

Imperial College London

Anterolateral Rotatory Instability of the Knee:
Anatomy, Biomechanics, and Related Reconstructions

by

Christoph Kittl

A thesis submitted
for the degree of MD(res)

Department of Mechanical Engineering

Imperial College London

2019

Originality Declaration

I declare that all work hereby contained in this thesis has been produced by the author, and all else has been appropriately referenced.

Copyright Declaration

The copyright of this thesis rests with the author and is made available under a Creative Commons Attribution Non-Commercial No Derivatives licence. Researchers are free to copy, distribute or transmit the thesis on the condition that they attribute it, that they do not use it for commercial purposes and that they do not alter, transform or build upon it. For any reuse or redistribution, researchers must make clear to others the licence terms of this work.

Abstract

There are several different factors, why an anterior cruciate ligament (ACL) graft may fail. One reason is missed peripheral injuries, especially on the anterolateral side of the knee, which may be responsible for different grades of instability after ACL rupture. Thus, the aim of this thesis was to investigate the role of the anterolateral structures in restraining knee instability and provide a surgical rationale for extra-articular lateral reconstruction.

A cutting study was performed using a six degree of freedom robotic setup. The anterolateral structures were subsequently transected in ACL-intact and ACL deficient knees and the drop in force was analysed. The iliotibial tract was the primary restraint to internal tibial rotation in 30°, 60°, and 90° knee flexion. The ACL presented the main contribution in full extension.

In high-grade anterolateral rotatory instability (ALRI), an ACL reconstruction and an additional extra-articular lateral reconstruction may control this instability better than an isolated ACL reconstruction. Furthermore, it will share the load with the intra-articular graft and therefore prevent re-rupture. Cadaveric knees were tested in a muscle loading rig and the length changes of the native anterolateral structures and several extra-articular reconstructions were measured using a suture and a linear variable displacement transducer (LVDT). The Lemaire and the MacIntosh reconstruction, which were guided deep to the lateral collateral ligament (LCL) had preferable length change pattern, being tight in extension and slacken in flexion.

The iliotibial tract was the primary restraint to internal tibial rotation and an injury should be expected in high-grade ALRI. Regarding length change pattern of lateral extra-articular reconstructions a Lemaire or MacIntosh reconstruction, guided deep to the LCL should be used.

Acknowledgements

I would like to express my very great appreciations to Prof. Andrew Amis, who believed in me when coming with new ideas and always had an open door for my countless questions. The work in this thesis would not have been possible without his valuable guidance and his unlimited support.

I am particularly thankful to Mr Andy Williams and Dr. Chinmay Gupte for their surgical advice and their expert guidance. I look back with pleasure at our anterolateral dissection and reconstruction session at the ISAKOS congress in 2015 in Lyon.

A huge thanks to my “robot” colleagues Dr Hadi El Daou and Dr. Kiron Athwal, who endured me during several night sessions, testing with cadaveric knee specimen. Thanks also to Dr. Camilla Halewood and Dr. Joanna Stephen for their valuable help in the lab and for answering my questions regarding statistics. Thank you to Dr. Breck Lord and Dr. Thomas Correa and the whole biomechanical group for their discussions and friendship, which made the time in London to such a special experience.

Last but certainly not least, a special thanks to my mother, father and my brother Michael, who always supported me in every situation. Without your help and your loyalty, this would not have been possible. Thank you also to my girlfriend Maria, who endured me during the whole process of writing and submitting this thesis.

Publications from this Thesis

The role of the anterolateral structures and the ACL in controlling laxity of the intact and ACL-deficient knee; The American Journal of Sports Medicine, Volume 44, Number 2, pages: 345-354
C Kittl, H El-Daou, KK Athwal, CM Gupte, A Weiler, A Williams, AA Amis

Length change patterns in the lateral extra-articular structures of the knee and related reconstructions; The American Journal of Sports Medicine, Volume 43, Number 2, pages: 354-362
C Kittl, C Halewood, JM Stephen, CM Gupte, A Weiler, A Williams, AA Amis

The role of the anterolateral structures and the ACL in controlling laxity of the intact and ACL-deficient knee: response; The American Journal of Sports Medicine, Volume 44, Number 4, pages: NP15-NP18
C Kittl, H El-Daou, KK Athwal, CM Gupte, A Weiler, A Williams, AA Amis

Anterolaterale Rotationsinstabilität; Arthroskopie, Volume 27, Number 3, pages: 170-176
C Kittl, A Weiler, AA Amis

Biomechanics of the anterolateral structures of the knee; Clinics in Sports Medicine, Volume 37, Number 1, pages: 21-31
C Kittl, E Inderhaug, A Williams, AA Amis

Biomechanical Role of Lateral Structures in Controlling Anterolateral Rotatory Laxity: The Iliotibial Tract; Operative Techniques in Orthopaedics, Volume 27, Number 2, pages: 96-101
C Kittl, A Williams, AA Amis

Scientific Basis and Surgical Technique for Iliotibial Band Tenodesis Combined with ACL
Reconstruction; Controversies in the Technical Aspects of ACL Reconstruction, pages: 393-404
C Kittl, E Inderhaug, J Stephen, H El-Daou, A Williams, AA Amis

Presentations from this Thesis

- **C Kittl**, H El Daou, KK Athwal, CM Gupte, A Weiler, A Williams, AA Amis; The role of the anterolateral structures in controlling rotational laxity in an ACL intact and deficient knee. ACL Study group Are (invited guest)
- **C Kittl**; Die Anatomie der anterolateralen Strukturen des Kniegelenks und deren Rekonstruktionen (Re-Live Dissektion); GOTS 2016 (invited Highlight speaker)
- **C Kittl**; Anatomie und Biomechanik der anterolateralen Strukturen; Master Class Symposium: Periphere-Instabilität (Berlin, 2015)
- **C Kittl**, H El Daou, KK Athwal, CM Gupte, A Weiler, A Williams, AA Amis; The role of the anterolateral structures in controlling rotational laxity in an ACL intact and deficient knee. AGA 2015 Dresden (2. AGA Best Research Paper Award 2015)
- **C Kittl**, H El Daou, KK Athwal, CM Gupte, A Weiler, A Williams, AA Amis; The Role of the Anterolateral Structures and the ACL in Controlling Internal Rotational Knee Laxity (ISAKOS 2015 (Winner of the ISAKOS Young investigator award)
- **C Kittl**, H El Daou, KK Athwal, CM Gupte, A Weiler, A Williams, AA Amis; The role of the anterolateral structures in controlling internal rotational knee laxity. BASK 2015 Annual Spring Meeting

- **C Kittl**, JM Stephen, C Halewood, CM Gupte, A Weiler, A Williams, AA Amis;
Anterolateral rotatory instability of the knee: responsible structures and reconstruction isometry. BASK 2014 Annual Spring Meeting - 8th & 9th April

- **C Kittl**, A Weiler, C Gupte, A Williams, AA. Amis; Anterolateral rotatory instability of the knee: Contributing structures and reconstruction isometry; AGA meeting 2014 Innsbruck

Table of Contents

1. Introduction	26
1.1 Background.....	28
1.2 Aims and Objectives.....	30
2 Anatomy of the Anterolateral structures	31
2.1 Background.....	33
2.2 Iliotibial Tract.....	33
2.2.1 Superficial Layer of the ITT:.....	34
2.2.2 Deep Layer of the ITT:	34
2.2.3 Capsulo-osseous layer of the ITT	36
2.3 Capsule, Mid-third capsular ligament.....	37
2.4 Anterolateral ligament:	38
2.5 Biceps femoris muscle complex	39
2.6 Lateral meniscus:	40
2.7 Segond Fracture	41
2.8 Confusion around the anterolateral structure nomenclature	42
2.9 Dissection Method	46
2.10 Reconciling the terminology of the anterolateral structures	48
2.11 Conclusion	49
3 Biomechanics of the Anterolateral structures	50
3.1 Background:.....	52
3.2 Internal tibial rotation:.....	53
3.3 Anterolateral rotatory instability	54
3.4 Pivot shift phenomenon:	56
3.5 Structural properties of the anterolateral structures	58

3.6	Length change pattern of the anterolateral structures.....	59
3.7	Conclusion	61
4	The role of the anterolateral structures in the ACL-intact and deficient knee.	63
4.1	Background.....	65
4.2	Aims and Hypothesis	65
4.3	Methods:	66
4.3.1	Specimen preparation:.....	66
4.3.2	Tissue resection and cutting order:	68
4.3.3	Testing protocol:	74
4.3.4	Robotic biomechanical testing system:	75
4.3.5	Data Analysis:.....	77
4.4	Results:.....	79
4.4.1	Anterior and posterior tibial translation:.....	79
4.4.2	Internal and external tibial rotation:	81
4.4.3	Simulated pivot-shift test:.....	84
4.5	Discussion:.....	87
4.6	Limitations:.....	91
4.7	Conclusion:	91
5	Surgical procedures of the anterolateral structures.....	93
5.1	Background:.....	95
5.2	Aims:	95
5.3	Biomechanics of the lateral extra-articular reconstruction.....	96
5.4	Lateral extra-articular procedures.....	99
5.4.1	MacIntosh tenodesis.....	99
5.4.2	Lemaire tenodesis.....	100
5.4.3	The Losee sling and reef operation.....	104

5.4.4	Ellison procedure	106
5.4.5	The Rowe-Zarins technique	107
5.4.6	Anterolateral ligament reconstruction	108
5.5	Limitations of extra-articular reconstructions.....	109
5.6	Conclusion	110
6	Length change pattern of the anterolateral structures and related reconstructions	111
6.1	Background.....	113
6.2	Aims	114
6.3	Materials and Methods	115
6.3.1	Specimen preparation.....	115
6.3.2	Data analysis	121
6.3.3	Statistical Analysis:.....	121
6.4	Results.....	123
6.4.1	Attachment sites	123
6.4.2	Graft course:	124
6.5	Length change pattern and total strain range.....	125
6.5.1	Native tissue structures of the anterolateral side of the knee	125
6.5.2	Lateral Extra-articular soft-tissue reconstructions	127
6.5.3	Femoral isometric points	129
6.6	Discussion.....	130
6.7	Limitations.....	133
6.8	Conclusion	134
7	General discussion and future work.....	135
7.1	Research findings	137
7.1.1	Anatomy of the anterolateral complex (Chapter 2)	137
7.1.2	Biomechanics of the anterolateral structures (Chapter 3)	138

7.1.3	The role of the anterolateral structures in restraining knee laxity (Chapter 4).....	138
7.1.4	Extra-articular lateral reconstructions (Chapter 5).....	139
7.1.5	Length change pattern of the anterolateral structures and related reconstructions (Chapter 6)	139
7.2	Limitations.....	141
7.2.1	Knee specimens	141
7.2.2	Specimen dissection method and biomechanical testing.....	141
7.2.3	Testing setup:.....	142
7.2.4	Measurement methods	143
7.3	Future work	145
7.3.1	Robotic testing:.....	145
7.3.2	Clinical trials	146
7.4	Recommendations to surgeons.....	147
8	References.....	148
9	Appendix	166

List of Figures

Figure 2.1 Right knee, lateral side: 1 Patella; 2 Iliopatellar Band; 3 superficial iliotibial tract inserting mainly inserting at Gerdy's tubercle (4); 5 Area of the Segond avulsion, halfway between Gerdy's tubercle (4) and fibular head (6), 7 Lateral collateral ligament shining through the superficial fibres of the iliotibial tract, 8 long head of the biceps femoris, 9 short head of the biceps femoris.....33

Figure 2.2 Right knee, lateral side, revealing the Kaplan fibre network after removal of the superficial iliotibial tract fibres (1) from anterior. 2 proximal insertion, 3 supracondylar insertion, 4 retrograde insertion, 5 lateral superior genicular artery, 6 lateral intermuscular septum, 7 vastus lateralis longus.35

Figure 2.3 Right knee, lateral side, Further removal of the superficial fibres of the iliotibial tract, revealing the retrograde fibre tract (1), forming a sling around the posterolateral femur and inserting posterior to Gerdy's tubercle (8), 2 lateral epicondyle, 3 supracondylar insertion, 4 retrograde insertion, 5 lateral superior genicular artery, 6 lateral intermuscular septum, 7 lateral collateral ligament.....36

Figure 2.4 Right knee, lateral aspect after removal of the superficial (see 1 in figure 2.2), deep (see 2 and 3 in figure 2.2), and capsule osseous layer (see 1 in figure 2.3), revealing the capsular structures. 1 vastus lateralis longus, 2 lateral epicondyle, 3 long head of the biceps femoris, 4 anterolateral ligament, 5 lateral meniscus, 6 attachment of the anterolateral ligament at the area of the Segond avulsion fracture, 7 lateral collateral ligament, 8 patella, 9 fibular head, 10 Gerdy's tubercle, 11 patellar tendon.38

Figure 2.5 Right knee, lateral side, after removal of the superficial iliotitbial tract (1). Femoral transection and lifting of the capsulo-osseous layer (3) showing the biceps-capsuloosseous iliotibial tract confluence (2). 4 short head of the biceps femoris, 5 tendon of the long head of the biceps femoris, 6 lateral intermuscular septum.....39

Figure 2.6 Right knee, lateral capsular structures removed and Patellar deflected. 1 c-shape of the lateral meniscus, 2 anterior root, 3 posterior root, 4 anterior cruciate ligament (tibial stump), 5 anterior meniscomfemoral ligament, 6 probe holding the posterior meniscomfemoral ligament, 7 bare area of the lateral meniscus (popliteus hiatus).41

Figure 2.7: Segond Avulsion shown on an anterior/posterior radiograph. This sign has been shown to be pathognomic for anterior cruciate ligament ruptures. Reproduced with permission from Kittl et al.⁹⁰ (2014)42

Figure 2.8 (a) 1: Patella, 2: Quadriceps tendon, 3:lateral femoral condyle, 4: anterior cruciate ligament (ACL), 5: lateral meniscus, 6: capsulo-osseous layer of the iliotibial tract (ITT), 7: tibial attachment of the capsulo-osseous layer 8: Gerdy’s tubercle. (b) The ACL and the capsulo-osseous layer of the ITB form a sling around the lateral femoral condyle. Reproduced with permission from Vieira et al. ¹⁶⁷ (2007)45

Figure 2.9 This is the lateral aspect of a left knee, distal to the left, proximal to the right. The anterolateral ligament complex (ALL) is grasped by the forceps close to the femoral attachment, which extends to the lateral intermuscular septum. Thus, describing a mixture of the deep iliotibial tract fibers and the ALL. It passes over the lateral (fibular) collateral ligament (LCL), and fans-out to wrap over the anterolateral rim of the tibial plateau. This exposure followed a longitudinal incision of the posterior edge of the iliotibial tract and anterior reflection of the resulting flap (in upper forceps), with sharp dissection posterior to Gerdy’s tubercle, exposing/clarifying the ALL and the LCL.....46

Figure 3.1: Anterior drawer in an ACL-deficient knee at 90° flexion. The y-axis shows the amount of displacement (mm). The x-axis shows the amount of tibial internal/external rotation (degree). The central point indicates the results with free tibial rotation. The left and right points are the results with fixed internal and external tibial rotation. Reproduced with permission from Amis and Scammell⁴ (1993)54

Figure 3.2 Axis of rotation of the tibial plateau. (a) Intact anterior cruciate ligament (ACL). The axis of rotation is central and therefore internal rotation causes the lateral tibial plateau to move anteriorly and the medial tibial plateau to move posteriorly by similar amounts. (b) Deficient ACL. The pathological axis of rotation is medial; therefore, tibial internal rotation causes a coupled anterior translation and magnifies the movement of the lateral compartment. Reproduced with permission from Amis et al.¹ (2005)55

Figure 3.3 At full extension the lateral tibial plateau can be subluxated, due to the loss of the ‘screw home mechanism’ in anterior cruciate ligament deficient knees. When the knee gets flexed the iliotibial increasingly pulls the lateral tibial plateau backwards until it gets reduced, which is felt by the examiner. Reproduced with permission from Lord and Amis¹⁰⁹ (2017)58

Figure 3.4 Separation distance (mm) between the tibial and femoral attachments of the anterolateral ligament of the knee in 0°, 30°, 60°, and 90° (circle graph), with 5Nm internal rotation (triangle) and external rotation (square). Reproduced with permission from Dodds et al.³³ (2014).....61

Figure 4.1 Alignment jig in order to position the centre of the tibial pot with the tibial axis of rotation. The tip of the needle was placed in the middle of the tibial eminence, when the pot was lean on the base of the jig, which was first introduced by Amis and Scammell⁴. Reproduced with permission from

Athwal KK¹⁰, Assessing the contributions of soft tissue to the stability of total knee replacements; a thesis for the degree of PhD and Diploma of Imperial College. (2016).....67

Figure 4.2 Intact-state of the knee mounted into the robot. The femur was attached to the base (right), whereas the tibia was attached to the moving arm of the robot (left)67

Figure 4.3 Lateral aspect of a left knee. (a) Superficial layer of the iliotibial tract (ITT) and biceps femoris muscle complex removed. Gerdy’s tubercle (1), capsulo-osseus layer of the ITT (2) inserting posterior to Gerdy’s tubercle, lateral collateral ligament (LCL) (3). (b) Attachment of the resected capsulo-osseus layer of the ITT (1), LCL (2).....69

Figure 4.4 Lateral aspect of a left knee: the femur extends proximally to the right, and the tibia extends distally toward the left with the patella at the top. Shown after removal of the deep and capsulo-osseous layer of the iliotibial tract, leaving the extracapsular anterolateral ligament exposed (arrows), passing over the proximal lateral collateral ligament. The femoral attachment is proximal and posterior to the epicondyle, and the tibial attachment is midway between the Gerdy tubercle and the head of the fibula.....70

Figure 4.5 lateral aspect of a left knee. A, All structures running superficial to the lateral collateral ligament (LCL) were removed. Gerdy’s tubercle (1), anterolateral capsule (2), LCL (3), femoral insertion of the lateral head of the gastrocnemius muscle (4). B, After removal of the anterolateral capsule, Gerdy’s tubercle (1), lateral meniscus (2), popliteus tendon (3), LCL (4), femoral attachment of the lateral head of the gastrocnemius muscle (5).....71

Figure 4.6 Left knee, lateral side after removal of the complete anterolateral structures and midsubstance cut of the anterior cruciate ligament (ACL) showing the tibial stump of the ACL (1), the lateral femoral condyle (2), the lateral meniscus (3), the anterolateral tibial rim (4), and the intact lateral collateral ligament (5).72

Figure 4.7 a) Example hysteresis graph of a force-controlled setup of the robot. After cutting two structures (light and dark green) in an intact knee (blue) the displacement increased with the same force applied. b) Example hysteresis graph of a displacement-controlled setup. The robot replays the path of motion from the intact state (blue) of the knee after cutting the structures (green). The decrease in force representing the contribution of the transected structure. Reproduced with permission from Athwal KK¹⁰, Assessing the contributions of soft tissue to the stability of total knee replacements; a thesis for the degree of PhD and Diploma of Imperial College, (2016)75

Figure 4.8 Setup of the six degrees-of-freedom robotic system (1-6). 7 universal force/moment sensor, 8 tibial fixture, 9 femoral base unit.....76

Figure 4.9 Sample hysteresis graph of internal [+] /external [-] rotation at 90° flexion of knee 6 (anterior cruciate ligament intact). Y-axis represents the torque [Nm], whereas the X-axis represents the tibial rotation [degree]. Each motion was replayed three times by the robot (same colour). For example the drop in torque (black arrow) between the blue curve (intact state of the knee) and the red curve (superficial iliotibial tract cut) presented the contribution of the superficial iliotibial tract. sITT = superficial iliotibial tract; dclTT = deep and capsule-osseus layer of the iliotibial tract; ALL = anterolateral ligament; ACL = anterior cruciate ligament.78

Figure 4.11 Contribution [%] of tested structures in restraining a 90N anterior tibial translation at 0°, 30°, 60°, and 90°. Cross-hatched areas indicate results from the anterior cruciate ligament deficient group. sITT=superficial layer of the iliotibial tract; dclTT= deep and capsulo-osseus layer of the iliotibial tract; ALL= anterolateral ligament; Cap= anterolateral capsule; ACL= anterior cruciate ligament. Asterisks note significant differences to the previous cut, whereas asterisks with brackets note significant differences to the ACL deficient state of the knee. Statistical significance: *p<.05; **p<.01; *** p<.001. (Shown as mean + SD, n=8)79

Figure 4.12 Contribution [%] of tested structures in restraining a 90N posterior tibial translation at 0°, 30°, 60°, and 90°. The anterolateral structures had no significant contribution to posterior tibial translation. Cross-hatched areas indicate results from the anterior cruciate ligament deficient group. sITT=superficial layer of the iliotibial tract; dclTT= deep and capsulo-osseus layer of the iliotibial tract; ALL= anterolateral ligament; Cap= anterolateral capsule; ACL= anterior cruciate ligament.80

Figure 4.13 Contribution [%] of tested structures in restraining a 5Nm internal rotation torque at 0°, 30°, 60°, and 90°. The medial collateral ligament (MCL) and the posterior medial corner (PMC) were only tested on four knees and at 30° knee flexion. Cross-hatched areas indicate results from the anterior cruciate ligament deficient group. sITT=superficial layer of the iliotibial tract; dclTT= deep and capsulo-osseus layer of the iliotibial tract; ALL= anterolateral ligament; Cap= anterolateral capsule; ACL= anterior cruciate ligament. Asterisks note significant differences to the previous cut, whereas asterisks with brackets note significant differences to the ACL deficient state of the knee. Statistical significance: *p<.05; **p<.01; *** p<.001. (Shown as mean + SD, n=8, apart from MCL and PMC when n=4).....82

Figure 4.14 Contribution [%] of tested structures in restraining a 5Nm external rotation torque at 0°, 30°, 60°, and 90°. Cross-hatched areas indicate results from the anterior cruciate ligament deficient group. sITT = superficial layer of the iliotibial tract; dclTT= deep and capsulo-osseus layer of the iliotibial tract; ALL= anterolateral ligament; Cap= anterolateral capsule; ACL= anterior cruciate ligament. The ACL and the anterolateral structures had no contribution in restraining external

rotation, except the sITT at 30° and 60° compared to the previous cut (asterisks). Statistical significance: *p<.05.....83

Figure 4.15 Contribution [%] of tested structures in restraining a 4Nm internal rotation torque in response to a simulated pivot shift test (4Nm internal rotation and 8Nm valgus rotation) at 15°, 30°, and 45°. Cross-hatched areas indicate results from anterior cruciate ligament deficient group. sITT=superficial layer of the iliotibial tract; dclITT= deep and capsulo-osseus layer of the iliotibial tract; ALL= anterolateral ligament; Cap= anterolateral capsule; ACL= anterior cruciate ligament. Asterisks note significant differences to the previous cut, whereas asterisks with brackets note significant differences to the ACL deficient state of the knee. Statistical significance: *p<.05; **p<.01; *** p<.001. (Shown as mean + SD, n=8)86

Figure 5.1 Left knee lateral side (A): When a K-wire (2) was inserted anterior to the Kaplan fibres, the iliotibial tract (ITT; 1) reduced the lateral tibia condyle (3), as it provided a posterior pull throughout the range of motion. (B): When inserting a K-wire posterior to the Kaplan fibres the posterior pull was decreased and therefore the ITT (1) could not reduce the subluxation of the lateral tibial condyle (3), even at 90° flexion. Reproduced with permission and adapted from Hassler and Jakob⁶⁴ (1981)96

Figure 5.2 An additional extra-articular reconstruction did not add any stability compared to an isolated intra-articular reconstruction in case of an isolated anterior cruciate ligament rupture. An isolated extra-articular reconstruction improved stability compared to the ruptured state, but did not restore it to normal. Reproduced with permission from Amis and Scammell⁴ (1993).....97

Figure 5.3 An additional Lemaire or MacIntosh reconstruction, which was passed deep to the lateral collateral ligament, restored internal rotation laxity to normal. The anterolateral ligament (ALL Recon) reconstruction presented persistent internal rotation instability at certain flexion angles, whereas the superficial Lemaire (Lemaire Sup) over-constrained this. Statistical significance is indicated by circles. Reproduced with permission from Inderhaug et al.⁷⁵ (2017) 98

Figure 5.4 A strip of the iliotibial tract, left attached at Gerdy's tubercle (a) is shuttled deep to the lateral collateral ligament (b) and rerouted on itself after perforating the lateral intermuscular septum through a periosteal tunnel. Reproduced with permission from Ireland and Trickey⁷⁶ (1980)..... 100

Figure 5.5 Similarly to the MacIntosh tenodesis the iliotibial tract graft is routed deep to the lateral collateral ligament. It is then passed (a) through a semi-circular tunnel, which enters the lateral femoral condyle between the lateral epicondyle and the gastrocnemius tubercle (posterior and proximal to the lateral femoral epicondyle) and exits anteriorly. The graft is then again shuttled deep to the LCL and sutured onto itself (b). Reproduced with permission from Fritschy and Freuler⁴⁹ 101

Figure 5.6 The skin incision starts 10 mm proximal to the lateral epicondyle and is expanded towards Gerdy's tubercle (a). The iliotibial tract is then prepared and the lateral epicondyle can be palpated (forceps; b). Reproduced with permission from Wagner et al.¹⁷⁰ (2014)..... 102

Figure 5.7 The iliotibial tract is incised on the anterior border of Gerdy's tubercle using a scalpel (a). The incision is further expanded approximately 30 mm proximally to the lateral epicondyle using scissors in order to not damage the lateral collateral ligament. Reproduced with permission from Wagner et al.¹⁷⁰ (2014)..... 102

Figure 5.8 The lateral collateral ligament is then dissected and an Overholt-forceps (a) is passed deep to the lateral collateral ligament (LCL). A shuttle suture is passed deep to the LCL to later shuttle the graft proximally deep to the LCL. A 10 mm wide strip of the iliotibial tract, which is still attached to Gerdy's tubercle is then dissected proximally. (b). Reproduced with permission from Wagner et al.¹⁷⁰ (2014) 103

Figure 5.9 The strip of the iliotibial tract is then cut proximally, approximately 30 mm proximal to the lateral epicondyle. (a) It is then whipstitched and shuttled deep to the lateral collateral ligament using the shuttle suture (b). Reproduced with permission from Wagner et al.¹⁷⁰ (2014) 103

Figure 5.10 A K-wire is then drilled approximately 2 mm proximal and posterior to the tip of the lateral epicondyle (a). This is then overdrilled using a 6 or 7 mm thick drill, depending on the graft size (b). Reproduced with permission from Wagner et al.¹⁷⁰ (2014)..... 104

Figure 5.11 The graft is then shuttled into the tunnel using a shuttle suture (a). An interference screw according to the size of the graft is used to fix it into the tunnel (b). Reproduced with permission from Wagner et al.¹⁷⁰ (2014)..... 104

Figure 5.12 The strip of the iliotibial tract is passed through a tunnel from anterior/distal to proximal/posterior on the lateral femoral condyle. Reproduced with permission from Losee et al.¹¹⁰ (1978) 105

Figure 5.13 The iliotibial strip is then passed deep to the gastrocnemius tendon and deep to the posterolateral structures for the second reefing. Reproduced with permission from Losee et al.¹¹⁰ (1978) 106

Figure 5.14 A strip of the iliotibial tract with a distal bone plug is rerouted deep to the lateral collateral ligament and then fixed to the bone trough at Gerdy's tubercle using a staple. Reproduced with permission from Ellison³⁹ 1979)..... 106

Figure 5.15 The semitendinosus tendon and a strip of the iliotibial tract are rerouted through a tunnel on the anteromedial tibia via the over-the-top position of the lateral femoral condyle, and deep to the lateral collateral ligament and vice versa. Reproduced with permission from Zarins and Rowe¹⁸⁰ (1986) 107

Figure 5.16 A 3fold semitendinosus tendon with a single strand gracilis tendon is taken as the intra-articular anterior cruciate ligament graft. The remaining gracilis tendon graft is used as a tri-angular lateral extra-articular reconstruction. Reproduced with permission from Sonnery-Cottet et al.¹⁵² (2015) 109

Figure 6.2 Medial aspect of a left knee mounted into the knee extension rig. The muscles were loaded using hanging weights and a pulley system. 1 Patella; 2 Femur; 3 Vastus medialis obliquus; 4 Vastus medialis longus; 5 Rectus femoris and Vastus intermedius; 6 Vastus lateralis longus..... 116

Figure 6.3 Lateral aspect of a left knee mounted into the knee extension rig. The muscles were loaded using hanging weights and a pulley system. 1 Patella; 2 Iliotibial tract left attached at Gerdy’s tubercle; 3 Vastus lateralis obliquus; 4 Vastus lateralis longus; 5 Rectus femoris and Vastus intermedius..... 116

Figure 6.4 Knee extension rig. The muscles were loaded according their fibre direction and cross section area using hanging weights and a pulley system. The horizontal restraining bar limited the knee extension to any flexion angle. Reproduced with permission from Stephen et al.¹⁵⁶ (2012)..... 117

Figure 6.5 Femoral eyelet positioning (white). Tibio-femoral point combinations account for structures on the lateral side, extra-articular soft-tissue reconstructions and femoral isometric points. a: pinG (black): Gerdy’s tubercle; pinA (blue): Area of the Segond avulsion; Dashed line: lateral collateral ligament; green pin: lateral epicondyle. b: black pin: Gerdy’s tubercle; blue pin: Area of the Segond avulsion; red pin: fibular head; green pin: lateral epicondyle..... 119

Figure 6.6 Linear variable displacement transducer setup. Depending on the location of the sliding core the ferromagnetic chamber produces a voltage change, which is transmitted to the Solartron base unit. This voltage change can be converted to millimetre length change and stored to an Excel sheet on the local computer. Reproduced with permission from Ghosh KM⁵⁵, The Effects of Total Knee Replacement on the Extensor Retinaculum of the Knee; a thesis for the degree of MD(Res) and Diploma of Imperial College. (2009)..... 120

Figure 6.7 A monofilament suture connected the tibia with the femur using a pin and an eyelet. When the ligament tightened the stroke arm of the linear variable displacement transducer (LVDT) lengthened, whereas when the ligament relaxed the stroke arm of the LVDT shortened. Reproduced with permission and adapted from Ghosh et KM⁵⁵ (2009), and Stephen et al.¹⁵⁵ (2014) 120

Figure 6.8 Length change pattern of all tested native tissue structures with pooled 95% confidence interval. In relation to tibial pin A, a change from femoral eyelet E1 to E3 changed the length change from a mean 19mm elongation to 8mm shortening. Moving from G to A on the tibia had a smaller effect, in relation to femoral eyelet E6. 123

Figure 6.9 Differences between tibio-femoral point combinations superficial and deep (*) to the lateral collateral ligament (LCL). The combinations guided deep to the LCL displayed less variability in length change patterns. 124

Figure 6.10 Extra-articular isometry map for various tibio-femoral point combinations. Total strain range values (TSR) were plotted onto the femur. Low values indicate near isometry and high values non-isometry. Green pin: lateral femoral epicondyle; red pin: fibula head; black pin Gerdy`s tubercle; blue pin: Area of the Segond avulsion. (a) TSR values in combination with pinG, the suture was guided superficial to the lateral collateral ligament (LCL). (b): TSR values in combination with pinA, the suture was guided superficial to the LCL. (c): TSR values in combination with pinG, the suture was guided deep to the LCL..... 125

Figure 6.11 Length change pattern of all tested reconstructions with pooled 95% confidence interval. Femoral insertion points proximal to the lateral epicondyle display similar length change pattern. *: graft passed deep to the lateral collateral ligament..... 128

List of Tables

Table 2.1 Pictures of the corresponding studies were analysed and assigned to anatomical regions..	44
Table 4.1. Sequential cuts and corresponding anatomical structures	73
Table 4.2 Contribution [%] of each structure restraining a 90N anterior translation force (for abbreviations see Table 4.1).....	80
Table 4.3. Contribution [%] of each structure restraining a 5Nm internal rotation torque (for abbreviations see Table 4.1).....	83
Table 4.4. Contribution [%] of each structure restraining a 5Nm external rotation torque (for abbreviations see Table 4.1).....	84
Table 4.5. Contribution [%] of each structure restraining a 4Nm internal rotation torque in response to a simulated pivot shift test (8Nm valgus torque) (for abbreviations see Table 4.1)	86
Table 6.1. Femoral eyelet positioning and corresponding tibio-femoral point combinations (four native tissue structures, four reconstructions and three femoral isometric points). ALL = anterolateral ligament; ITT = iliotibial tract; LCL = lateral collateral ligament.....	118
Table 6.2: Length change (%) and significant differences at each flexion angle for ligament tibio-femoral point combinations.....	126
Table 6.3 Total strain range values of each tested tibio-femoral point combination. LCL = lateral collateral ligament,.....	127
Table 6.4 Length change (%) and significant differences at each flexion angle for reconstruction tibio-femoral point combinations. The course of the suture was deep to the lateral collateral ligament.	128

Table 6.5 Length change (%) and significances at each flexion angle for tested femoral isometric points.
..... 130

List of Abbreviations

ACL	Anterior cruciate ligament
ALL	Anterolateral ligament
ALRI	Anterolateral rotatory instability
ANOVA	Analysis of variances
AP	Anterior-posterior
ATT	Anterior tibial translation
Cap	Anterolateral capsule
dcITT	deep and capsule osseous layer of the iliotibial tract
IE	Internal-external
IKDC	International Knee Documentation Committee
ITB	Iliotibial Band
ITT	Iliotibial tract
LCL	Lateral collateral ligament
LVDT	Linear variable displacement transducer
MCL	Medial collateral ligament
N	Newton
Nm	Newton meter
PCL	Posterior cruciate ligament
PMC	Posteromedial corner
PMMA	Polymethylmethacrylate
SD	Standard deviation
SM	Semimembranosus tendon
SPSS	Statistical package for social science
sITT	Superficial iliotibial tract

TSR

Total strain range

UFS

Universal force-moment sensor

I. Introduction

1.1 Background

Anterior cruciate ligament (ACL) reconstruction generally has good to excellent results. However, graft ruptures occur in approximately 4-17%^{54,82,151,174}, with higher risk in the younger population (12-25%)^{17,133,148,172} and patients returning to strenuous sports (up to 29%)¹⁷² suffering a graft rupture or contralateral ACL injury. Additionally, a substantial number of patients (5-25%) have disappointing IKDC and return to sports scores.^{9,48,62} Reasons for graft rupture, contralateral ACL injury and poor results may include surgical error, concomitant peripheral injuries, failure of graft incorporation, and trauma.^{62,78} Unrecognized injuries to the peripheral ligamentous structures may lead to persistent rotatory instabilities^{1,138}, higher ACL graft forces⁹⁷, and may shift the contact areas posteriorly on the tibial plateau^{8,72}. These factors may not only lead to the failure of an isolated ACL graft, but also to early onset osteoarthritis¹⁶⁰ despite ACL reconstruction.

Anterolateral rotatory instability (ALRI) is one these complex rotatory instabilities associated with ACL rupture. It may occur as a result of concomitant damage to the anterolateral structures at the time of ACL injury^{71,110,119,164,175}. However, in the chronic setting, the anterior tibial translational and internal rotational laxity associated with ACL-deficiency may cause the anterolateral structures to be repeatedly stressed resulting in progressive elongation ('stretching out')⁴⁰.

Although cohort studies of revision ACL reconstruction have shown that technical error at primary surgery was the commonest cause of graft failure and that missed peripheral ligament injuries account for only 3% of revisions,^{60,105} the addition of a lateral extra-articular procedure to primary ACL reconstruction appears to lower graft rupture rates.¹⁵²

Lateral extra-articular reconstructions were first developed in the 1970s and 1980s.^{7,39,101,110,112,180} Unfortunately, when performed in isolation, they did not yield satisfactory results in the treatment of ACL deficiency³⁴ and were abandoned after a consensus conference in 1989 organized by the American Orthopaedic Society for Sports Medicine (AOSSM). They concluded that extra-articular

reconstructions would eventually increase the risk of osteoarthritis by over-constraining the lateral compartment and did not add any additional stability to an intra-articular ACL reconstruction.

It was Paul Segond in 1879¹⁴⁶, who first described an avulsion fracture of the lateral tibial rim between Gerdy's tubercle and the fibular head, when applying excessive internal rotation on cadaveric knee specimen. This avulsion, which was later called the "Segond fracture" was attached to a pearly fibrous ligament. Yet, more recently, focus on the antero-lateral ligament (ALL) of the knee has lead to a re-kindling of interest in the anatomy, biomechanics and possible reconstructions on the lateral side of the knee to augment ACL reconstruction.²²

Thus, this thesis aims to improve the understanding of the anatomy, biomechanics, and related reconstructions of the anterolateral structures of the knee.

I.2 Aims and Objectives

1. To develop a dissection method in order to describe the anatomy of the anterolateral structures of the knee and compare this to the existing literature.
2. To determine the function of the ACL and the anterolateral structures in controlling knee stability.
3. To obtain data on the function of the anterolateral structures in controlling knee stability in an ACL-deficient knee.
4. To study the length change pattern of the native anterolateral structures
5. To investigate the insertion point isometry of lateral extra-articular reconstructions.

2 Anatomy of the Anterolateral structures

The majority of this chapter has been published in german in Arthroscopie
Anterolaterale Rotationsinstabilität; Arthroscopie, Volume 27, Number 3, pages: 170-176
C Kittl, A Weiler, AA Amis

Some parts of this chapter have been published in the American Journal of Sports Medicine
The role of the anterolateral structures and the ACL in controlling laxity of the intact and ACL-
deficient knee: response; The American Journal of Sports Medicine, Volume 44, Number 4, pages:
NP15-NP18

C Kittl, H El-Daou, KK Athwal, CM Gupte, A Weiler, A Williams, AA Amis

For permission see Chapter 9 (Appendix)

2.1 Background

The anatomy of the anterolateral side of the knee is complex and anatomical descriptions are confusing. The purpose of this chapter was a literature review aiming to reconcile differing depictions of the anatomy and provide consistency to descriptions of key functional structures.

2.2 Iliotibial Tract

The iliotibial tract (ITT) is a strong band of the fascia latae over the lateral surface of the thigh, which is proximally invested by the gluteus maximus muscle, the tensor fascia latae and the fascia of the gluteus medius¹⁷¹. On the femur the ITT attaches on the linea aspera through the lateral intermuscular septum and the so called 'Kaplan fibres' further distal.¹⁰⁸ On the tibia it inserts on Gerdy's tubercle and slightly posterior on the lateral rim of the tibia. It also has an attachment on the patella (iliopatellar band), which merges with the lateral retinaculum.

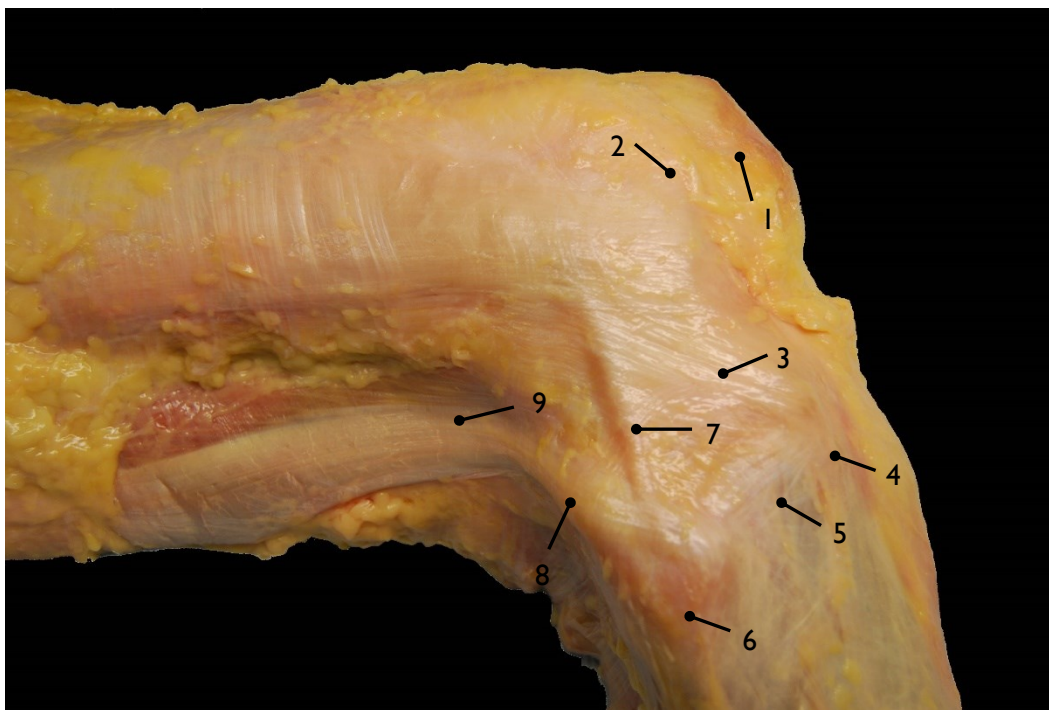


Figure 2.1 Right knee, lateral side: 1 Patella; 2 Iliopatellar Band; 3 superficial iliotibial tract inserting mainly inserting at Gerdy's tubercle (4); 5 Area of the Segond avulsion, halfway between Gerdy's tubercle (4) and fibular head (6), 7 Lateral collateral ligament shining through the superficial fibres of the iliotibial tract, 8 long head of the biceps femoris, 9 short head of the biceps femoris

The ITT can be divided into two functional components (ITT and iliopatellar band) and five layers (aponeurotic, superficial, middle, deep and capsulo-osseous).¹⁶¹ However, recent literature has only mentioned the superficial, deep and capsulo-osseous layer.¹⁶⁷ It has been shown in electrical stimulation studies, that the proximal muscles attached to the ITT do not transmit forces to the knee joint.⁸⁴ Thus, the ITT has only a static, ligament like function across the tibiofemoral joint⁶⁴ and it has been suggested that it provides anterolateral stability to the tibia.⁴³

2.2.1 Superficial Layer of the ITT:

The superficial layer of the ITT is a fibre confluence of the fascia latae, the vastus lateralis muscle aponeurosis, biceps femoris muscle aponeurosis¹⁶⁷ and the iliopatellar band.¹⁶¹ (figure 2.1) The patella and the patellar tendon form the anterior border of the superficial layer. The posterior border is formed by the biceps femoris muscle. The majority of the superficial fibres insert on Gerdy's tubercle at the tibia. However Terry et al.¹⁶³ found that the posterior fibre region of the superficial layer merges with the capsulo-osseous layer and inserts slightly posterior. The oblique fibre direction of the ITT may suggest a strong contribution to limit tibial internal rotation, particularly in high knee flexion angles.

2.2.2 Deep Layer of the ITT:

The deep layer of the ITT becomes visible approximately 6cm proximal to the lateral femoral epicondyle.¹⁶¹ (figure 2.2) This triangular area at the distal termination of the intermuscular septum is formed by strong fibres connecting the superficial ITT layer to the femur. The lateral superior genicular artery passes between these femoral attachments suggesting a strong and static area. Werner Mueller noted haemorrhage in this area in acute ACL ruptures and found increased internal rotatory instability following section of this layer. Lobenhoffer et al.¹⁰⁸ further divided this layer into the proximal- and supracondylar tract insertion.

They found the supracondylar fibres of the deep ITT extended distally and attach at the posterolateral femoral metaphysis (see 3 in figure 2.2). These could be visualised in 93% of their 100

dissected knees¹⁰⁸. The distance from Gerdy's tubercle at 10° knee flexion was 66 ± 9 mm and its bony insertion had a length of 12 ± 6 mm.¹⁰⁸

The proximal Kaplan fibres, which attached directly distal to the distal termination of the lateral intermuscular septum, were found in 73% (see 2 in figure 2.2). The bony insertion had a length of 9 ± 4 and the distance from Gerdy's tubercle at 10° knee flexion was 74 ± 11 mm. Conversely, Godin et al.⁵⁷ reported the distance between Gerdy's tubercle and the attachment site of the supracondylar fibres of the ITT to be 93.8 mm. The distance between Gerdy's tubercle and the attachment of the proximal Kaplan fibres was 72.2 mm. Their measurements were taken at 50 degrees as opposed to 10 degrees flexion. Furthermore, the attachment site was also found larger compared to Lobenhoffer et al., which may have resulted from different dissection methods and number of knees used in these studies (8^{57} vs 100^{108}).

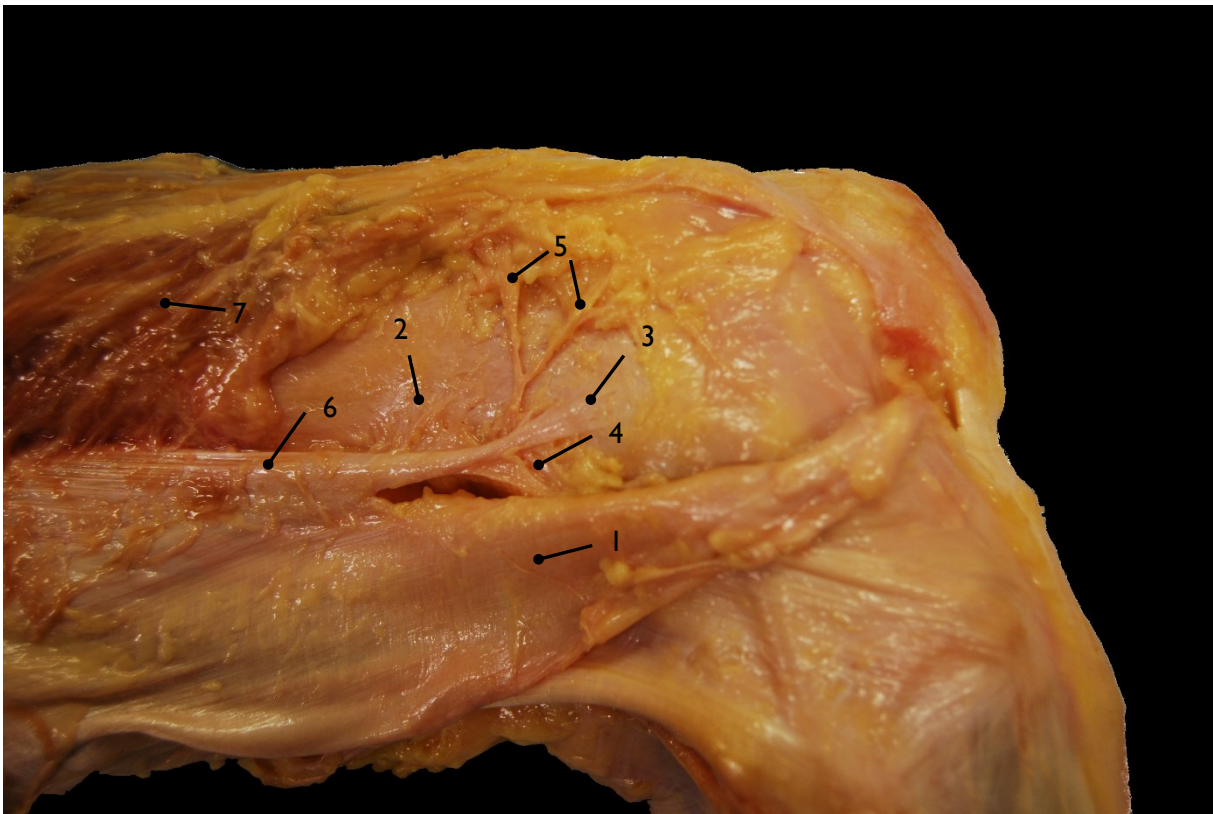


Figure 2.2 Right knee, lateral side, revealing the Kaplan fibre network after removal of the superficial iliotibial tract fibres (1) from anterior. 2 proximal insertion, 3 supracondylar insertion, 4 retrograde insertion, 5 lateral superior genicular artery, 6 lateral intermuscular septum, 7 vastus lateralis longus.

2.2.3 Capsulo-osseous layer of the ITT

The capsulo-osseous layer was described as the deepest layer of the ITT and provides a lateral capsular strengthening.¹⁶⁷ (figure 2.3) This layer is also known as the retrograde tract insertion¹⁰⁸ and attaches at the lateral femoral supracondylar region and passes distal, where it inserts slightly posterior to Gerdy's tubercle. This region halfway between the fibular head and Gerdy's tubercle is known to be the area of the Segond avulsion fracture. The capsulo-osseous layer forms a sling around the lateral femoral condyle and prevents the lateral tibial plateau from subluxating anteriorly. Thus, this structure restrains the pivot-shift manoeuvre by keeping the superficial layer posterior to the transverse axis of rotation.¹⁶¹ Authors considered this layer of the ITT acting as an 'anterolateral ligament'.¹⁶⁷ Furthermore Terry et al.¹⁶⁴ found injuries of the capsulo-osseous layer in 71% of their ACL tear cases.

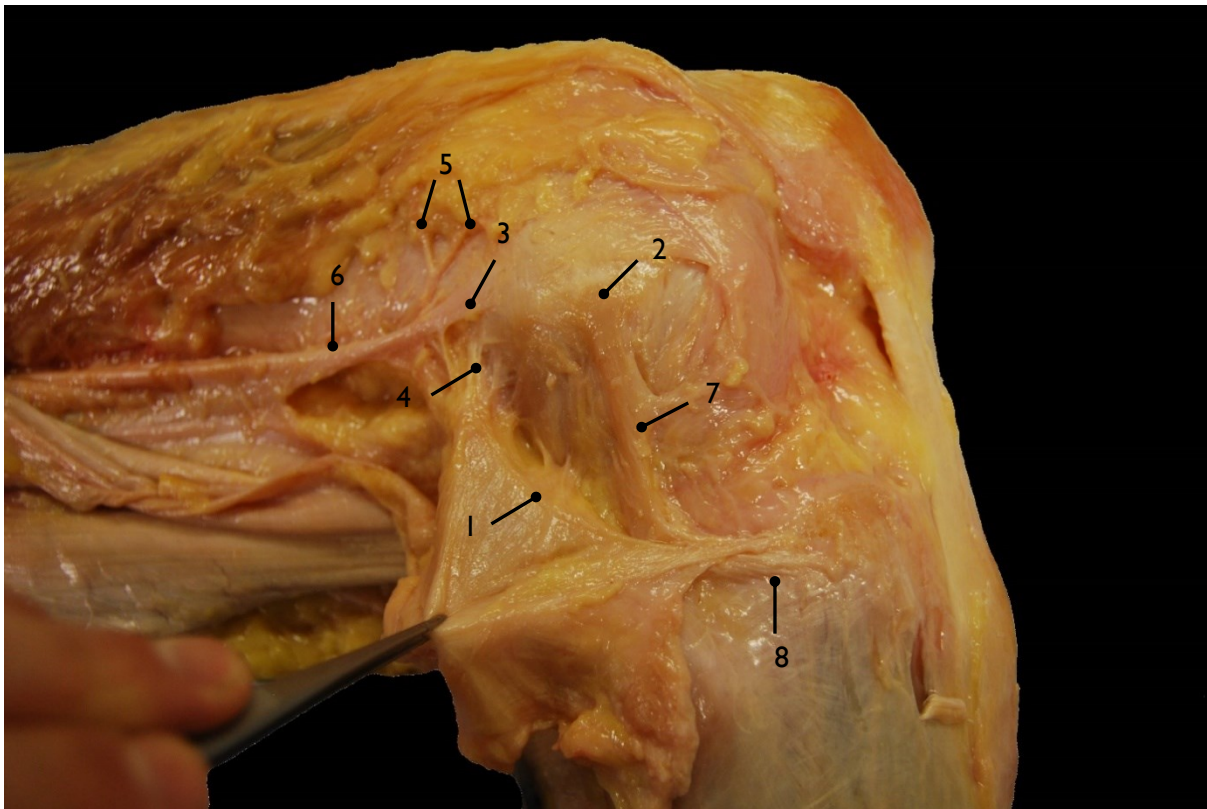


Figure 2.3 Right knee, lateral side, Further removal of the superficial fibres of the iliotibial tract, revealing the retrograde fibre tract (1), forming a sling around the posterolateral femur and inserting posterior to Gerdy's tubercle (8), 2 lateral epicondyle, 3 supracondylar insertion, 4 retrograde insertion, 5 lateral superior genicular artery, 6 lateral intermuscular septum, 7 lateral collateral ligament.

The deep and the capsule-osseous layers of the ITT are commonly known as the Kaplan fibres.¹⁴³ Lobenhoffer et. al. called these fibres, which had a reversed course compared to the other Kaplan bundles, the `retrograde fibre tract`. These fibres had the same attachment area as the proximal Kaplan fibres and were found in all the knees where the proximal fibres were present (73%).

2.3 Capsule, Mid-third capsular ligament

The midthird lateral capsular ligament has been described as having a meniscotibial portion and a meniscomfemoral portion. On the tibia it attaches between the anteroinferior popliteomeniscal fascicle (popliteus hiatus) and the posterior border of Gerdy's tubercle approximately 6-9mm distal from the subchondral bone.^{16,71,96,137,143,145} The femoral attachment site was defined in the region of the lateral femoral epicondyle^{71,96} with several other attachments on the posterior aspect of the popliteus insertion and at the lateral gastrocnemius tendon insertion.⁹⁵ Seebacher et al. emphasised a bilaminar structure of the lateral capsule. The superficial capsular lamina (original capsule embryologically) surrounds the LCL, the deep lamina passes medial to the LCL and inserts on the outer edge of the lateral meniscus. The midthird lateral capsular ligament was found at the confluence of these two layers at the posterior border of the ITT. Johnson et al. described a lateral capsular ligament complex, which had vertical and horizontal components and attachments on the lateral tibia, lateral meniscus, fibula, biceps femoris, lateral head of the gastrocnemius and the popliteus sheath.⁸¹ They also noted interdigitating fibres attaching at the superficial layer of the ITT. However none of these authors have mentioned the deep and capsulo-osseous layer of the ITT, which may be part of their descriptions.¹⁶¹ Recently Catherine et al. concluded in their study that the lateral capsular ligament is a thickening of the lateral capsule and can be seen as an independent structure, synonymous to the ALL.²¹

2.4 Anterolateral ligament:

Recently several different research groups identified a distinct ligament on the anterolateral side of the knee.^{21,22,28,33,67,142,157,168} Claes et al. were the first to describe this distinct ligament. They found the femoral attachment on the tip of the lateral femoral epicondyle, which was present in 97% of their dissected knees. Also, an intimate connection to the lateral meniscus was observed. Their description is similar to the midthird lateral capsular ligament described by Hughston et al.⁷¹. Vincent et al.¹⁶⁸ also found a capsular structure similar to those structures described by Claes et al.²² and Helito et al.⁶⁷ However its femoral attachment was located on the popliteus tendon or anterior to the popliteus tendon. Dodds et al.³³ found the attachment proximal and slightly posterior to the lateral femoral epicondyle. It was also described as an extra-capsular structure. (figure 2.4) Similarly, Kennedy et al.⁸⁶ showed its femoral attachment was located 4.7 mm posterior and proximal to the LCL attachment.

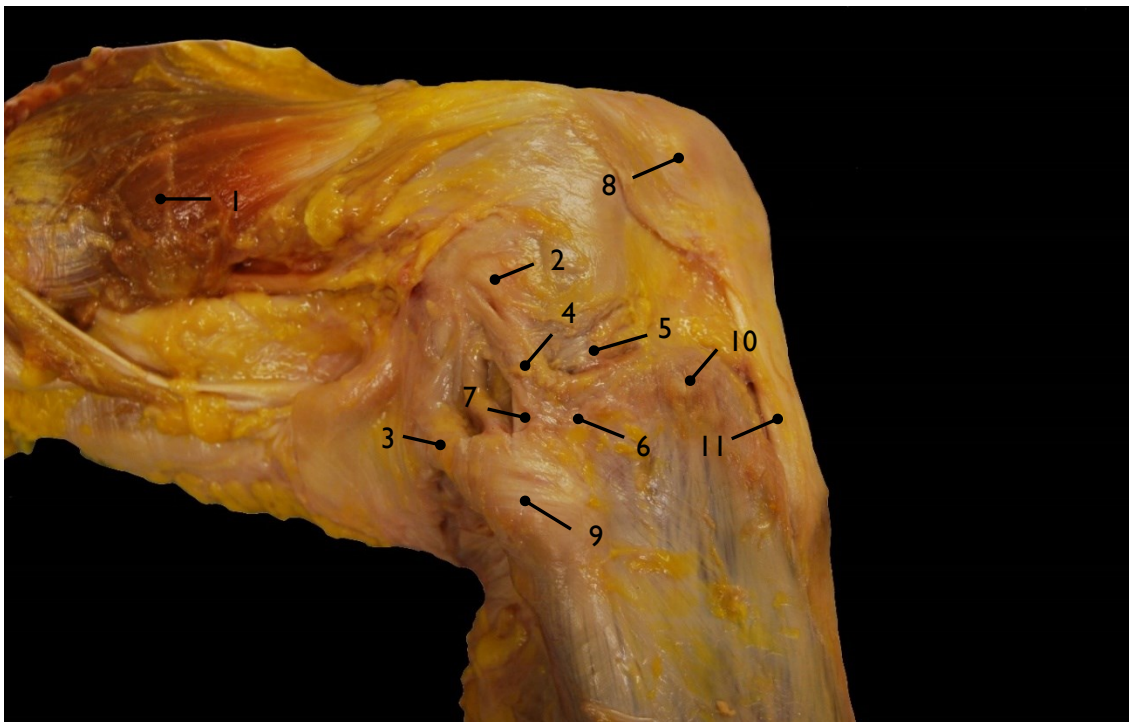


Figure 2.4 Right knee, lateral aspect after removal of the superficial (see 1 in figure 2.2), deep (see 2 and 3 in figure 2.2), and capsule osseous layer (see 1 in figure 2.3), revealing the capsular structures. 1 vastus lateralis longus, 2 lateral epicondyle, 3 long head of the biceps femoris, 4 anterolateral ligament, 5 lateral meniscus, 6 attachment of the anterolateral ligament at the area of the Second avulsion fracture, 7 lateral collateral ligament, 8 patella, 9 fibular head, 10 Gerdy's tubercle, 11 patellar tendon.

2.5 Biceps femoris muscle complex

The biceps femoris muscle complex contains two heads, long and short. The long head of the biceps femoris originates at the ischial tuberosity and has five major insertion on the knee.¹⁶² Two of them are tendinous insertions and attach at the fibular styloid (direct arm) and on the lateral edge of the fibular head (anterior arm). The anterior arm then continuous as the anterior aponeurosis into the fascia cruris. The two fascial components insert at the posterior border of the ITT (reflected arm), and the posterior part of the lateral collateral ligament (LCL; lateral aponeurosis).

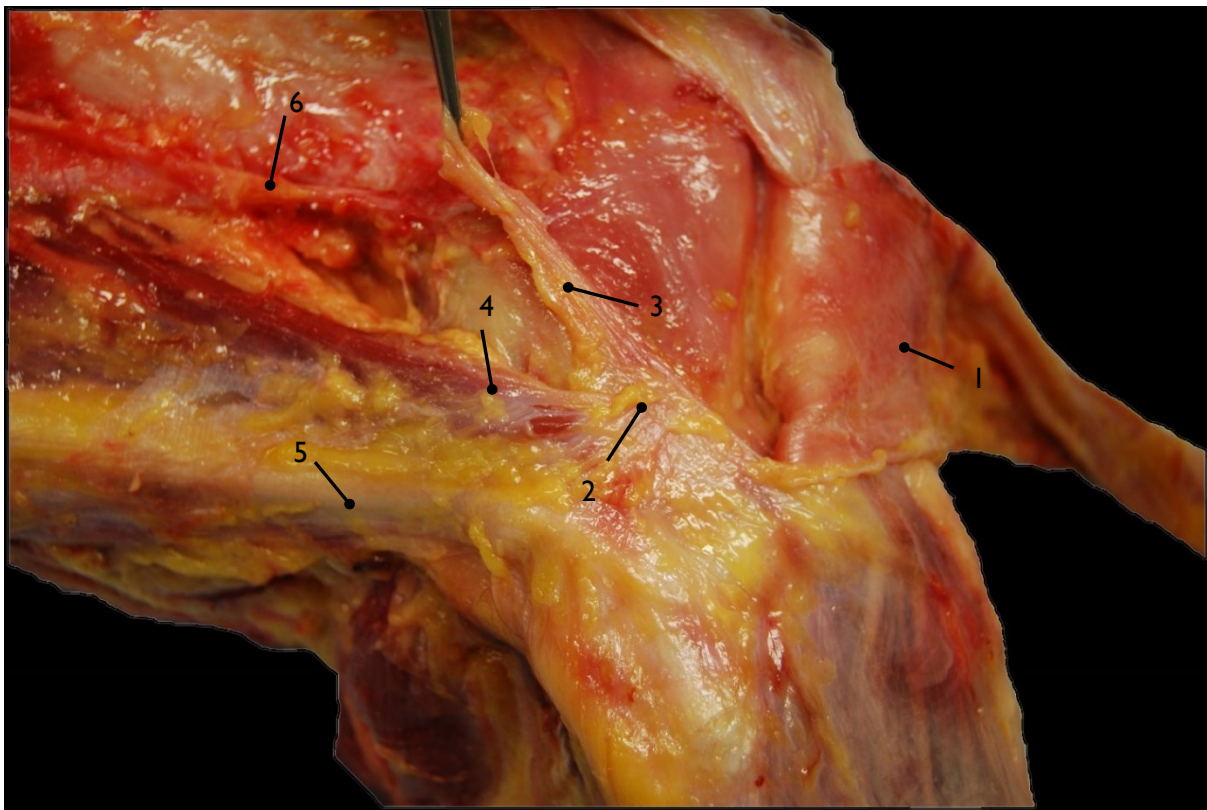


Figure 2.5 Right knee, lateral side, after removal of the superficial iliotibial tract (1). Femoral transection and lifting of the capsulo-osseous layer (3) showing the biceps-capsuloosseous iliotibial tract confluence (2). 4 short head of the biceps femoris, 5 tendon of the long head of the biceps femoris, 6 lateral intermuscular septum.

The short head of the biceps femoris originates at the lateral intramuscular septum and the lateral aspect of the linea aspera. After removal of the long head of the biceps, the parts of the short head are revealed. The direct arm inserts on the tip of the fibular styloid and its anterior arm passes deep to the LCL and inserts with the meniscotibial portion of the midthird lateral capsular ligament on the

rim of the lateral tibial plateau. Similar to the long head the lateral aponeurotic arm inserts at the posteromedial border of the LCL. Furthermore, the short head of the biceps also has three muscular insertions to the tendon of the long head, to the posterolateral aspect of the capsule, and to the capsulo-osseous layer of the ITT. The last insertion is the biceps-capsuloosseous iliotibial tract confluence. (figure 2.5)^{162,163}

2.6 Lateral meniscus:

The lateral meniscus is a curved and wedge shaped fibrocartilage structure in the lateral knee compartment.⁹⁹ (figure 2.6) It is firmly attached to the tibia by its two roots. Its anterior root blends with the tibial attachment and is C-shaped (laterally open) surrounded by the tibial attachment of the ACL.¹⁸² The posterior root attachment was found to be directly posterior to the lateral tibial spine. Johnson et al. found that the anterior and posterior root attachments of the lateral menisci were directly connected to the tibial ACL stump. The posterior fibres of the anterior horn blended with the anterior ACL fibres, while the anterior fibres of the posterior horn blended with the posterior fibres of the ACL.⁸⁰ Johannsen described the relationship to the tibial posterior cruciate ligament attachment, which was located 12.7 mm posterior to the centre of the root attachment.⁷⁹ Further tibial attachments of the lateral meniscus are the lateral capsular ligament (anterolateral) and the coronary ligament (posterolateral).¹⁴³ Between these capsular attachments the popliteus tendon enters the knee joint through the popliteus hiatus, which was described as the bare area of the meniscus.²⁴ However, this area contains a complex fibre network, called the popliteomeniscal fascicles. Stäubli et al.¹⁵⁴ described three different fascicle. 1. the superior popliteomeniscal fascicle, which inserted into the posterior horn of the lateral meniscus. 2. the inferior popliteomeniscal fascicle, which creates the floor of the popliteal hiatus. And, finally, the popliteofibular fascicle, which connects the popliteal hiatus to the fibula.

Femoral attachments of the lateral meniscus include the meniscomfemoral capsule and two distinct ligaments, which connect the posterior horn of the lateral meniscus to the femur. The anterior

menisofemoral ligament (aMFL; ligament of Humphrey) was present in 74% of knees.⁶¹ Its femoral attachment was located on the medial side of the intercondylar notch, adjacent to the medial border of the posterior cruciate ligament (PCL) attachment, adjacent to the articular cartilage margin. The posterior menisofemoral ligament (pMFL; ligament of Wrisberg) was present in 69% of the knees and its femoral attachment was more posterior than the attachment of the aMFL on the proximal border of the femoral PCL attachment.

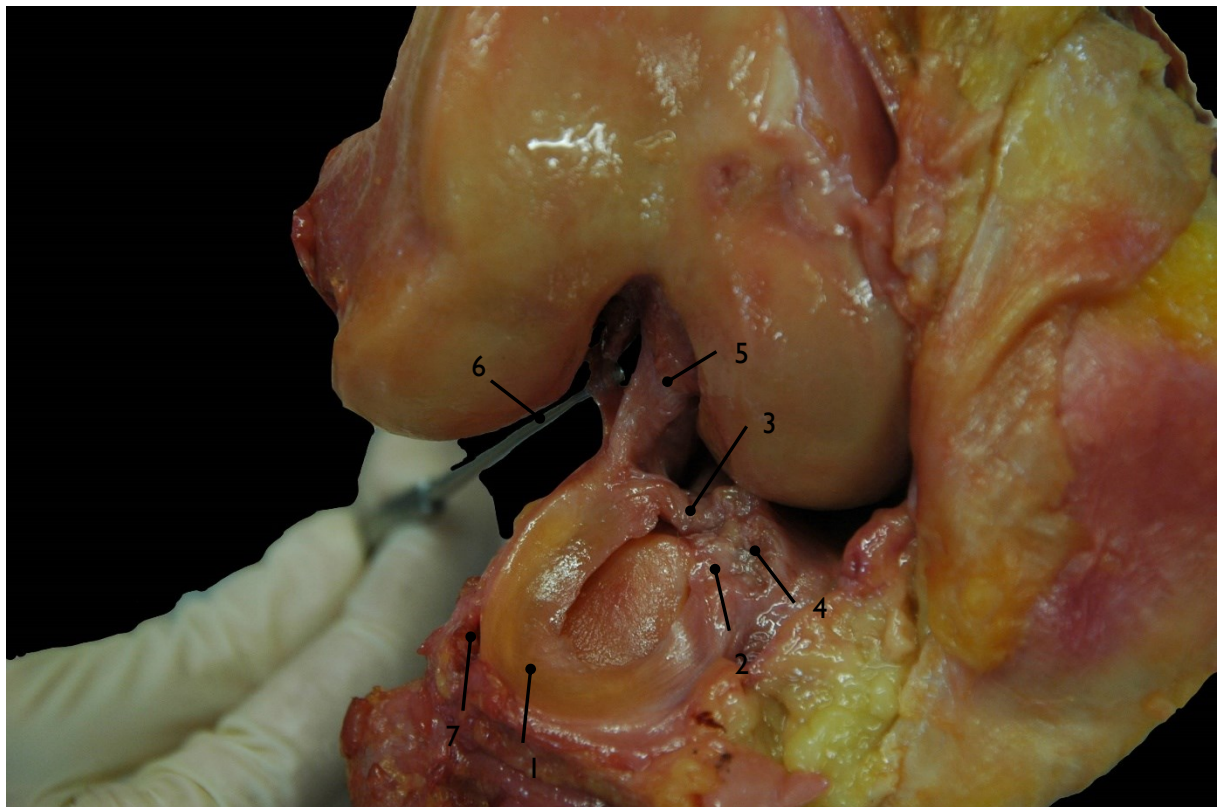


Figure 2.6 Right knee, lateral capsular structures removed and Patellar deflected. 1 c-shape of the lateral meniscus, 2 anterior root, 3 posterior root, 4 anterior cruciate ligament (tibial stump), 5 anterior menisofemoral ligament, 6 probe holding the posterior menisofemoral ligament, 7 bare area of the lateral meniscus (popliteus hiatus).

2.7 Segond Fracture

The Segond fracture was first described by Paul Segond in 1879.¹⁴⁶ This cortical avulsion, best seen on an anterior-posterior X-ray, occurs halfway between the fibular head and the tip of Gerdy's tubercle. (figure 2.7) It was described as being the result of an excessive internal rotation and varus

rotation moment, and a strong link to ACL rupture was emphasized.⁵⁸ However, no consensus exists regarding the attaching soft tissue structures. Terry and LaPrade found in their surgical observations that the mid-third lateral capsular ligament, the capsulo-osseous layer of the ITT and the anterior arm of the biceps femoris muscle were attached to the fracture fragment.¹⁶² Similarly, Shaikh et al. found the capsulo-osseous layer of the ITT and the anterolateral capsule attached at this fragment in 36 MRIs, but did not look at the biceps¹⁴⁷. ALRI should be suspected in patients presenting with this injury, until proven otherwise.³¹

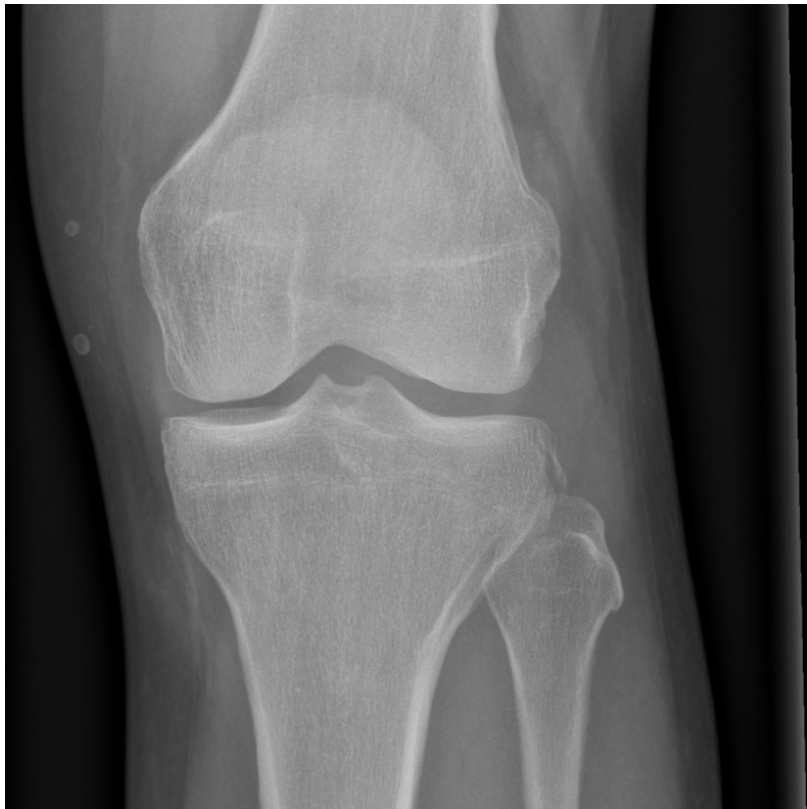

Figure 2.7: Segond Avulsion shown on an anterior/posterior radiograph. This sign has been shown to be pathognomonic for anterior cruciate ligament ruptures. Reproduced with permission from Kittl et al.⁹⁰ (2014)

2.8 Confusion around the anterolateral structure nomenclature

Hughston et al.⁷¹ were the first to popularize the term ‘anterolateral rotatory instability’ and associated it with a rupture of the midthird lateral capsular ligament and the ACL. However, they did

not mention the capsulo-osseous layer of the ITT, which runs directly above the anterolateral knee capsule. Kaplan⁸⁴ and later Terry et al.¹⁶⁴, and Viera et al.¹⁶⁷ described the capsulo osseous layer of the ITT as forming a sling around the posterolateral femur and called it an ‘anterolateral ligament’. (figure 2.8) Confusion may have arisen from the use of different names in the literature: Müller: Ligamentum femorotibiale anterius¹²²; Lobenhoffer: retrograde fibre bundle¹⁰⁸, and Hassler and Jakob: Ligamentum tractotibiale⁶⁴. These terms have all been applied to what may be described as the femoral attachment of fibrous structures which are effectively a distal prolongation of the lateral intermuscular septum, and which includes what are often known as the Kaplan’s fibres. All of the cited studies found a femoral attachment at the linea aspera around the distal termination of the intermuscular septum, and a tibial attachment either posterior to Gerdy’s tubercle or directly at Gerdy’s tubercle.

Conversely, the description of the femoral attachment of the ALL varies broadly among authors. Originally it was reported to be anterior and distal to the lateral femoral epicondyle and a conjunction to the lateral meniscus was described. These characteristics certainly do not match the descriptions of the capsulo-osseous layer of the ITT. Thus, in accordance with Claes et al.²² we believe that the ALL “... is clearly distinct from the ITB, and both its deep layer and its capsulo-osseous layer should not be confused with the ALL”. Some later descriptions of the ALL^{28,33,86}, however, describe different attachments around the lateral femoral epicondyle and it still remains unclear whether this “ligamentous” structure is a capsular thickening or an extra-capsular structure. When looking at the pictures of recent anatomical and biomechanical publications^{28,86,150} it may in fact be possible that a mixture of the anterolateral knee capsule (which has a connection to the lateral meniscus) and fibres of the capsulo-osseous ITT layer have been described as a “robust” ALL having a fan-like tibial attachment posterior to Gerdy’s tubercle (figure 2.9). However, this of course raises the important question why the original terms (capsulo-osseous layer; midthird capsular ligament) have neither been maintained nor adopted. There is lack of clarity in the terminology on the anterolateral side of the knee. The following table (2.1) will help to understand the names and structures. The pictures in the studies were analysed and assigned to anatomical regions.

Table 2.1 Pictures of the corresponding studies were analysed and assigned to anatomical regions.

Author	Structure	Name
Müller	Confluence of the superficial and deep iliotibial tract (ITT)	Ligamentum femorotibiale anterius
Terry	Deep ITT	Capsulo-losseous layer, acting as an anterolateral ligament
Viera	Deep ITT	Anterolateral ligament
Hassler	Confluence of the superficial and deep ITT	Ligamentum tractotibiale
Hughston	Thickening in the anterolateral capsule	mid-third capsular ligament
Vincent	Thickening in the anterolateral capsule	Anterolateral ligament
Claes	Thickening of the anterolateral capsule	Anterolateral ligament
Dodds	Parts of the deep ITT and a capsular thickening	Anterolateral ligament
Daggett	Parts of the deep ITT and a capsular thickening	Anterolateral ligament
LaPrade	Parts of the deep ITT and a capsular thickening	Anterolateral ligament

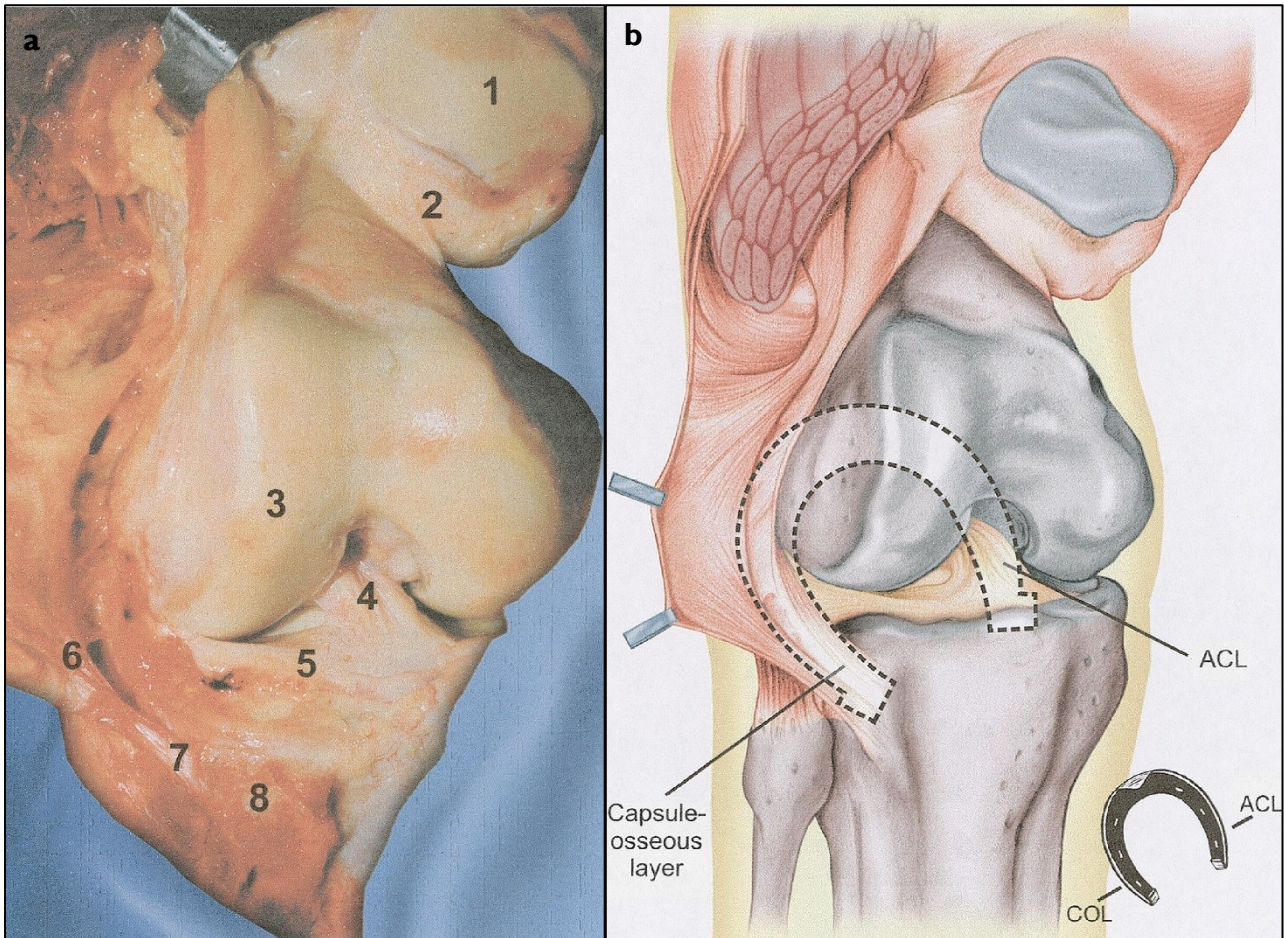


Figure 2.8 (a) 1: Patella, 2: Quadriceps tendon, 3:lateral femoral condyle, 4: anterior cruciate ligament (ACL), 5: lateral meniscus, 6: capsulo-osseous layer of the iliotibial tract (ITT), 7: tibial attachment of the capsulo-osseous layer 8: Gerdy's tubercle. (b) The ACL and the capsulo-osseous layer of the ITB form a sling around the lateral femoral condyle. Reproduced with permission from Vieira et al. ¹⁶⁷ (2007)

Daggett and Sonnery-Cottet¹¹¹ suggested that the capsular thickening and the deep fibres of the ITT are the same structure and should be called ALL. Although as a concept it does indeed not really matter, what the orthopaedic community term the anterolateral corner structures, it would seem confusing to describe two discreet anatomical structures in this way, and of course, incorrect!

In our own observations we found a clear layer-by-layer anatomy existing of the superficial ITT layer, the deep and capsulo-osseous layer of the ITT, and the anterolateral capsule. In fact, in some knees, some fibres separated superficially from the capsular layer, such that they passed superficial to the LCL, and were so pronounced that they formed a capsular thickening imitating a distinct ligament.

This observation is in line with several other studies, which did not find a distinct ligament on the anterolateral side in fresh frozen knees, formalin embedded knees⁴⁵, and foetal knees⁴⁶.

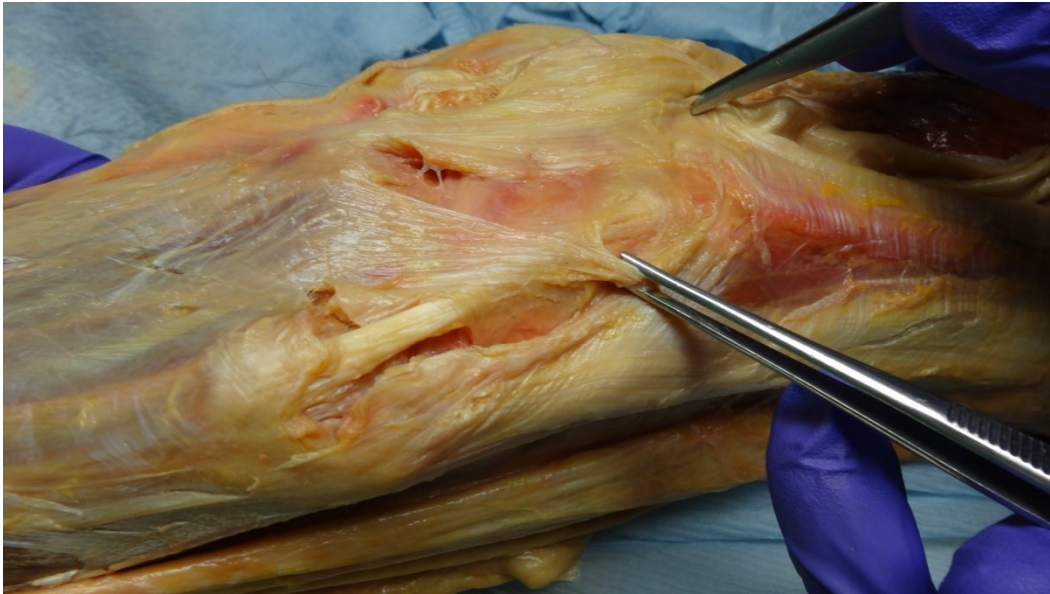


Figure 2.9 This is the lateral aspect of a left knee, distal to the left, proximal to the right. The anterolateral ligament complex (ALL) is grasped by the forceps close to the femoral attachment, which extends to the lateral intermuscular septum. Thus, describing a mixture of the deep iliotibial tract fibers and the ALL. It passes over the lateral (fibular) collateral ligament (LCL), and fans-out to wrap over the anterolateral rim of the tibial plateau. This exposure followed a longitudinal incision of the posterior edge of the iliotibial tract and anterior reflection of the resulting flap (in upper forceps), with sharp dissection posterior to Gerdy's tubercle, exposing/clarifying the ALL and the LCL.

2.9 Dissection Method

The dissection method used in this study addressed the layered anatomical structures using fresh-frozen cadaver specimens. At least 25 cadaveric knee specimens were dissected and the anatomical structures and their insertion sites were evaluated. The dissection was performed from anterior to posterior (according to Müller¹²¹) as opposed to Daggett et al.²⁶, who dissected from posterior to anterior.

After removal of the skin and the subcutaneous fat the fascia lata was incised longitudinally slightly lateral and proximal to the patella. The vastus lateralis muscle was then mobilised anteriorly until the lateral intermuscular septum could be identified. (see 6 in figure 2.2). The incision of the fascia lata

was then further expanded distally to the lateral portion of the tibial tuberosity. A longitudinal incision of the lateral retinaculum was then performed on the lateral edge of the patella and extended towards the medial portion of Gerdy's tubercle until the anterolateral capsule was visible and the superficial ITT could be reflected posteriorly (see figure 2.2). At the distal termination of the lateral intermuscular septum the lateral superior genicular artery could then be identified, which was frequently found surrounded by fatty tissue. This was then meticulously resected and the artery was followed posteriorly towards the Kaplan fibre network. As displayed in figure 2.2, three different fibre bundles, attaching at the area of the femoral metaphysis, could be identified (see chapter 2.2.2 and 2.2.3). Application of an internal tibial rotation torque, with the knee at 30 and 90 degrees flexion, caused obvious tightening of these fibres and the intermuscular septum.

The superficial layer of the ITT could then be differentiated from the capsulo-osseous layer due to its different tibial and femoral attachments. All fibres of the superficial layer of the ITT inserting at Gerdy's tubercle were resected. Tracing these fibres proximally there was no attachment at the metaphysis of the femur and they could then be completely removed. The superficial layer, covering the capsulo-osseous layer, was then peeled off, leaving the more-posterior fibres in place (see figure 2.3). At the posterior transition of the short head of the biceps femoris, the biceps-capsulo-osseous iliotibial tract confluence could then be identified, confirming the presence of the capsule-osseous layer without any superficial fibres left on it. Again, when applying internal rotation these posterior fibres could be tightened and were seen to provide restraint to the anterior subluxation of the lateral tibia.

The capsulo-osseous layer of the ITT was then resected, identifying the proximal attachments at the linea aspera and then followed distally. Once freed from its proximal attachment, this structure was not adherent to its underlying structures and could be easily followed to its distal attachment at the area posterior to Gerdy's tubercle. Thus, this structure formed a direct link from the linea aspera of the femur to the tibia, just posterior to Gerdy's tubercle. There was absolutely no doubt that the capsulo-osseous layer was completely separated from its underlying structures. Once these two

layers had been removed internal rotation laxity of the tibia was substantially increased, even in an ACL intact knee, implying a potent role of the ITT in controlling internal tibial rotation.

After resection of the ITT the anterolateral capsule was exposed. No distinct ligament could be found in all of the dissected knees. Only when an internal rotation force was applied to the tibia, it was possible to identify fibres running obliquely over the LCL corresponding to the ALL. These fibres were then removed. The remaining capsular structure, which also could be tensed by applying internal rotation was also resected⁷¹. This exposed the surface of the lateral femoral condyle, lateral meniscus and rim of the tibial plateau as far posteriorly as the LCL, so that no fibres, described in previous studies as being the ALL, remained intact.

By a fortunate coincidence, the senior signatory of the letter from Daggett et al.²⁷, Bertrand Sonnery-Cottet, had arranged to visit the laboratory of Imperial College London, and so we took the opportunity to dissect some knees together. Despite different dissection protocols, we were largely in agreement about the anatomy of the ALL: its course – passing over the LCL, its attachments – posterior/proximal to the lateral epicondyle, and mid-way between Gerdy's tubercle and the head of the fibula, and how it was tightened by tibial internal rotation, when the ITT was completely removed.

2.10 Reconciling the terminology of the anterolateral structures

The confusion surrounding the descriptions of the anatomy of the anterolateral side suggests a need for a consistent terminology for these structures reconciling older descriptions of the deep fibres of the ITT and the joint capsule. In particular, some interpretations of the ALL seem to describe a structure complex, that would consist of fibres from different anatomical structures.

Following some work in this thesis a consensus meeting in Watford, UK (2017) was held in order to establish an anatomical terminology for the anterolateral side of the knee.⁵³ After dissection of four

cadaveric knee specimens, each research group presented their results, which were discussed according to a modified Delphi consensus discussion. Similar to the layered anatomical observations of this thesis, the superficial ITT was described as the most superficial structure, followed by the deep ITT and the ALL and the anterolateral capsule.

Lobenhoffer et al.¹⁰⁸ were the first to further divide the Kaplan fibre network into the proximal (2 in figure 2.2), supracondylar (3 in figure 2.2) and retrograde fibres (4 in figure 2.2). Due to simplicity, these were classified as proximal (2 in figure 2.2), distal (3 in figure 2.2) supracondylar attachments and retrograde (condylar) attachment (4 in figure 2.2). The retrograde attachment continues into the capsulo-osseous layer (described by Terry et al.¹⁶¹, 1 in figure 2.3). The ALL was defined as a capsular structure lying in Seebacher layer three¹⁴⁵ of the anterolateral capsule, attaching posterior and proximal to the lateral femoral epicondyle on the femur and between Gerdy's tubercle and fibular head on the tibia.

2.11 Conclusion

The anatomy of the anterolateral structures of the knee is complex, lacks standard nomenclature and has been variably described. It seems, however, best to describe these in terms of tissue layers from superficial to deep. The first layer is presented by the superficial fibres of the ITT. The second layer is formed by the deep and capsulo-osseous fibres of the ITT, also called the Kaplan fibre network. The third layer represents the anterolateral knee capsule, which is divided into a superficial and deep lamina through the LCL.

The oblique course of these anterolateral structures imply a role in restraining the anterior subluxation of the lateral tibial plateau. However, biomechanical work evaluating the functions of the structures on the anterolateral side of the knee is lacking.

3 Biomechanics of the Anterolateral structures

Parts of this chapter have been published in Clinics in Sports Medicine, Operative Techniques in Orthopaedics, and Controversies in the Technical Aspects of ACL Reconstruction.

Biomechanics of the anterolateral structures of the knee; Clinics in Sports Medicine, Volume 37, Number 1, pages: 21-31

C Kittl, E Inderhaug, A Williams, AA Amis

Biomechanical Role of Lateral Structures in Controlling Anterolateral Rotatory Laxity: The Iliotibial Tract; Operative Techniques in Orthopaedics, Volume 27, Number 2, pages: 96-101

C Kittl, A Williams, AA Amis

Scientific Basis and Surgical Technique for Iliotibial Band Tenodesis Combined with ACL Reconstruction; Controversies in the Technical Aspects of ACL Reconstruction, pages: 393-404

C Kittl, E Inderhaug, J Stephen, H El-Daou, A Williams, AA Amis

For permission see Chapter 9 (Appendix)

3.1 Background:

Previously, the term ALRI was synonymous for the instability caused by an isolated ACL injury. However, Hughston et al.⁷¹, were the first to popularise ALRI as being due to combined ACL and anterolateral capsule injury, resulting in excessive anterior subluxation of the lateral tibial plateau. The introduction of intraarticular ACL reconstruction led to a loss of focus on associated peripheral injuries with ACL rupture. This was compounded with the transition from open to arthroscopic ACL surgery. Although intra-articular reconstruction of the ACL restored knee kinematics in the anterior/posterior direction, it failed to completely abolish the pivot-shift phenomenon in some knees.¹⁰⁴ This led to a more anatomical approach of intra-articular ACL reconstruction reproducing its oblique course to the posterior aspect of the femur using the medial portal technique.⁶³ However, despite efforts to improve reconstruction tunnel positions, graft tension, and postoperative rehabilitation, the issue of persistent rotational instability, following ACL reconstruction, remains.³

This residual rotational instability after ACL reconstruction may come from additional injury of the peripheral structures, which gained broad interest after anatomical description of the ALL in 2013.²² Since then, many studies regarding anatomy, biomechanics and possible reconstructions have been conducted.^{21,28,33,67,168} However, there is still a lack of evidence on how to diagnose these injuries and more importantly which patients will benefit from an additional lateral extra-articular procedure.

Although previous work has suggested promising biomechanical and clinical results, there is a lack of level one evidence. Similar to the medial side, anterolateral capsular structures may have a high healing potential, when the primary restraint to anterior tibial translation is reconstructed, but routine combined ACL reconstruction and reconstruction of the anterolateral structures may lead to increased morbidity. Conversely, undiagnosed anterolateral structure injuries may 'stretch-out' over time in chronic cases and impose abnormal loads on the ACL graft, preventing it from healing in the bone tunnel.²⁰ The purpose of this chapter is to evaluate the existing literature on the biomechanics of the anterolateral side of the knee.

3.2 Internal tibial rotation:

The principle of primary and secondary restraints was first introduced by Butler et al.¹⁹ by displacing the tibia anteriorly a predefined distance and then calculating the contribution of the different structures after cutting them. In this experiment the ACL provided an 85% resistance to a 250-550N anterior tibial translation (ATT) at 90° flexion, whereas the peripheral structures showed only a minor (< 3% each) contribution and were classified as a secondary restraint to ATT. This has also been shown in 20° knee flexion, where the ACL provided 78% of a lower anterior force (150N),² implying that the ACL is the primary restraint to ATT at all flexion angles.

However, in the ACL deficient knee the contribution of the secondary restraints in controlling laxity is increased, providing a backup and may "stretch out" over time when the primary restraint is absent.

As the tibia translates anteriorly there is a coupled internal rotation of the tibia of 3-10°.⁴ This increased motion in the lateral compartment is related to the convex shape of the lateral tibial plateau, the loose menisco-capsular attachments and the more mobile lateral meniscus. With the tibia free to rotate, ATT is 30% greater than when the tibia is fixed in internal or external rotation.¹ (figure 3.1). Controversy exists regarding the primary and secondary restraints to tibial internal rotation. Some authors found that an isolated ACL injury led to significant rotatory instability.^{4,6,106} However, other authors reported no increased tibial internal rotation.^{94,119} Wroble et al.¹⁷⁵ found a statistically significant but clinically unimportant increase in internal rotation when the ACL was sectioned. A large increase in internal rotation was only observed after additional cutting of the anterolateral structures. However, no specific structure acting as the primary restraint to internal tibial rotation has yet been identified. It would seem logical that the ACL may be only a secondary restraint to tibial internal rotation as, situated in the centre of the knee, it has a relatively small lever arm¹⁷⁵. By contrast the lateral peripheral structures, such as the ITT, the midthird lateral capsular ligament (ALL), or the collateral ligaments have a much larger lever arm.

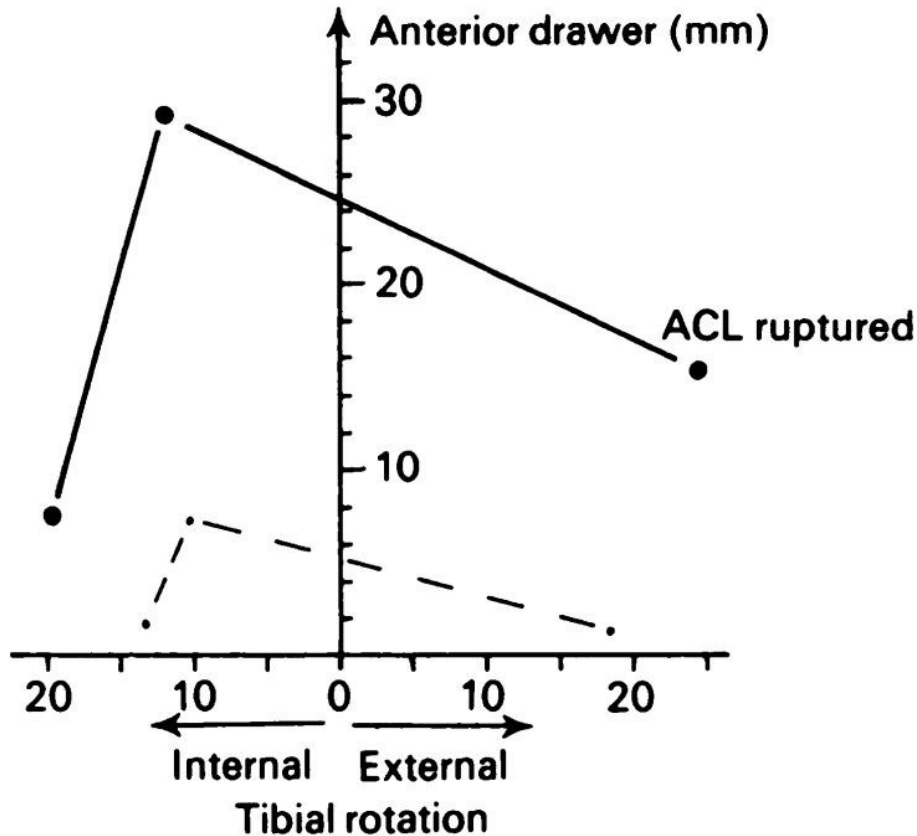


Figure 3.1: Anterior drawer in an ACL-deficient knee at 90° flexion. The y-axis shows the amount of displacement (mm). The x-axis shows the amount of tibial internal/external rotation (degree). The central point indicates the results with free tibial rotation. The left and right points are the results with fixed internal and external tibial rotation. Reproduced with permission from Amis and Scammell⁴ (1993)

3.3 Anterolateral rotatory instability

ALRI is a combined internal rotational and anterior translational movement of the tibial plateau. The biomechanical principle behind this is based on the rotational axis of the tibia shifting medially following ACL rupture.^{106,113,117} (figure 3.2) The lateral tibial plateau is susceptible to anterior subluxation due to the increased mobility in the lateral compartment (compared to medial) and may be accentuated by concomitant injuries to the anterolateral structures.^{71,110,120,164,175}

Video analysis studies¹³¹ have shown that non-contact ACL injury involves tibial internal rotation. Typically, the commonly seen bone-bruise pattern following ACL rupture affects the posterolateral tibial condyle and the femoral condyle in the region of the sulcus terminalis. This indicates

anterolateral subluxation of the lateral tibial plateau.⁶⁹ In the acute injury situation, the abduction moment of the knee forces the lateral femoral condyle to slide posterior on the convex lateral tibial slope. This anterior subluxation of the lateral tibial plateau or the posterior subluxation of the femur, has been shown to put the ACL under excessive load, which may eventually result in ACL failure.⁸³

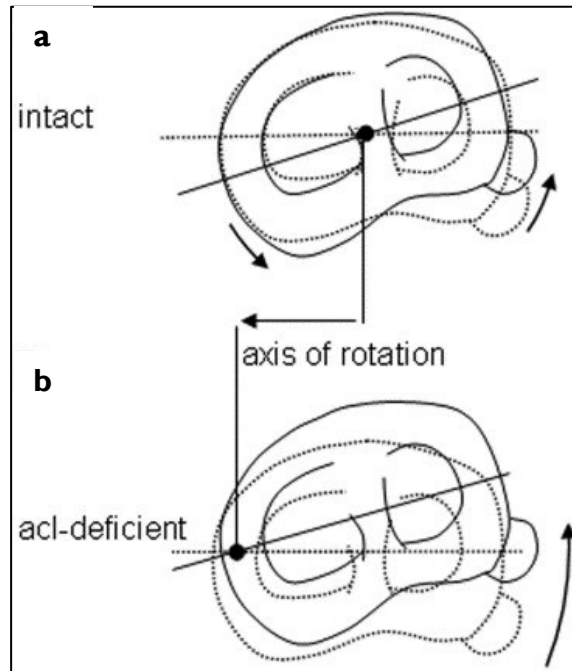


Figure 3.2 Axis of rotation of the tibial plateau. (a) Intact anterior cruciate ligament (ACL). The axis of rotation is central and therefore internal rotation causes the lateral tibial plateau to move anteriorly and the medial tibial plateau to move posteriorly by similar amounts. (b) Deficient ACL. The pathological axis of rotation is medial; therefore, tibial internal rotation causes a coupled anterior translation and magnifies the movement of the lateral compartment. Reproduced with permission from Amis et al.¹ (2005)

Hughston et al.⁷¹ observed injuries of the mid-third lateral capsular ligament in patients presenting with acute ALRI. Chronic ALRI may develop following isolated ACL injury due to the progressive elongation “stretching out” of the other ligamentous restraints to internal tibial rotation.⁴⁰ Damage of the structures which restrain internal rotation in an ACL-intact knee, will cause ALRI in an ACL deficient knee. Thus, in patients with ALRI, reconstruction of the ACL and the anterolateral structures might seem logical to reduce loads in an isolated ACL reconstruction graft.

3.4 Pivot shift phenomenon:

Although its position in the centre of the knee means that the ACL has a relatively small lever arm to restrain internal tibial rotation, it has been shown that it provided a statistically significant restraint to a 8Nm rotational torque at 10 and 30° knee flexion.⁶ Thus, it is suggested that the tightening of the ACL in full extension forces the tibia to rotate externally and locks the knee at full extension. This principle of the 'screw home' mechanism is lost in an ACL-deficient knee leaving the tibia to rotate internally²⁷ and the lateral tibial plateau to sublux anteriorly in extension. (figure 3.3)

With progressive knee flexion, tension in the ITT pulls posteriorly on the lateral tibia causing a sudden reduction of the lateral tibiofemoral compartment at approximately 30 degree knee flexion.²⁰

There are many different test methods to clinically elicit the pivot-shift phenomenon. Typically tests are performed with a combined internal and valgus moment while bringing the knee from full extension to flexion until the clunk of reduction is felt by the examiner. The internal tibial rotation moment is used to sublux the lateral tibial plateau. This is enhanced by the valgus moment by creating a compressive force, which pushes the lateral tibial plateau anteriorly, because the articular surface is inclined distally and posteriorly. The valgus load also limits the movement of the medial compartment by tensioning the medial collateral ligament (MCL).¹¹⁷ Assessment of the pivot shift test is challenging due to the large inter- and intra-examiner variability¹²⁵, due to different bony geometry, integrity of the anterolateral and medial soft tissues, and hip abduction.^{18,127}

Typically the Pivot-shift test is graded as glide (+), clunk (++) or gross (+++).⁶⁵ Jakob et al.⁷⁷ tried to grade the Pivot shift depending on tibial rotation. The idea behind this was that internal rotation would subluxate the lateral tibial plateau the easiest, thus, representing grade I. Grade 2 is a positive pivot shift in neutral rotation. At grade 3 the pivot-shift test becomes positive in external tibial rotation and therefore indicated a severe soft tissue injury in both the medial and lateral compartments. However, there is no consensus about the role of the peripheral injuries regarding the pivot shift phenomenon. The different layers of the ITT, the lateral meniscus and the capsular ligaments are suggested to increase the pivot shift phenomenon when injured. Damage of the

capsulo-osseous layer of the ITT has been proposed to correlate most with the different grades of the pivot-shift.¹⁶⁴

Based on recent biomechanical data one may speculate that this subluxation of the lateral tibial plateau will increase when an additional anterolateral structure damage is present.⁸⁸ The reduction event in 30-60° of flexion, which is felt as the typical clunk, will then be pronounced similarly. This was also suggested by Galway et al.⁵¹, who found that sectioning of the ITT produced a high-grade pivot-shift test. However, Hassler and Jakob⁶⁴ and later Matsumoto et al.¹¹⁷ found a large increase of tibial internal rotation after sectioning the ITT in an ACL-deficient knee, but the clunk of the Pivot-shift test disappeared. These findings may imply that, due to the missing pull from the ITT, the anterolateral subluxation can be so excessive that the lateral tibial plateau never reduces. Another factor which influences the characteristics of the pivot-shift test is the integrity of the MCL.

Donaldson et al.³⁵ observed that the pivot shift diminished in patients with ACL rupture and grade three MCL injury when examined under anaesthesia. It is likely that this is due to the deficiency of the medial structures resulting in medial opening of the knee, rather than compression of the lateral compartment, when valgus force is applied during the pivot shift test.

Thus, interpretation of the pivot shift in the clinical setting may be challenging and a specific test to precisely identify and grade ALRI is missing.

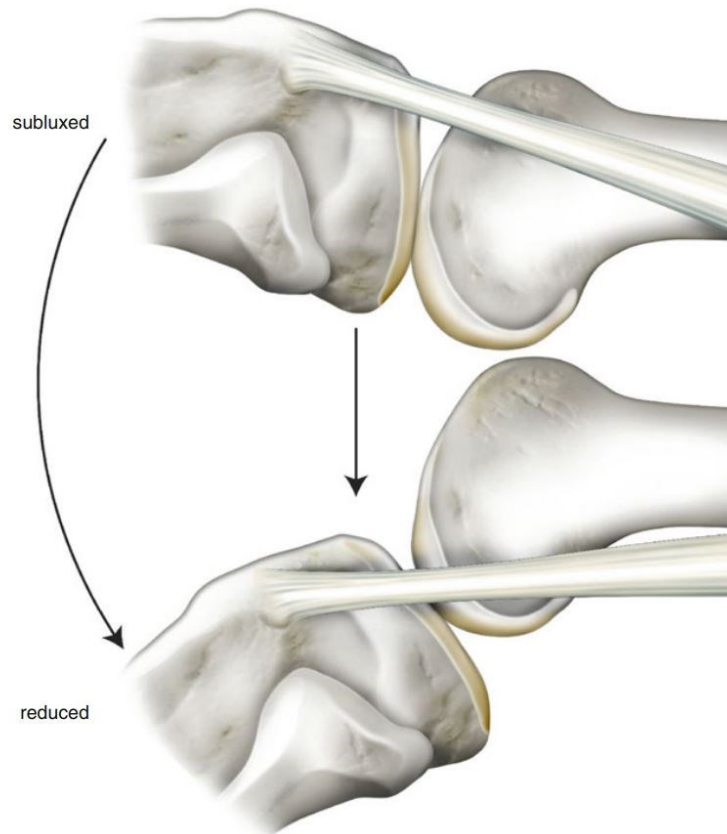


Figure 3.3 At full extension the lateral tibial plateau can be subluxated, due to the loss of the `screw home mechanism` in anterior cruciate ligament deficient knees. When the knee gets flexed the iliotibial increasingly pulls the lateral tibial plateau backwards until it gets reduced, which is felt by the examiner. Reproduced with permission from Lord and Amis¹⁰⁹ (2017)

3.5 Structural properties of the anterolateral structures

In Werner Mueller`s¹²¹ anatomical dissection video of the lateral side of the knee made for the ESSKA, he described a principle of “Big structures, big function, small structures, small function”. Not only is size an important factor in how a structure acts to control motion, but fibre orientation (axis of alignment) is key. The ITT is not only large but is tethered to the femoral metaphysis via the lateral intermuscular septum and the Kaplan fibres, therefore the capsulo-osseous layer forms a sling around the posterolateral aspect of the lateral femoral condyle, which is well aligned to restrain the anterior subluxation of the lateral tibial plateau.¹³

The ALL has been found to have a mean tensile strength of 49,9 – 319,7 N and a mean stiffness of 20 – 26 N/mm. The discrepancy in mean tensile strengths reported by previous studies is likely to be due to differences in what the authors described and tested as the ALL. Zens et al.¹⁸³ separated an isolated ALL structure, according to only one available anatomic paper at this time, which only had an ultimate strength of 50 N. Other studies obviously included the capsulo-osseous layer of the ITT and found an ultimate tensile strength of 175 – 319N and a mean stiffness of 20 – 26 N/mm.^{135,153} This is similar to the structural properties of the deep MCL, which is protected by the superficial fibres of the MCL¹³⁹, like the anterolateral capsule and the deep fibres of the ITT are sheltered by the superficial ITT. An 18 mm wide strip of the ITT has been reported to have a mean tensile strength of 769 N.¹²⁴ It is likely from the size and fibre orientation that the ITT is going to be the primary restraint to internal tibial rotation.

3.6 Length change pattern of the anterolateral structures

In ligament surgery the term isometry indicates the constant length of a graft during range of motion. True isometry can only apply to a point-to-point connection. This is not possible to replicate in a reconstruction graft where there will be differing length change patterns for fibres attaching to different parts of the attachment site¹⁸¹. Native ligaments, such as the ACL and MCL are often flat and twisted about their axis, reducing excessive fibre length changes at each end of the attachment¹²². It has also been shown that for reconstruction grafts isometry depends more on the femoral attachment than the tibial attachment.⁶⁶

It seems logical that the area at the axis of knee flexion, the transepicondylar axis, will be near to isometric, because the posterior aspects of the femoral condyles are almost spherical. However, due to the knee's roll-glide mechanism the lateral condyle rolls posteriorly on the increasing posterior tibial slope. Sidles et al. showed that this makes it impossible to find a perfect isometric tibiofemoral connection on the lateral side of the knee¹⁴⁹. They also found that a structure attaching anterior to

the epicondyle will stretch with knee flexion, while structures attaching posterior to the epicondyle will slacken with knee flexion.

Looking at the ALL, two different attachment areas have been described. Vincent et al.¹⁶⁸ and Claes et al.²² described the attachment site as anterior to and at the epicondyle, while several other studies^{33,153} described an attachment area proximal and posterior to the epicondyle. An ALL, with an anterior attachment site, has been found to tension with knee flexion, with the distance between attachment sites increasing in length by almost 20%⁸⁹. This means that it cannot be tight at early flexion angles and only control laxity at higher flexion angles. Conversely an ALL which attaches posterior to the epicondyle may only control laxity towards extension, and then slackens with knee flexion. This also applies to the superficial ITT, which can be divided into anterior and posterior fibre regions, which act reciprocally. The posterior fibre region is tight in extension, while the anterior fibre region is tight in flexion.

Dodds et al.³³ measured the separation distance between attachment sites by threading a suture along the ligament fibres attaching it to the tibia and a transducer. If the tibia was rotated internally the separation distance increased (that is, the structure was stretched, causing tension to resist the tibial motion), while external rotation decreased the separation distance. (figure 3.4) Thus, anterolateral structures attaching posterior to the lateral femoral epicondyle are tight in early flexion angles and, due to their oblique course, are able to restrain the anterior subluxation of the lateral tibial plateau.

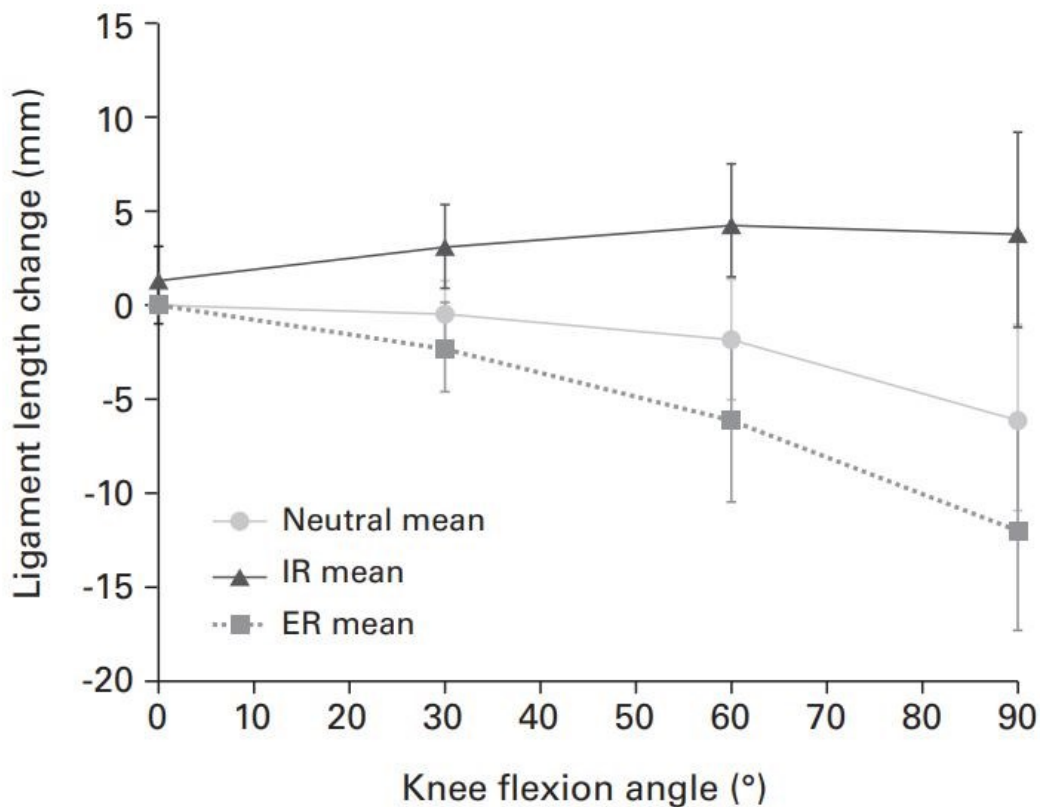


Figure 3.4 Separation distance (mm) between the tibial and femoral attachments of the anterolateral ligament of the knee in 0°, 30°, 60°, and 90° (circle graph), with 5Nm internal rotation (triangle) and external rotation (square). Reproduced with permission from Dodds et al.³³ (2014)

3.7 Conclusion

Typical ACL trauma mechanisms involve the anterior subluxation of the lateral tibial plateau. This motion is restrained by the ACL and the anterolateral structures of the knee. Due to loss of the `screw home mechanism` after an ACL rupture, the pivot shift mechanism can be elicited by the physician and a `clunk` is felt, when the ITT reduces the anterolateral side of the knee. The dominance of the ITT in restraining ALRI may be expected when considering that it is many times stronger and stiffer than the underlying capsular ALL^{19,86}, and that it has a much larger moment arm to resist tibial rotation torque than the centrally-placed ACL. It is not clear yet, which structure is the primary and secondary restraint to internal tibial rotation and the pivot shift test. An improved

understanding of the roles of these structures is needed to help develop reconstructions that restore stability and normal knee kinematics.

4 The role of the anterolateral structures in the ACL-intact and deficient knee.

The majority of this chapter has been published in The American journal of Sports Medicine

The role of the anterolateral structures and the ACL in controlling laxity of the intact and ACL-deficient knee; The American Journal of Sports Medicine, Volume 44 , Number 2, pages: 345-354
C Kittl, H El-Daou, KK Athwal, CM Gupte, A Weiler, A Williams, AA Amis

For permission see Chapter 9 (Appendix)

4.1 Background

Injuries of various structures of the anterolateral side of the knee have been suggested to cause increased internal tibial rotational laxity. Hematomas¹²¹ and avulsion⁴⁷ of the proximal attachment of the ITT (Kaplan's fibers) have also been noted in patients suffering from an increased rotational instability of the knee. Similarly, the mid-third lateral capsular ligament and the biceps femoris muscle complex have been linked to the Segond fracture, which indicates severe rotational instability⁵⁸. With the transition to arthroscopic ACL reconstruction, interest in the role of the peripheral structures faded. However, recent descriptions of the ALL have led to renewed interest in these structures, which may play a role in controlling rotational laxity of the knee.^{22,33,67,165}

4.2 Aims and Hypothesis

The aim of this chapter is to determine the contribution of the anterolateral structures and the ACL in restraining 1. Anterior-posterior (AP) laxity. 2. Internal-external (IE) tibial rotation laxity. 3. Internal rotation laxity in response to a simulated pivot-shift (sPS) test in the ACL-intact and ACL-deficient knee. Based on the published articles, it was hypothesized that both the ITT and ALL would contribute to resisting anterolateral knee laxity. Knowledge of these contributions would aid the design of improved surgical procedures for stabilizing the knee.

4.3 Methods:

4.3.1 Specimen preparation:

18 fresh-frozen cadaver knee specimens were procured from a tissue bank after approval from the local research ethics committee. Two specimens were used to develop the sectioning and robotic testing protocol and the remaining 16 knees were included for final data analysis (mean age: 69; range: 52-93; 8 male, 8 female; 6 left, 10 right). Eight knees were tested with the ACL intact, and the remaining eight knees were used to test the ACL deficient state. In the latter knees the ACL was transected mid-substance through a 15mm mid patellar tendon incision before testing. A MacDonald's dissector was slid into the gap between the cruciate ligaments with the knee flexed, then a scalpel cut laterally/distally away from the dissector until there was a sudden increase in anterior laxity of the knee that indicated complete ACL deficiency. Before testing, the knee specimens were manually tested using common clinical tests (Lachman test, Varus/Valgus stress test, Posterior drawer test) in order to confirm ligamentous integrity. Lack of damage to other ligamentous structures, the cartilage, and the menisci was verified after testing was completed. The knees were stored in polyethylene bags at -20°C , then thawed at room temperature 24h prior to testing. The skin and subcutaneous soft tissue were resected, leaving the muscles, tendons and ligaments intact. The tibia and the femur including all soft tissues were then cut approximately 120mm and 200mm from the joint line respectively. A tricortical screw was used to maintain the anatomic position of the proximal tibio-fibular joint. The tibia was securely potted into a cylindrical stainless-steel tube using polymethylmethacrylate (PMMA) bone cement. The centre of the pot was aligned to the tibial axis of rotation at the interspinous space using a custom made alignment jig through a 15 mm longitudinal incision in the patellar tendon⁴. (figure 4.1) The femur was then potted at 0° knee flexion, while the posterior condylar axis was aligned parallel to the base fixture orientation of the robot. (figure 4.2) The specimens were left mounted to the robot and kept moist throughout the whole experiment.

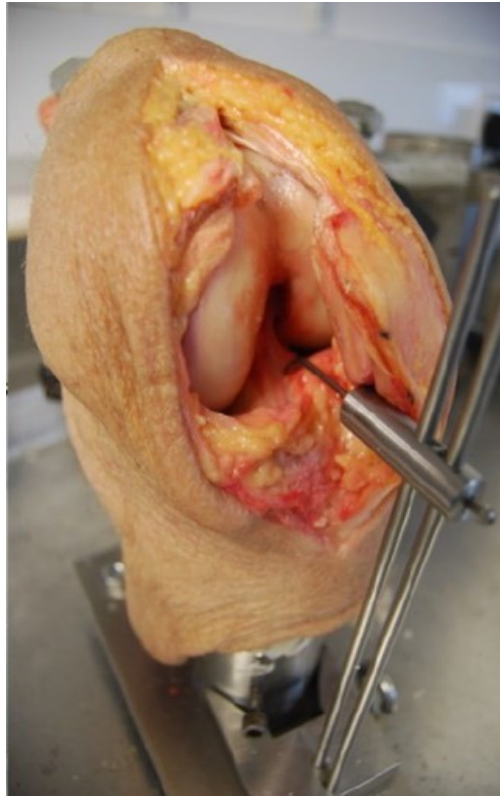


Figure 4.1 Alignment jig in order to position the centre of the tibial pot with the tibial axis of rotation. The tip of the needle was placed in the middle of the tibial eminence, when the pot was lean on the base of the jig, which was first introduced by Amis and Scammell⁴. Reproduced with permission from Athwal KK¹⁰, Assessing the contributions of soft tissue to the stability of total knee replacements; a thesis for the degree of PhD and Diploma of Imperial College. (2016)

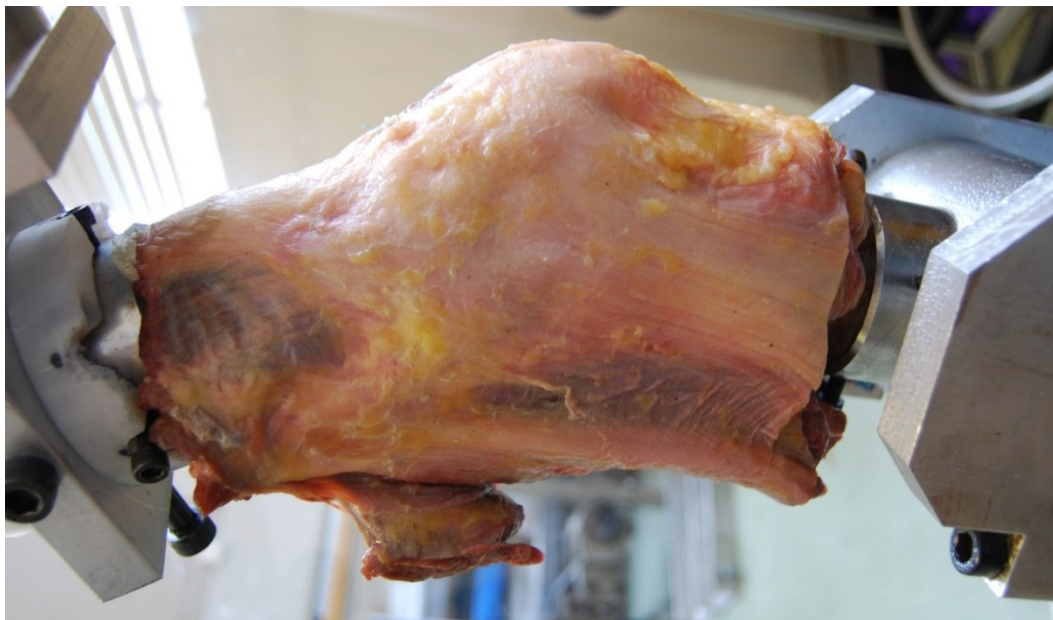

Figure 4.2 Intact-state of the knee mounted into the robot. The femur was attached to the base (right), whereas the tibia was attached to the moving arm of the robot (left)

4.3.2 Tissue resection and cutting order:

Sequential resection of the anterolateral structures and transection of the ACL was performed whilst the knee remained mounted in the robot at 30° knee flexion. The sequence of cutting was from superficial to deep:

1. Superficial layer of the ITT (the sITT). A curved longitudinal cut from the anterior border of Gerdy's tubercle along the lateral patellar border (lateral retinaculum) was performed to resect the sITT away from its anterior attachment. The biceps femoris muscle complex was then completely resected, including the capsulo-osseus biceps femoris confluence and several tendinous and aponeurotic arms of both the long and short heads of the biceps femoris. The remaining strip of the sITT was then carefully resected from the deep and capsulo-osseus layers.
2. The deep and capsulo-osseus layer of the ITT (the dcITT) including the Kaplan fibres were resected from their proximal femoral attachment and distal tibial attachment at the lateral tibial rim immediately posterior to Gerdy's tubercle. (figure 4.3)

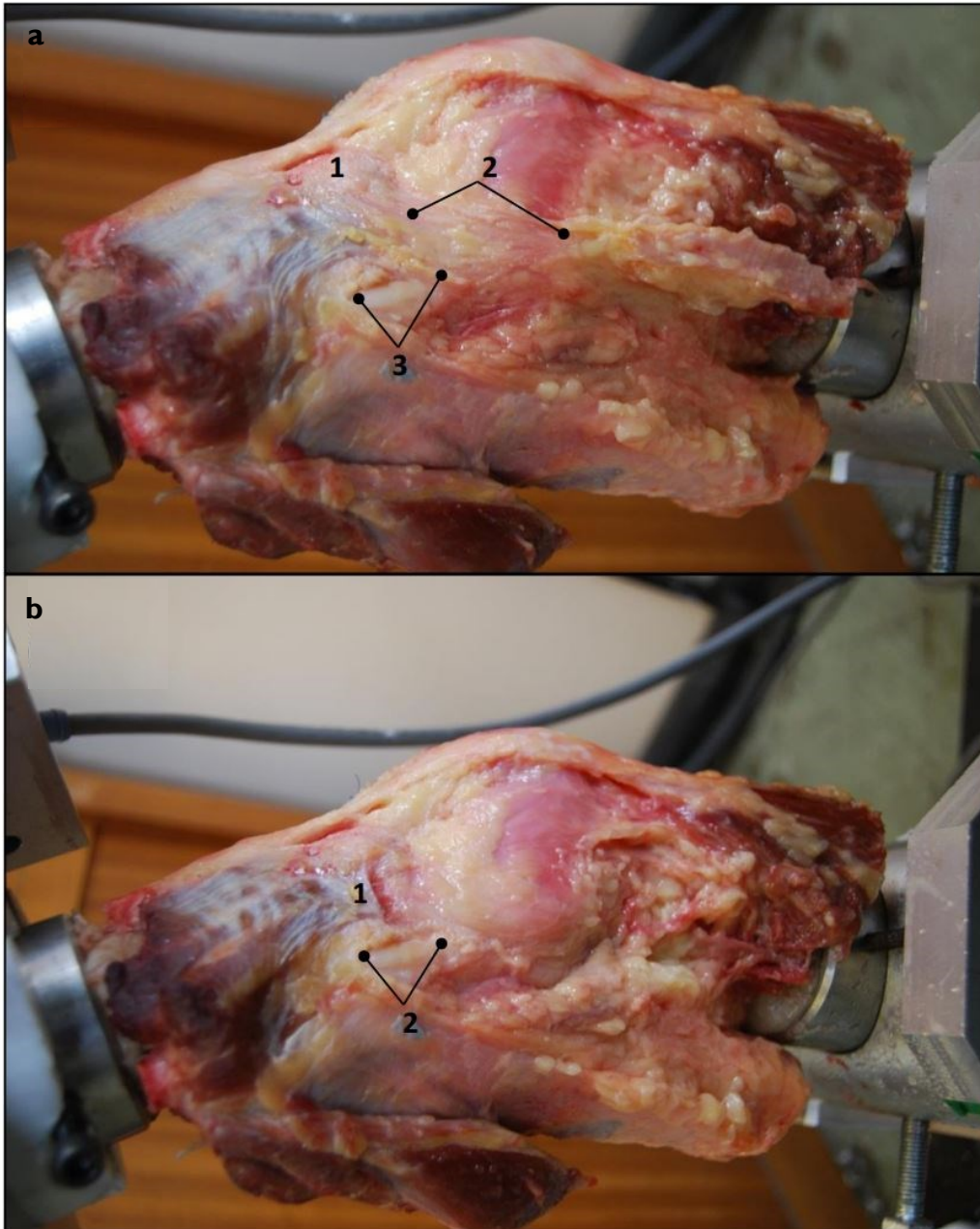


Figure 4.3 Lateral aspect of a left knee. (a) Superficial layer of the iliotibial tract (ITT) and biceps femoris muscle complex removed. Gerdy's tubercle (1), capsulo-osseus layer of the ITT (2) inserting posterior to Gerdy's tubercle, lateral collateral ligament (LCL) (3). (b) Attachment of the resected capsulo-osseus layer of the ITT (1), LCL (2).

3. After removing the dcITT, the remaining fibres running superficial to the LCL and inserting posterior and proximal to the lateral femoral epicondyle on the femur and posterior to Gerdy's tubercle on the tibia were resected (figure 4.4). Fibres in this zone have previously

been defined as the ALL by Dodds et al.³³ After this structure had been resected only the capsule remained on the anterolateral aspect of the knee.

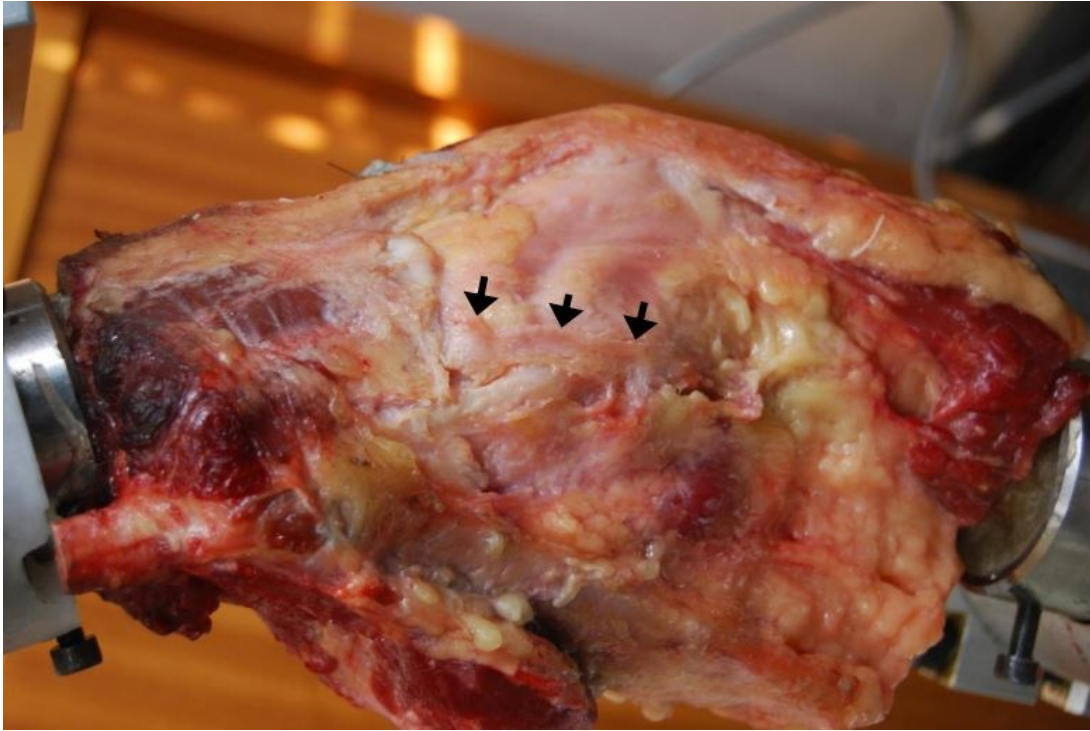


Figure 4.4 Lateral aspect of a left knee: the femur extends proximally to the right, and the tibia extends distally toward the left with the patella at the top. Shown after removal of the deep and capsulo-osseous layer of the iliotibial tract, leaving the extracapsular anterolateral ligament exposed (arrows), passing over the proximal lateral collateral ligament. The femoral attachment is proximal and posterior to the epicondyle, and the tibial attachment is midway between the Gerdy tubercle and the head of the fibula.

4. The whole meniscomfemoral and meniscotibial anterolateral capsule was resected. This included the midthird lateral capsular ligament and other fibres described as an ALL¹⁶⁵. (figure 4.5)

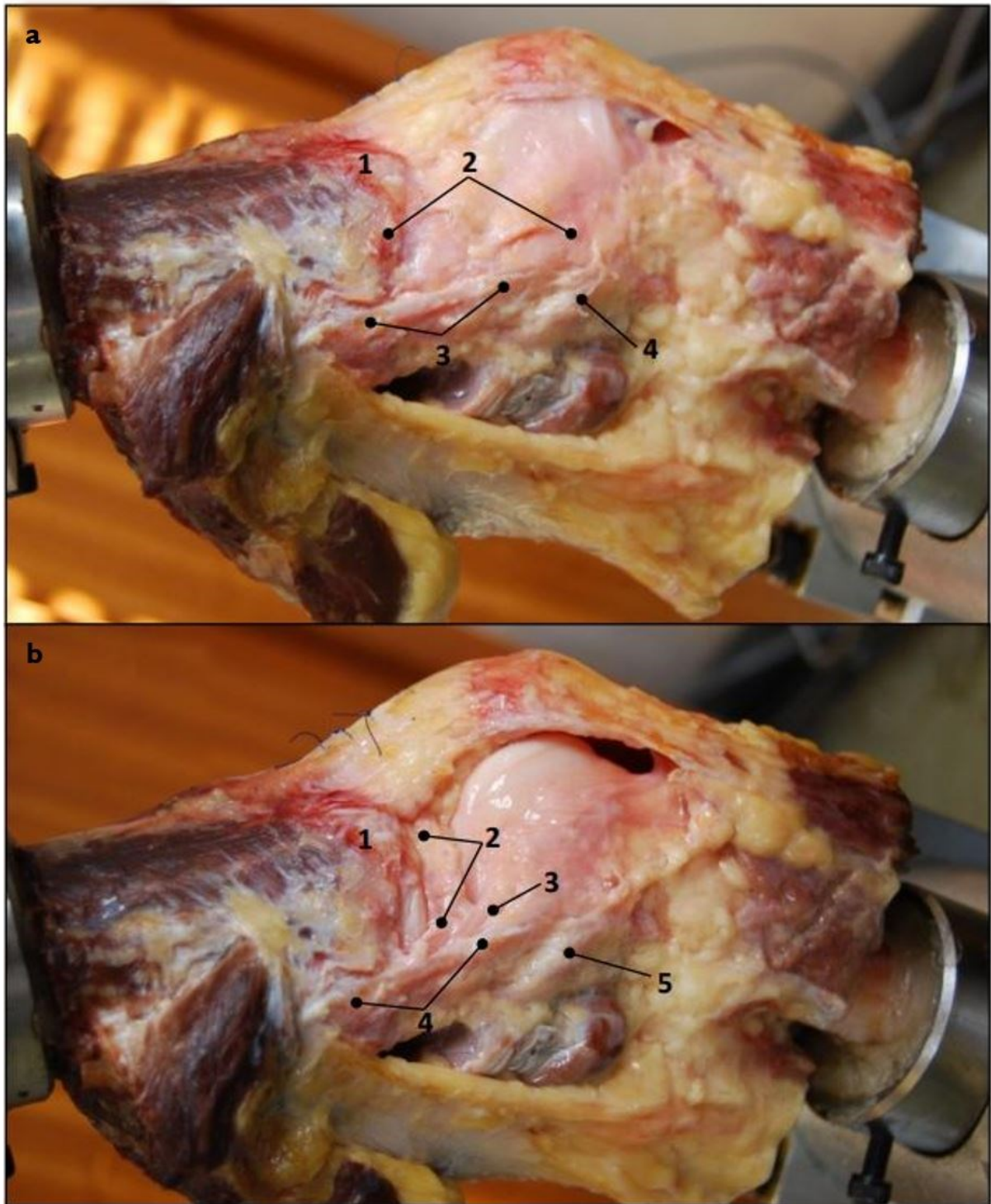


Figure 4.5 Lateral aspect of a left knee. (a) All structures running superficial to the lateral collateral ligament (LCL) were removed. Gerdy's tubercle (1), anterolateral capsule (2), LCL (3), femoral insertion of the lateral head of the gastrocnemius muscle (4). (b) After removal of the anterolateral capsule, Gerdy's tubercle (1), lateral meniscus (2), popliteus tendon (3), LCL (4), femoral attachment of the lateral head of the gastrocnemius muscle (5).

5. The ACL was cut midsubstance in the ACL-intact group at 90° knee flexion. (figure 4.6)

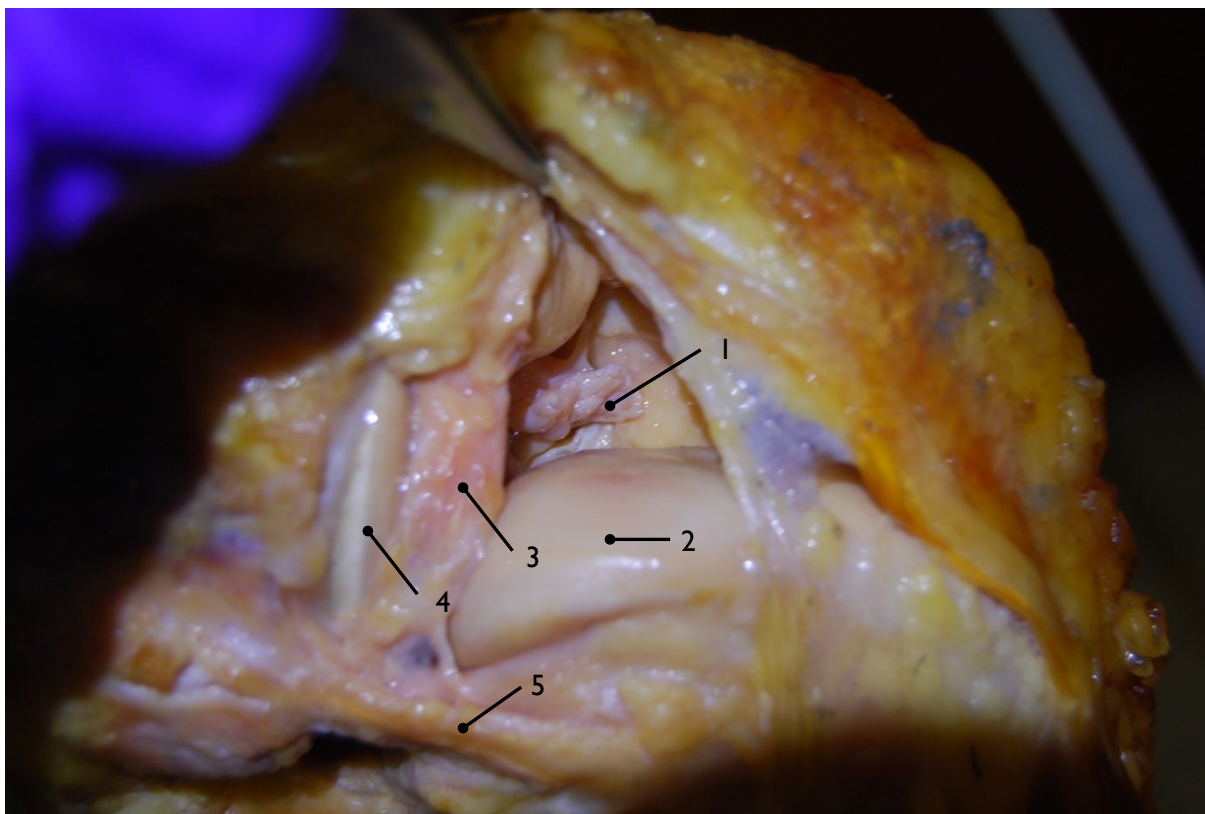


Figure 4.6 Left knee, lateral side after removal of the complete anterolateral structures and midsubstance cut of the anterior cruciate ligament (ACL) showing the tibial stump of the ACL (1), the lateral femoral condyle (2), the lateral meniscus (3), the anterolateral tibial rim (4), and the intact lateral collateral ligament (5).

After completion of the initial testing stages listed above in knees 1 to 4, the protocol for knees 5 to 8 was extended in order to test additional structures on the medial side. This followed data processing on the first four knees, which showed a large residual resistance to tibial internal rotation after resecting/cutting the anterolateral structures and ACL. Unfortunately, because work on the medial structures had not been planned, the test protocol had not allowed for remounting the knees into the robot with sufficient precision to allow their testing to be extended, and so knees 1 to 4 could not be included in the extended protocol. Due to the length and complexity of the testing protocol resulting from the addition of medial cutting sequences, we decided against performing this

in ACL deficient knees. A separate study, outside the scope of this thesis, to investigate the role of the medial structures in the ACL deficient knee was planned

The following cuts were performed on four knees of the ACL-intact group after remounting the knees to the robot:

6. The medial collateral ligament complex, including the deep medial collateral ligament (dMCL) and the superficial collateral ligament (sMCL), was transected.
7. The posterior medial corner (PMC) including the posterior oblique ligament (POL), the semimembranosus tendon (SM) and the posterior medial capsule.

Table 4.1. Sequential cuts and corresponding anatomical structures

Cuts	Corresponding anatomical structure
Cut 1 (sITT)	Superficial layer of the iliotibial tract (ITT), biceps femoris muscle complex (including tendinous and aponeurotic arms of the long and short head.), biceps-capsuloosseous iliotibial tract confluens, lateral retinaculum, lateral patellofemoral ligament, lateral patellomeniscal ligament.
Cut 2 (dcITT)	Deep and capsulo-osseus layer of the ITT (supracondylar insertion, insertion near the septum, and retrograde insertion)
Cut 3 (ALL)	All structures running superficial to the lateral collateral ligament (anterolateral ligament; ALL described by Dodds et al., superficial capsule described by Seebacher et al.)
Cut 4 (Cap)	Whole anterolateral capsule (ALL described by Claes et al., Vincent et al., and Helito et al.)
Cut 5 (ACL)	Anterior cruciate ligament
Cut 6 (MCL)	Medial collateral ligament (superficial and deep portion)
Cut 7 (PMC)	Posteromedial corner (posterior oblique ligament, semimembranosus tendon, posteromedial capsule)

4.3.3 Testing protocol:

Prior to testing, the knee was manually flexed and extended 10 times to minimize tissue hysteresis. This has previously been shown to be sufficient to achieve a steady state.¹¹⁶ The tibia and the femur were then mounted to the end-effector and to the fixed base unit of the robot at 0° knee flexion, respectively. In order to find the starting position at 0° all forces and moments acting across the tibio-femoral joint were neutralized. The robot automatically defined the path of passive motion of the knee across the range of flexion and extension by minimizing constraining forces and moments acting across the knee. The knee could then be moved to each desired angle of flexion and the simulated clinical tests were assessed, while all remaining forces/torques were minimized.

Simulated knee laxity tests were performed at 0°, 30°, 60° and 90° flexion, where anterior-posterior translation and internal-external rotation laxity were tested in response to a 90N anterior-posterior force and 5Nm internal-external torque respectively. The robot constrained the knee to remain at the chosen angle of flexion while the force or torque was applied, but was programmed to seek zero load in the secondary degrees of freedom of motion when the tibia was moved away from its initial position of equilibrium. Thus, for example, the tibia was allowed to rotate about its long axis and in valgus/varus, and also to move in medial/lateral and proximal/distal translations when an anterior translation was imposed. A simulated pivot shift test (4Nm internal tibial rotation and 8Nm valgus rotation) was performed at 15°, 30° and 45° flexion. The internal tibial torque was applied first and held constant while the valgus torque was applied and released, and tibial motion in the remaining degrees of freedom was measured, such as coupled anterior translation^{83,179}. After each resection/cut was performed, the same motion of the simulated laxity tests of the intact state was replayed and the force/torque versus displacement data were recorded. Thus, the decrease in force/torque represented the contribution of the resected/cut structure in restraining the laxity test. (figure 4.7) Each simulated laxity test was repeated 3 times. The loads were selected to be at the lower range of those applied during clinical examination of knee laxity, in order to prevent 'stretching-out' of the remaining structures after some had been resected/cut. For example, 89N of

ATT drawer force was chosen as this figure accords to the first tone heard when performing anterior laxity testing using a KT1000.

Internal and external rotation (5Nm) was tested at only 30° for the four remounted knees of the ACL intact group in order to test the structures on the medial side. Remounting the specimen for testing the medial side was not as straight forward as expected, because of residual forces/torques were acting on the knee specimen. These were minimised (< 10 N/ 0.5 Nm) by manually adjusting the moving arm of the robot in 30° flexion towards the initially saved position for the intact state of the knee. This was possible even though the anterolateral side of the knee and the ACL were already resected. The intact kinematics were then replayed by moving the robot in position control to reproduce the path of motion recorded earlier when the knee was intact and the resulting forces and torques were used as a reference prior to any additional cuts.

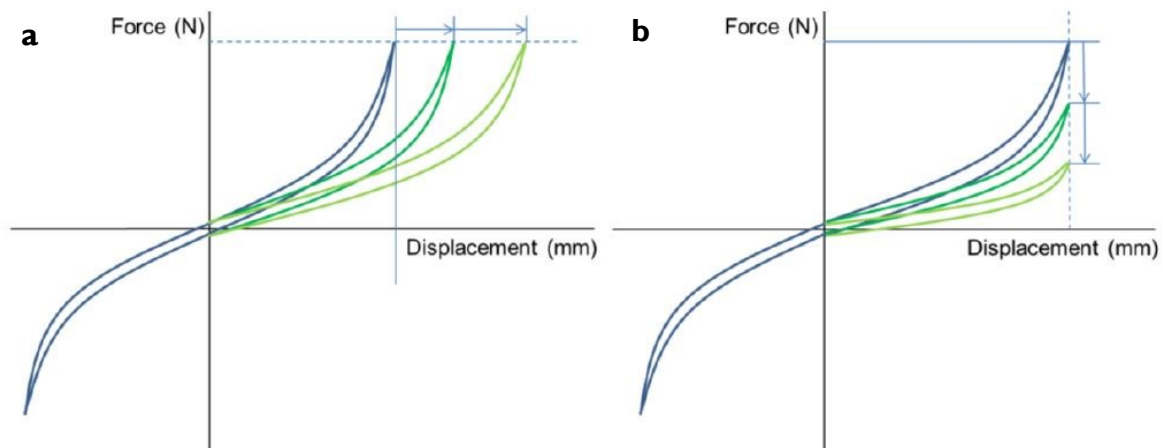


Figure 4.7 (a) Example hysteresis graph of a force-controlled setup of the robot. After cutting two structures (light and dark green) in an intact knee (blue) the displacement increased with the same force applied. (b) Example hysteresis graph of a displacement-controlled setup. The robot replays the path of motion from the intact state (blue) of the knee after cutting the structures (green). The decrease in force representing the contribution of the transected structure. Reproduced with permission from Athwal KK¹⁰, Assessing the contributions of soft tissue to the stability of total knee replacements; a thesis for the degree of PhD and Diploma of Imperial College, (2016)

4.3.4 Robotic biomechanical testing system:

The biomechanics testing platform (figure 4.8) was a six degree-of-freedom industrial robot (Stäubli TX90, Stäubli Co., Pfaffikon, Switzerland) and a six axis universal force-moment sensor (UFS)

(Omega85, ATI Industrial Automation). Similar configurations have been used previously⁵⁰. The robot had a maximum load capacity of 200N and a repeatability of ± 0.03 mm. The UFS was mounted between the specimen's tibia and the robot end-effector using a custom made mechanical fixture and had a resolution of 0.3N in the x and y-axes and 0.4N for the Z axis. The UFS could measure torques up to 80Nm in all three axes with a resolution of 0.013Nm about the x and y axes and of 0.009Nm about the z axis. This robotic testing setup was chosen due to its accuracy and it can be considered as the “gold standard” for biomechanical “cutting studies”.

For the initial state of each knee (ACL intact group and ACL deficient group), the robotic platform was controlled to find the passive path of flexion-extension by minimizing the forces and torques, and then to simulate clinical laxity tests, while recording the position and the corresponding forces and torques at every 0.04 s.




Figure 4.8 Setup of the six degrees-of-freedom robotic system (1-6). 7 universal force/moment sensor, 8 tibial fixture, 9 femoral base unit.

4.3.5 Data Analysis:

A power calculation based on prior work on rotatory knee laxity⁹¹ determined that a sample size of 8 would allow identification of changes of translation and rotation of 2.1 mm and 1.2° respectively with 80% power and 95% confidence. Based on previously published studies these changes in laxity are below the clinical threshold of 3 mm ATT³⁰ and 10° rotation¹³.

Force or torque versus displacement graphs were plotted for each simulated laxity test, each flexion angle, and each knee. The force/torque endpoints of the three cycles were averaged. (figure 4.9) In order to obtain the internal rotation torque endpoint in case of the simulated pivot-shift the torque value was measured when the valgus torque was at its peak. (figure 4.10) The decrease in force/torque after each cut was then converted into percentage of the intact state/deficient state, which acted as a reference.

A repeated-measures analysis of variances (ANOVA) was used to assess the main effects of each independent variable (deficiency status and flexion angle) and the interaction between them for the ACL-intact and ACL-deficient groups. The dependent variables were the percentage contributions in restraining 1. Anterior translation; 2. Posterior translation; 3. Internal rotation; 4. External rotation; and 5. Internal rotation in response to a simulated pivot-shift test. Pairwise comparisons with Bonferroni correction to maintain 95% confidence were used to compare each contribution at different flexion angles.

Independent sample t-test or the Mann-Whitney U test for non-normally distributed data were used to address statistical significances between the ACL-intact and ACL-deficient group for each simulated test mentioned above.

Statistical analysis was performed in Statistical package for social science (SPSS) version 21, with significance level set at $P < 0.05$.

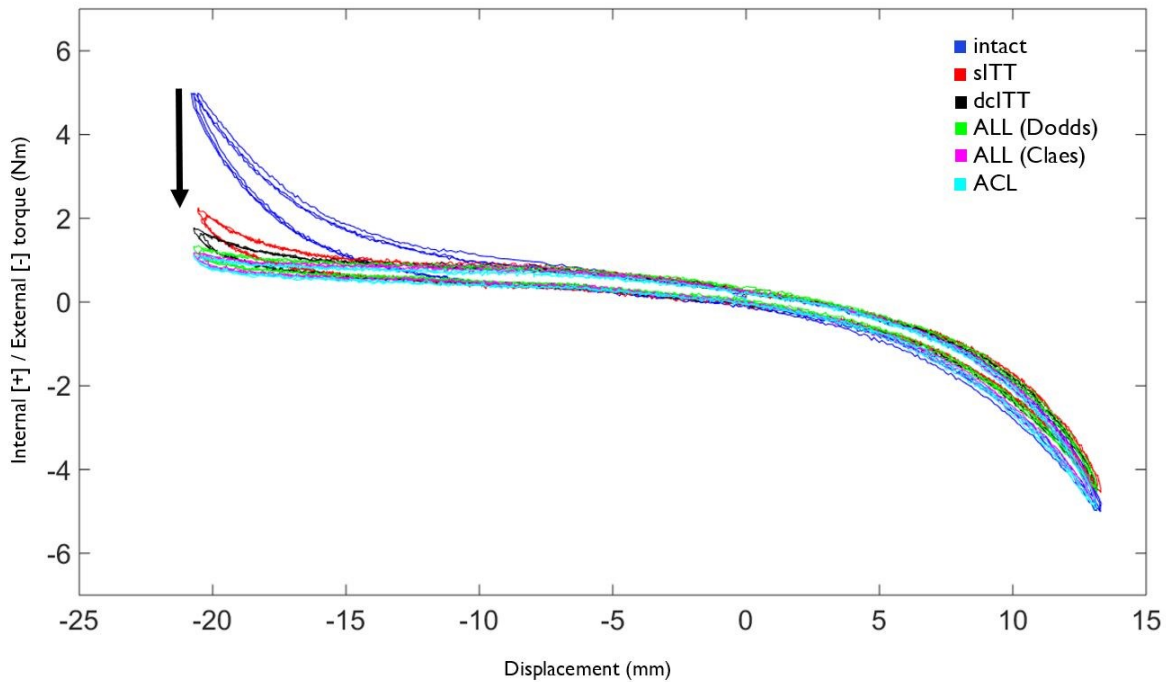


Figure 4.9 Sample hysteresis graph of internal [+] /external [-] rotation at 90° flexion of knee 6 (anterior cruciate ligament intact). Y-axis represents the torque [Nm], whereas the X-axis represents the tibial rotation [degree]. Each motion was replayed three times by the robot (same colour). For example, the drop in torque (black arrow) between the blue curve (intact state of the knee) and the red curve (superficial iliotibial tract cut) presented the contribution of the superficial iliotibial tract. sITT = superficial iliotibial tract; dcITT = deep and capsule-osseus layer of the iliotibial tract; ALL = anterolateral ligament; ACL = anterior cruciate ligament.

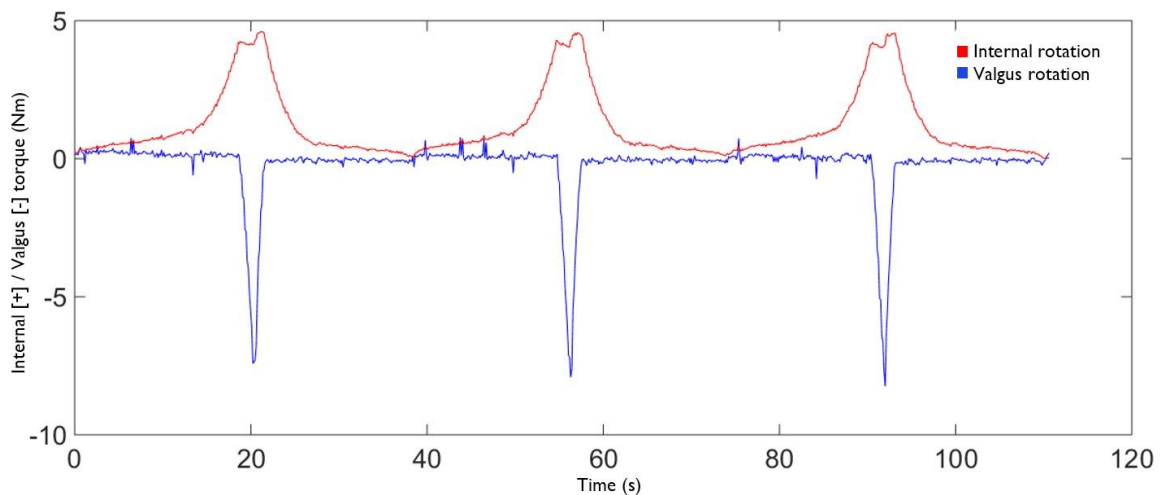


Figure 4.10 Sample hysteresis graph of the simulated pivot shift test at 15° knee flexion (anterior cruciate ligament intact; three cycles). X-axis represents the time (seconds), whereas the Y-axis presents the torque. Positive values indicate internal rotation (4Nm), and negative values indicate valgus torque (8Nm).

4.4 Results:

4.4.1 Anterior and posterior tibial translation:

Overall, the anterolateral cutting sequence caused a significant increase ($p < .001$) in anterior translation laxity for both the ACL-intact and ACL-deficient groups. For the posterior translation only the ACL-intact group showed a significant effect ($p < 0.05$). The interaction with the flexion angle was significant ($p < .001$) when applying an anterior translation force, meaning that the contributions of each of the resisting structures varied across the arc of flexion.

ACL-Intact group:

Only the ACL had a significant role in restraining a 90N tibial anterior translation force ($p < .001$ at 0° , 30° , 60° and 90° knee flexion) (figure 4.11; Table 4.2). All other sectioned structures (Table 4.1) had only a small contribution. Furthermore, there was no significant contribution in restraining a 90N posterior tibial force for the ACL and all tested anterolateral structures. (figure 4.12)

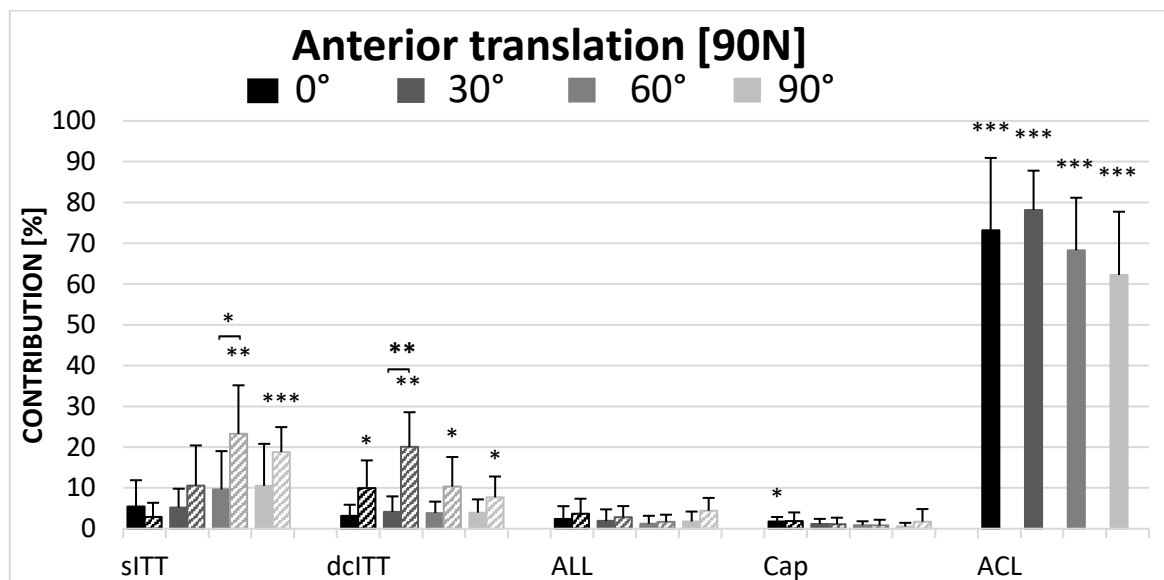


Figure 4.11 Contribution [%] of tested structures in restraining a 90N anterior tibial translation at 0° , 30° , 60° , and 90° . Cross-hatched areas indicate results from the anterior cruciate ligament deficient group. sITT=superficial layer of the iliotibial tract; dcITT= deep and capsulo-osseus layer of the iliotibial tract; ALL= anterolateral ligament; Cap= anterolateral capsule; ACL= anterior cruciate ligament. Asterisks note significant differences to the previous cut, whereas asterisks with brackets note significant differences to the ACL deficient state of the knee. Statistical significance: * $p < .05$; ** $p < .01$; *** $p < .001$. (Shown as mean + SD, $n=8$)

Table 4.2 Contribution [%] of each structure restraining a 90N anterior translation force (for abbreviations see Table 4.1)

Cuts	0°		30°		60°		90°	
	Intact	Def.	Intact	Def.	Intact	Def.	Intact	Def.
sITT	5.4±6.4	2.9±3.4	5.2±4.6	10.6±9.9	9.6±9.4	23.3±9.4	10.5±10.3	18.8±6.1
dcITT	3.2±2.7	9.9±6.8	4.1±3.8	20.1±8.5	3.8±2.8	10.3±7.2	3.9±3.3	7.7±5.1
ALL	2.5±3.1	3.7±3.7	1.9±2.8	2.8±2.7	1.2±2.0	1.7±1.8	1.8±2.4	4.4±3.1
Cap	1.8±1.1	1.8±2.2	1.2±1.3	1.1±1.6	0.8±1.0	0.8±1.4	0.5±0.9	1.7±3.1
ACL	73.2±17.7	-	78.1±9.7	-	68.3±12.9	-	62.2±15.5	-

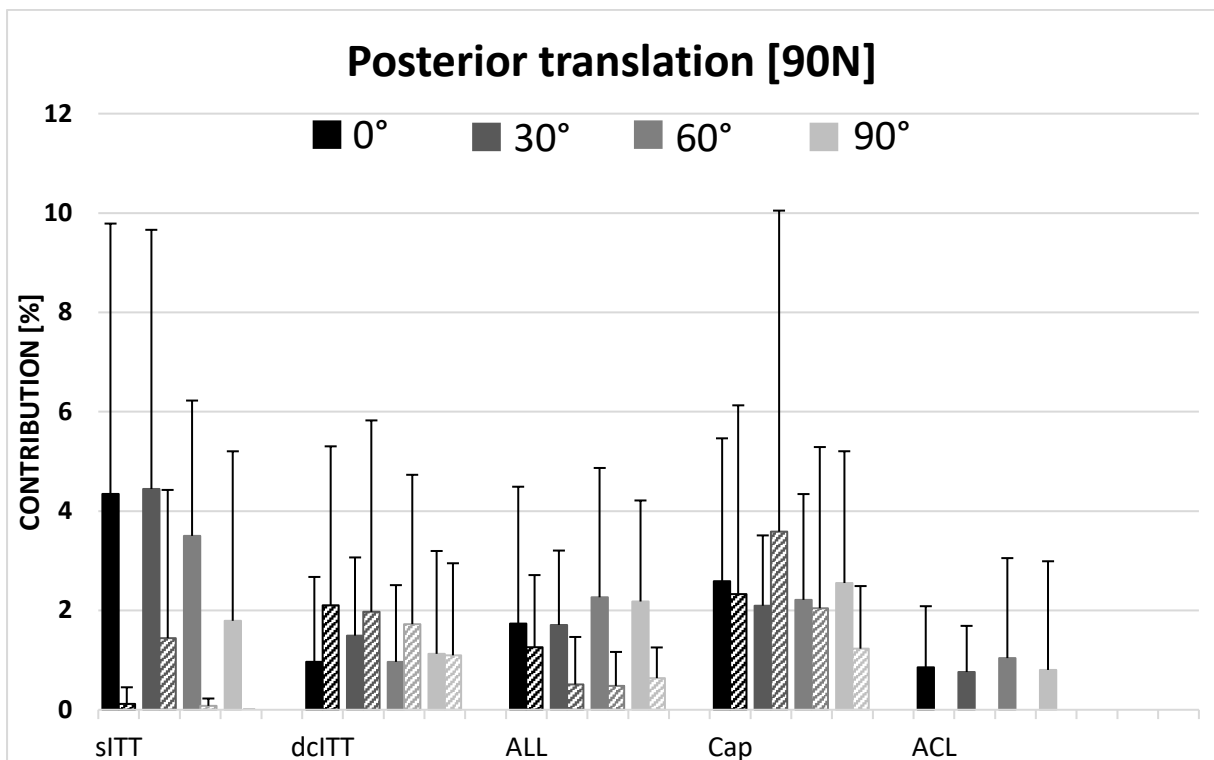


Figure 4.12 Contribution [%] of tested structures in restraining a 90N posterior tibial translation at 0°, 30°, 60°, and 90°. The anterolateral structures had no significant contribution to posterior tibial translation. Cross-hatched areas indicate results from the anterior cruciate ligament deficient group. sITT=superficial layer of the iliotibial tract; dcITT= deep and capsulo-osseus layer of the iliotibial tract; ALL= anterolateral ligament; Cap= anterolateral capsule; ACL= anterior cruciate ligament.

ACL-Deficient group:

The sITT significantly restrained a 90N tibial anterior translation at 60° ($p<.01$) and 90° ($p<.001$), whereas the dcITT presented a significant contribution at 0° ($p=.05$), 30° ($p<.01$), 60° ($p=.05$), and 90° ($p=.04$). Compared to the ACL-intact group, all structures tended to make a higher contribution

in restraining a 90N anterior tibial translation, but that change was only statistically significant for the sITT at 60° ($p=.04$) and the dcITT at 30° ($p<.01$).

Similar to the intact group none of the structures demonstrated a significant contribution to restraining a 90N posterior translation force.

4.4.2 Internal and external tibial rotation:

The state of the ACL (intact versus deficient) had a significant effect ($p<.001$) on the contributions of the structures of interest in restraining both internal and external rotation across the whole range of motion. Furthermore, the percentage contributions changed significantly ($p<.001$) with knee flexion angle, when applying an internal rotation torque. For the external rotation only the ACL intact group showed small, but significant ($p=0.042$) changes of percentage contributions with flexion angle.

ACL-Intact group:

At full extension only the ACL had a statistically significant ($p<.01$) contribution to restraining a 5Nm internal rotation torque. (figure 4.13, Table 4.3) The tested anterolateral structures collectively contributed a slightly higher resistance ($23\pm 18\%$), but none of them made a significant individual contribution. At 30°, 60° and 90° knee flexion both the sITT ($p=.012$; $p<.01$; $p<.01$), and dcITT ($p<.01$; $p=.033$; $p=.023$) provided a significant resistance to tibial internal rotation torque. The sITT had a greater impact at high flexion angles, reaching $56\pm 20\%$ contribution at 90°, whereas the dcITT showed a greater contribution at low flexion angles, reaching $26\pm 9\%$ at 30°. The whole ITT presented therefore a total contribution of $44\pm 10\%$ at 30°, $76\pm 11\%$ at 60°, and $71\pm 15\%$ at 90°. The extracapsular ALL described by Dodds et al.³³ displayed its highest contribution at 30° knee flexion ($11\pm 10\%$), which was not significant. Similarly, a significant role for the anterolateral capsule was not found at any tested knee flexion angle.

None of the tested structures made a significant contribution to restraining a 5Nm external tibial rotation torque, except the sITT at 30° (7±3%; p=.012) and 60° (4±3%; p=.039) knee flexion, which was small, but statistically significant. (figure 4.14)

The MCL and the PMC contributed 15±4% and 15±13% respectively to restraining tibial internal rotation at 30° flexion, which were not found to be significant with the small number tested (N=4) (figure 4.13, Table 4.3). However, the MCL had a significant (p=.037) role in restraining external tibial rotation, resulting in a 62±11% contribution at 30° knee flexion (N=4).

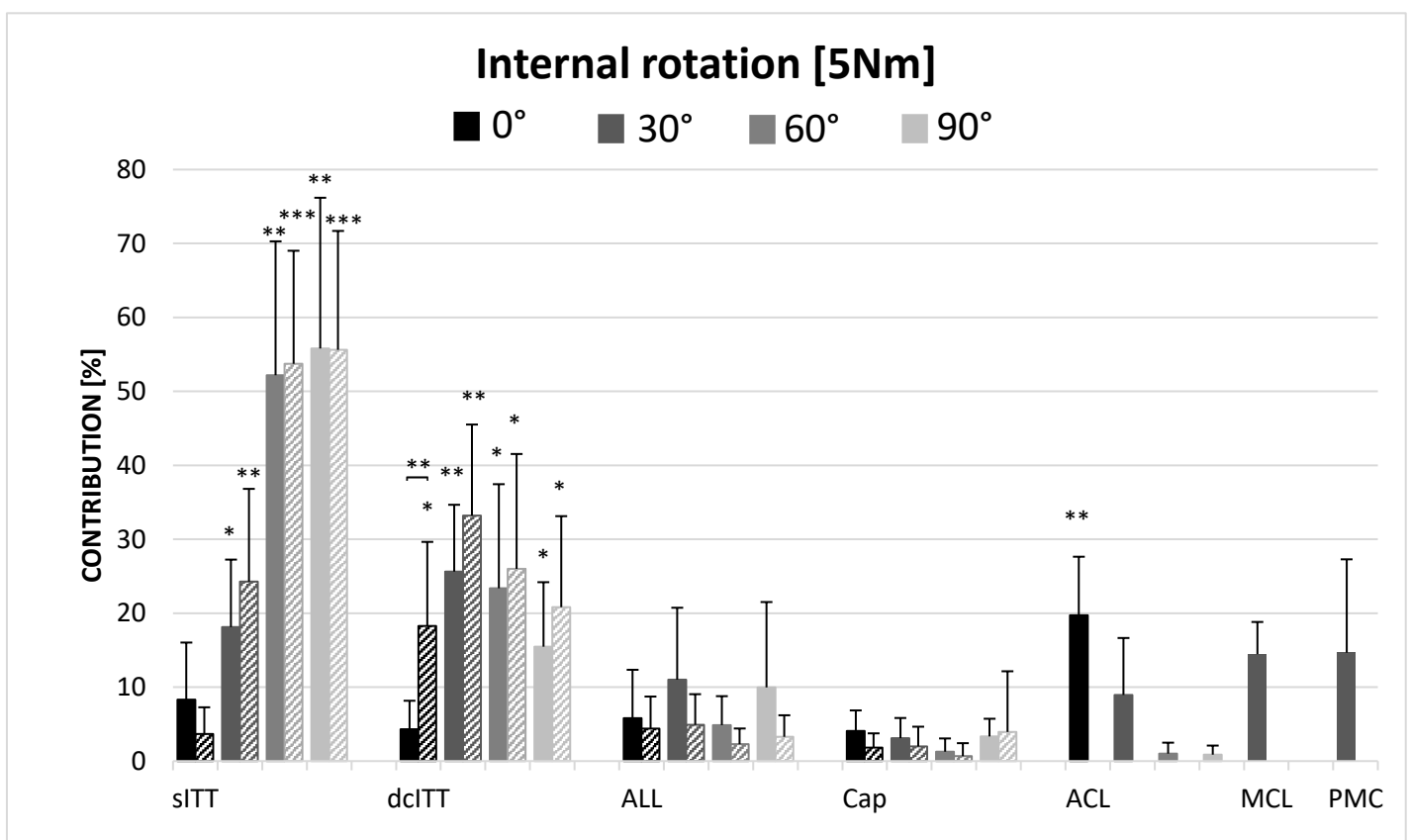


Figure 4.13 Contribution [%] of tested structures in restraining a 5Nm internal rotation torque at 0°, 30°, 60°, and 90°. The medial collateral ligament (MCL) and the posterior medial corner (PMC) were only tested on four knees and at 30° knee flexion. Cross-hatched areas indicate results from the anterior cruciate ligament deficient group. sITT=superficial layer of the iliotibial tract; dcITT= deep and capsulo-osseus layer of the iliotibial tract; ALL= anterolateral ligament; Cap= anterolateral capsule; ACL= anterior cruciate ligament. Asterisks note significant differences to the previous cut, whereas asterisks with brackets note significant differences to the ACL deficient state of the knee. Statistical significance: *p<.05; **p<.01; *** p<.001. (Shown as mean + SD, n=8, apart from MCL and PMC when n=4)

Table 4.3. Contribution [%] of each structure restraining a 5Nm internal rotation torque (for abbreviations see Table 4.1)

Cuts	0°		30°		60°		90°	
	Intact	Def.	Intact	Def.	Intact	Def.	Intact	Def.
sITT	8.3±7.7	3.7±3.6	18.1±9.1	24.3±12.5	52.2±18.1	53.7±15.3	55.8±20.4	55.6±16.1
dcITT	4.3±3.9	18.3±11.4	25.6±9	33.2±12.3	23.4±14.1	26±15.5	15.5±8.7	20.8±12.3
ALL	5.8±6.5	4.4±4.3	11±9.7	4.9±4.1	4.9±3.9	2.3±2.1	10±11.5	3.3±2.9
Cap	4.1±2.8	1.8±1.9	3.1±2.7	2±2.7	1.3±1.8	0.7±1.8	3.3±2.4	3.9±8.2
ACL	19.7±7.9	-	8.9±7.7	-	1±1.5	-	0.9±0.8	-
MCL	-	-	14.5±4.4	-	-	-	-	-
PMC	-	-	14.7±12.6	-	-	-	-	-

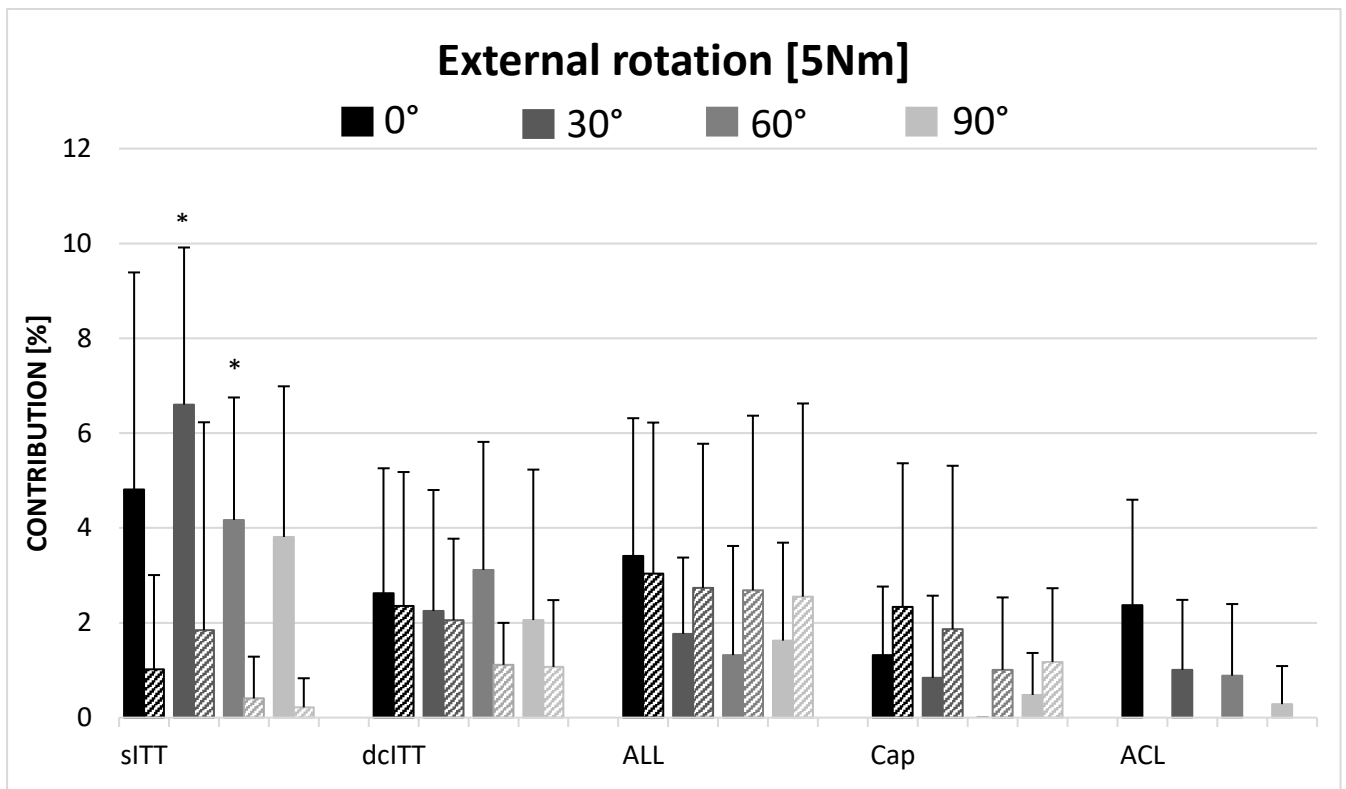


Figure 4.14 Contribution [%] of tested structures in restraining a 5Nm external rotation torque at 0°, 30°, 60°, and 90°. Cross-hatched areas indicate results from the anterior cruciate ligament deficient group. sITT = superficial layer of the iliotibial tract; dcITT= deep and capsulo-osseus layer of the iliotibial tract; ALL= anterolateral ligament; Cap= anterolateral capsule; ACL= anterior cruciate ligament. The ACL and the anterolateral structures had no contribution in restraining external rotation, except the sITT at 30° and 60° compared to the previous cut (asterisks). Statistical significance: *p<.05.

Table 4.4. Contribution [%] of each structure restraining a 5Nm external rotation torque (for abbreviations see Table 4.1)

Cuts	0°		30°		60°		90°	
	Intact	Def.	Intact	Def.	Intact	Def.	Intact	Def.
slTT	4.8±4.6	1.0±2.0	6.6±3.3	1.8±4.4	4.2±2.6	0.4±0.9	3.8±3.2	0.2±0.6
dclTT	2.6±2.6	2.4±2.8	2.2±2.6	2.1±1.7	3.1±2.7	1.1±1.7	2.1±3.2	1.1±0.9
ALL	3.4±2.9	1.8±1.6	1.8±1.6	2.7±3.0	1.3±2.3	2.7±3.7	1.6±2.1	2.6±4.1
Cap	1.3±1.4	2.3±3.0	0.8±1.7	1.9±3.4	0±0	1.0±1.5	0.5±0.9	1.2±1.6
ACL	2.4±2.2	-	1.0±1.5	-	0.9±1.5	-	0.3±0.8	-

ACL-Deficient group:

The dclTT contributed the only significant ($p=.027$) restraint to a 5Nm internal rotation torque at full extension, which was also significantly larger ($p<.01$) than in the intact group. (figure 4.13 Table 4.3) Both the slTT and the dclTT made significant contributions to restraining a 5Nm internal rotation torque at 30°, 60°, and 90°: $p<.01$, $p<.001$, and $p<.001$, respectively for the slTT and $p<.01$, $p=.021$, $p=.02$, respectively for the dclTT. Thus, the whole ITT (slTT+ dclTT) contributed a total internal rotation restraint of $58\pm10\%$ at 30°, $80\pm13\%$ at 60°, and $76\pm14\%$ at 90° knee flexion for the ACL deficient knee. Conversely, all the other anterolateral structures (ALL and the anterolateral capsule) made only a small contribution to restraining a 5Nm internal rotation torque, which was not found to be significant and did not differ significantly from their contribution with the ACL intact. None of the tested structures in the ACL-deficient knee had a significant role in restraining tibial external rotation.

4.4.3 Simulated pivot-shift test:

Cutting structures caused a significant increase in sPS laxity in both the ACL intact ($p<.001$) and ACL deficient groups ($p<.001$) across the range of motion tested. There was also a significant interaction with flexion angle for both groups ($p<.001$), that is: the percent contributions varied as the knee flexed. Cutting the slTT and dclTT had a greater effect in 30° and 45°, than in 15°.

ACL-Intact group:

The dcITT significantly restrained a 4Nm internal rotation torque under a combined valgus torque at all tested flexion angles: ($p < .01$ at 15° , 30° and 45° knee flexion (figure 4.15, Table 3). The slTT had a significant role ($p < .01$) in restraining the rotational component of the simulated pivot shift only at 45° ($37 \pm 14\%$) of knee flexion. The ALL, ACL and the anterolateral capsule made only small contributions to restraining internal tibial rotation under the simulated pivot shift at all tested flexion angles (n.s.).

ACL-Deficient group:

Similarly to the ACL-intact group, the slTT at 45° ($p = .015$), and the dcITT at 15° ($p < .01$), 30° ($p < .01$), and 45° ($p = .048$) made a significant contribution to restraining a 4Nm internal rotational torque under a combined 8Nm valgus torque in an ACL-deficient knee. (figure 4.15, Table 4.4) Although the contribution of the ALL at 15° ($7 \pm 4\%$) was lower than in the ACL-intact group, it made a significant contribution ($p = .049$) to restraining the simulated pivot-shift test.

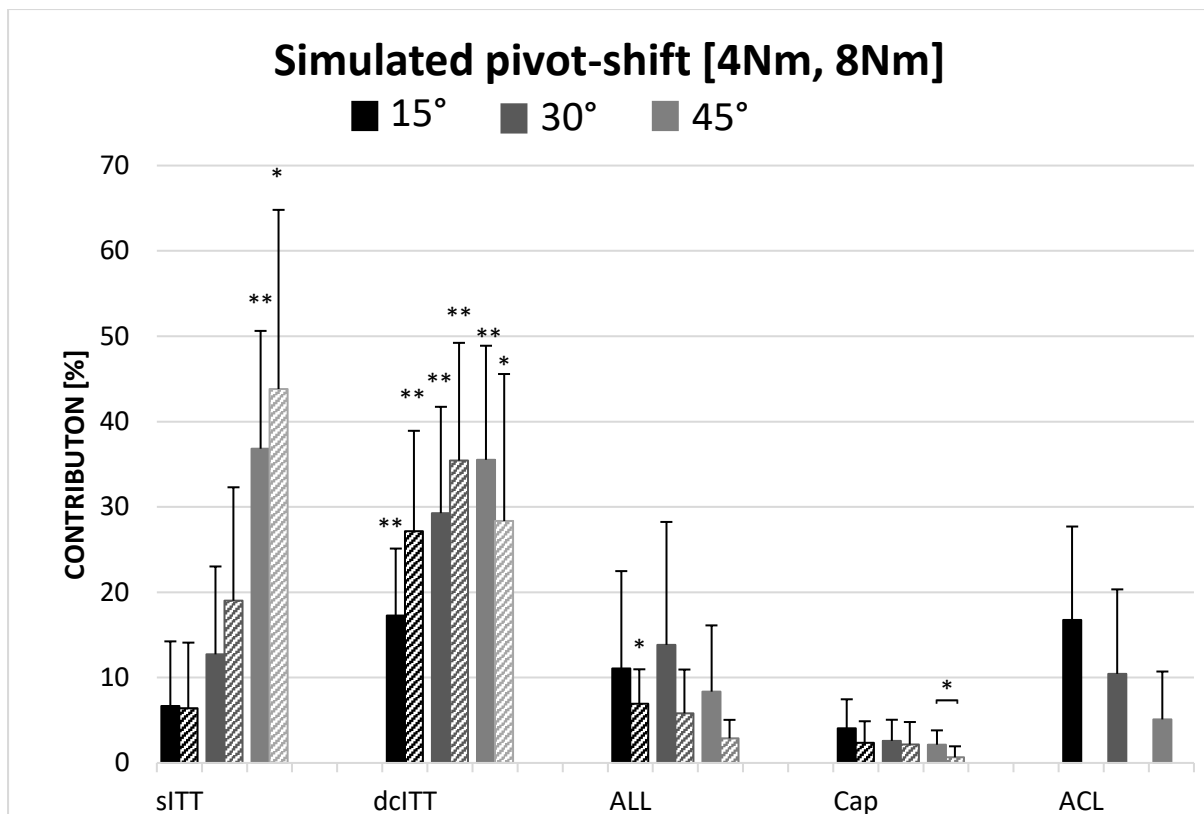


Figure 4.15 Contribution [%] of tested structures in restraining a 4Nm internal rotation torque in response to a simulated pivot shift test (4Nm internal rotation and 8Nm valgus rotation) at 15°, 30°, and 45°. Cross-hatched areas indicate results from anterior cruciate ligament deficient group. sITT=superficial layer of the iliotibial tract; dcITT= deep and capsulo-osseus layer of the iliotibial tract; ALL= anterolateral ligament; Cap= anterolateral capsule; ACL= anterior cruciate ligament. Asterisks note significant differences to the previous cut, whereas asterisks with brackets note significant differences to the ACL deficient state of the knee. Statistical significance: *p<.05; **p<.01; *** p<.001. (Shown as mean + SD, n=8)

Table 4.5. Contribution [%] of each structure restraining a 4Nm internal rotation torque in response to a simulated pivot shift test (8Nm valgus torque) (for abbreviations see Table 4.1)

Cuts	15°		30°		45°	
	Intact	Def.	Intact	Def.	Intact	Def.
sITT	6.7±7.6	6.4±7.7	12.7±10.3	19±13.3	36.8±13.8	43.8±21
dcITT	17.3±7.8	27.2±13.3	29.3±12.5	35.4±13.8	35.5±13.4	28.4±17.2
ALL	11.1±11.4	6.9±4	13.8±14.4	5.8±5.1	8.4±7.8	2.9±2.2
Cap	4.1±3.4	2.3±2.5	2.6±2.5	2.2±2.6	2.1±1.7	0.7±1.3
ACL	16.8±10.9	-	10.4±9.9	-	5.1±5.6	-

4.5 Discussion:

The main finding of this study was that, contrary to the hypothesis and recent speculation based on anatomic observations alone, neither the extracapsular ALL or anterolateral capsular structures offered significant resistance to tibial internal rotation from 0 to 90° knee flexion. At full knee extension, the ACL was a significant restraint in the intact knee; with ACL-deficiency, that role fell onto the deep and capsulo-osseous layer of the ITT. The combined actions of the superficial and deep layers of the ITT were the primary restraint (that is: their combined contribution was greater than 50% of the total) to tibial internal rotation by 30° knee flexion, and this contribution increased with increasing knee flexion, reaching 74% of the total resistance at 60° knee flexion. These findings fit with the observation of Terry et al.¹⁶⁴, that the deep and capsulo-osseous layer of the ITT had been damaged in 93% of functionally unstable knees that were reconstructed, and that this damage correlated significantly with the grade of the pivot-shift, whereas ACL damage did not.

It is widely accepted that the ACL is the primary restraint to anterior tibial translation. This is supported by our results, as the ACL was the only significant restraint in response to a 90N anterior tibial translation force. However, Butler et al.¹⁹ reported that the ACL made a larger contribution than was found in this study: 87% and 85% at 30° and 90° flexion, respectively. This difference may be because the test method used in the earlier study did not allow free tibial rotation, and so the ITT could not come into play as coupled tibial internal rotation was blocked.

There are inconsistencies across studies regarding the role of the ACL in controlling tibial internal rotation. Some authors found no statistically significant increase of internal tibial rotation after cutting the ACL.^{32,94} Similarly to the present study, other authors showed that ACL-deficiency allowed a small but statistically significant increase in internal rotation^{106,115,175} and internal rotation in response to a simulated pivot-shift test at low flexion angles.^{83,179} The present study showed a significant contribution of the ACL in controlling internal rotation only at full extension. In accordance with Oh et al.¹³⁰, who found a 13% decrease in dynamic internal rotational resistance in a

simulated pivot landing at 15° knee flexion after cutting the ACL, we found a 17% decrease in response to a simulated pivot-shift test at 15° knee flexion and an almost 20% decrease of an isolated internal rotation moment at full extension. This also corresponds with Zantop et al.¹⁷⁸, who found that the posterolateral bundle of the ACL played an important role in controlling internal rotation at low flexion angles. Loss of this constraint, which induces the ‘screw-home’, may allow anterior translation of the lateral tibial plateau in early knee flexion.^{8,20}

This study found that the anterolateral structures, particularly the superficial and deep layers of the ITT, were the primary restraint to tibial internal rotation between 30°-90° knee flexion and 30°- 45° for the simulated pivot-shift. Contrary to recent speculation, the ALL and related capsular structures together (so as to encompass the variety of recent anatomical interpretations of ‘the ALL’) were found to be a minor restraint. Sequential cutting studies investigating changes of joint laxity in internal tibial rotation and the simulated pivot shift have been carried out by several authors. Wroble et al.¹⁷⁵ found a significant increase in internal rotation after sectioning the entire anterolateral structures at 30° and above. Yamamoto et al.¹⁷⁶, and Hassler and Jakob⁶⁴ found such a large increase in internal rotation after cutting the ITT that the reduction of the lateral tibial plateau in a pivot shift test disappeared. Suero et al.¹⁵⁹ measured a significant increase in lateral compartment translation after cutting the ITT, but concluded that it did not have more effect than other lateral structures. Looking at the current study’s results, and the larger lever arms about the axis of tibial internal rotation of the peripheral structures, it appears logical that the anterolateral structures control internal rotational laxity better than the central ACL. However, although the studies described above presented data about changes of laxity – which are used for clinical diagnosis – that is not the same as knowing how much each structure contributes to restraining the laxity; that is: which are the primary and secondary restraints? There has been one study published which addressed this question¹³², but unfortunately they removed the superficial ITT prior to the experiment, which the present work has shown to be a primary restraint. In this state, the remaining structures will appear to be more important than they actually are in the intact knee. Also, the

kinematics of the knee will have been abnormal, with further consequences for the validity of the data. Furthermore, tissues deep to the superficial ITT were preserved, and so data presented for “the ALL” may have been a combination of the deep layer of the ITT, plus the extracapsular ALL, plus the capsular structures, all of which have been shown in the present study to have distinct contributions. Thus, their conclusion that the ALL is a primary restraint to tibial internal rotation at high flexion angles may be questioned, and that was not found to be the case in the present study.

In the absence of the ACL, its restraining action fell onto the remaining intact structures, so the contributions of the superficial and deep layers of the ITT to restraining internal rotation and the simulated pivot-shift test were enhanced for the ACL deficient knees at almost every flexion angle. However this increase was only significant (4% to 18%) for the capsulo-osseus layer at 0°, which was where the ACL had made its largest contribution to controlling tibial rotation. These results suggest that the load on the ITT, and especially on the deep capsulo-osseus layer, will increase after ACL rupture. This is in accordance with previous data showing that simultaneous intra-articular ACL and extra-articular lateral reconstructions share the load imposed on the knee.⁴¹

The contributions of the MCL and PMC to resisting tibial internal rotation at 30° knee flexion were measured in four knees as an ad-hoc addition to the original test protocol. That was because, after finishing the test series on the anterolateral structures and the ACL, the internal tibial rotation results at early flexion angles left speculations on the remaining 33% contribution at 30° knee flexion. Unfortunately, further investigation of the peripheral structures restraining internal tibial rotation of the knee could only be performed in four knees, because at this time it was not possible to remount the other knees to the robot in the exact same position without altering the kinematics due to residual forces/moments. The MCL and the PMC each contributed 15% of the restraint to internal tibial rotation, implying a greater role than the ALL, the anterolateral capsule, and the ACL at 30° knee flexion. Moreover, the MCL showed a 60% contribution to restraining external rotation at 30°, which implies a substantial role in restraining external tibial rotation, as suggested by previous

work.¹⁴⁰ These data were collected from only four knees, so are just an indication and cannot be taken as solid results. However, they suggest that it should be worthwhile to revisit the roles of the medial and posteromedial structures in restraining rotational laxity.

The differences in anatomical descriptions of the anterolateral aspect of the knee are not surprising, considering the complexity and variability of the structures found there. The femoral attachment of the ALL has been described at three different positions and it is not even agreed whether the ALL is a capsular or extracapsular structure^{22,33,67,168}. Different characterizations of the ALL may also have been confused with previously described structures like the capsulo-osseous layer of the ITT¹⁶¹, the midthird lateral capsular ligament⁷¹, the bilaminar structure of the capsule¹⁴⁵, and the aponeurotic extensions of the biceps femoris muscle¹⁶². With regard to function, it is largely immaterial as to whether the ALL is extra-capsular or a capsular ligament. However, for reconstruction of the anterolateral side of the knee, the position of the attachment sites of a graft are important, therefore in our study we examined both intra and extra-capsular restraints.

Contrary to recent speculation, the extracapsular ALL (described by Dodds et al.³³) and the entire anterolateral capsule (which included the ALL described by Claes et al.²², Helito et al.⁶⁷, and Vincent et al.¹⁶⁸) showed only a small contribution in restraining internal tibial rotation or internal tibial rotation in response to a simulated pivot shift test at all flexion angles examined. The capsulo-osseous layer of the ITT, on the contrary, is a more substantial structure which showed high potential in restraining anterior subluxation of the lateral tibial plateau, so it is surprising that damage of the anterolateral capsule and not the ITT has been considered as the cause of ALRI in recent publications. The functional importance of the ITT (especially the deep and capsulo-osseous fibers) is also implied by the high number of proprioceptors which have been found in the distal part of the ITT system.^{43,107} Thus, the deep and capsulo-osseous fibers of the ITT might have been underestimated in their role as potent restraints to ALRI, as evidenced by the biomechanical data on the ITT load-sharing with the ACL from Noyes et al.¹²⁶ and the correlation with pivot-shift instability.^{162,164}

4.6 Limitations:

Although the present study presented an appropriate way of determining the contribution of peripheral structures in restraining knee laxity, it had several limitations to note. The testing concentrated on the contribution of soft tissues in restraining knee laxity in a quasi-static setup that did not include the axial compression loading present during gait, and thus simulated clinical manual examination loading. This setup did not determine the contribution to functional stability of muscle loading; the short knee specimens had no proximal continuity to the tensor fascia lata, for example, and so the role of the ITT found in this work was likely to have been underestimated. Thus, this robotic testing setup could not imitate normal knee kinematics during gait, for example. The contribution of each structure to resisting tibiofemoral displacements was precisely derived from the intact/deficient kinematics of the knee using a repeated displacement-controlled method. A force-controlled method, which allows measurement of the increased joint laxity at a given load that follows the cutting of each structure, may appear to be more relevant for clinical diagnosis, but the results are sequence-dependent and so care must be taken in interpreting the resulting data. For example, if a minor restraint (such as the ALL) is the last structure left intact, then cutting it will allow a large increase in laxity, but that does not mean that it carried a significant load in use. It may be possible that resection of superficial structures – required here for visualization of deeper capsular structures – led to results different to those, which would have resulted from isolated transection or real-world injuries. Even though the residual forces/torques were kept low, remounting the specimen, when testing the medial structures, could have altered the results.

4.7 Conclusion:

This study has measured the contributions of the ACL and anterolateral structures of the knee to resisting tibial internal rotation motion, for both the intact knee and after ACL injury. The data may offer guidance for the treatment of rotational instability of the injured knee. The ITT was found to

be the primary restraint to internal tibial rotation for both the intact and ACL-deficient knee, from 30° to 90° knee flexion. The ITT was also found to be the primary restraint to internal tibial rotation induced by application of a simulated pivot shift test, at 15° to 45° knee flexion. The contributions of the deep and capsulo-osseous fibers of the ITT imply a potent role in restraining anterior subluxation of the lateral tibial plateau. This work did not find a significant restraining role for the ALL. These data suggest that it may be appropriate to identify and possibly to reconstruct additional ITT injuries in case of a suspected ALRI. Clinical research should focus on identifying additional peripheral injuries in MRI and clinical examination studies.

5 Surgical procedures of the anterolateral structures

Minor parts of this chapter have been published in The American Journal of Sports Medicine.

The role of the anterolateral structures and the ACL in controlling laxity of the intact and ACL-deficient knee; The American Journal of Sports Medicine, Volume 44 , Number 2, pages: 345-354
C Kittl, H El-Daou, KK Athwal, CM Gupte, A Weiler, A Williams, AA Amis

For permissions, see Chapter 9 (Appendix)

5.1 Background:

Lateral extra-articular procedures are sometimes used in revision ACL surgery¹⁶⁵ and in primary cases displaying excessive ALRI,^{120,177} following a combined injury of the ACL and the peripheral structures where it is judged that an isolated intra-articular ACL reconstruction may prove to be inadequate to control rotational instability. Such reconstructions typically involve routing a strip of the ITT left attached to Gerdy's tubercle, which is passed deep to the lateral (fibular) collateral ligament (LCL), before being attached to the lateral femur.^{20,101} However, these extra-articular reconstructions have lost popularity, due to a number of perceived and actual drawbacks: excessive constraint of internal tibial rotation,^{37,38,42,118} failure to restore normal AP stability,^{37,38} alteration of kinematics,^{41,42} and unsatisfactory clinical results^{29,52,98,136} even in combination with an intra-articular procedure.^{11,128,141,158} On the contrary, other authors have found reduced internal rotational laxity and good clinical outcomes after extra-articular reconstructions,^{14,120} both at follow up^{102,114,125,144,166} and at the time of revision surgery.¹⁶⁵ Historically, lateral extra-articular procedures were often performed in isolation, without simultaneous intra-articular ACL reconstruction, thereby leaving a major ligamentous restraint un-addressed. In addition, long periods of post-operative immobilisation in plaster, non-isometric graft placement and excessive graft tensioning may have contributed to the poor results.³⁴ Recent clinical and biomechanical studies⁷³⁻⁷⁵ have addressed these issues and showed promising results,^{25,120,144,165} when comparing a combined intra-articular and extra-articular procedure to an isolated Single Bundle or Double Bundle ACL reconstruction.

The purpose of this chapter was to evaluate the existing literature on the biomechanics and surgical reconstruction techniques for lateral extra-articular reconstruction of the knee.

5.2 Aims:

The aim of chapter five is to give an overview of the available and most commonly used extraarticular tenodeses and reconstructions of the anterolateral side of the knee and evaluate their biomechanics, advantages and limitations.

5.3 Biomechanics of the lateral extra-articular reconstruction

The biomechanical principle of most lateral extra-articular techniques is that the rerouting of the ITT deep to the LCL provides a lateral 'check-rein' against anterior subluxation of the lateral tibial plateau, by positioning the graft posterior to the transverse axis of rotation throughout the entire range of motion.²⁰ The effect of this was shown in an early experiment by Hassler and Jakob who used a K wire, placed anterior to the ITT, to maintain the ITT posterior to the axis of rotation, causing a reduction in anterior translation of the tibial plateau.⁶⁴ (figure 5.1)

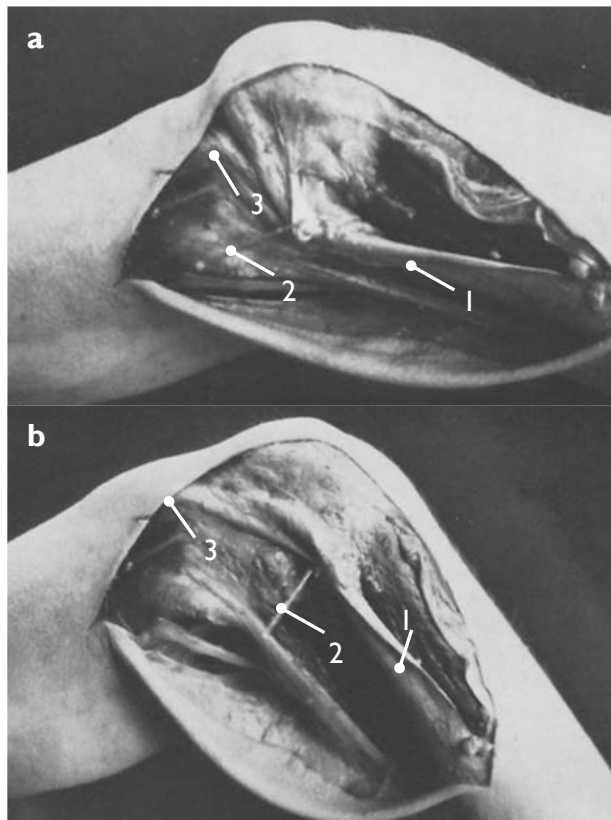


Figure 5.1 Left knee lateral side (a): When a K-wire (2) was inserted anterior to the Kaplan fibres, the iliotibial tract (ITT; 1) reduced the lateral tibia condyle (3), as it provided a posterior pull throughout the range of motion. (b): When inserting a K-wire posterior to the Kaplan fibres the posterior pull was decreased and therefore the ITT (1) could not reduce the subluxation of the lateral tibial condyle (3), even at 90° flexion. Reproduced with permission and adapted from Hassler and Jakob⁶⁴ (1981)

Furthermore, it has been shown that an additional extraarticular lateral soft-tissue reconstruction provides a back-up for the intraarticular ACL graft by reducing the graft force by an average of 43%.⁴¹ However, Amis and Scammell⁴ showed in a biomechanical experiment using the Instron machine that in knees with isolated ACL deficiency, an additional extra-articular reconstruction did not provide better stability compared to an isolated intra-articular ACL reconstruction (figure 5.2). This apparent dichotomy may result from the position of the tibia when the extra-articular tenodesis was fixed. While Amis and Scammell fixed their tenodesis with the tibia in neutral tibial rotation, Engebretsen et al.⁴¹ fixed it with tibial external rotation applied, thereby reducing the load on the ACL.

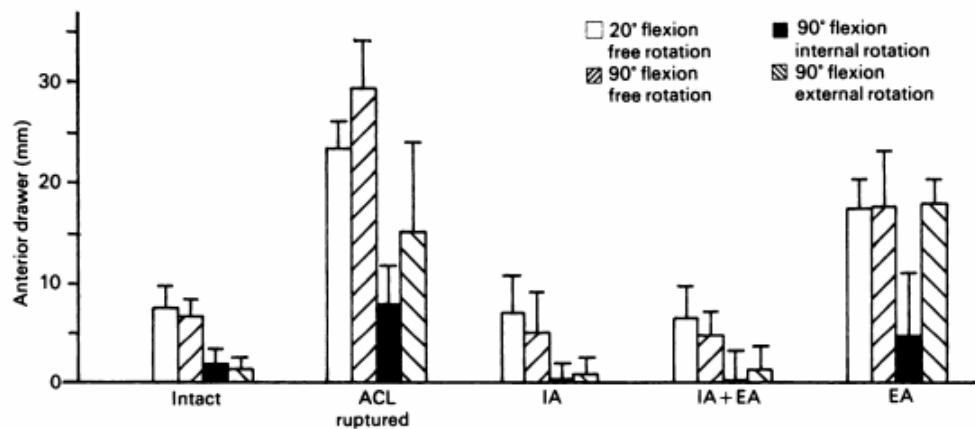


Figure 5.2 An additional extra-articular reconstruction did not add any stability compared to an isolated intra-articular reconstruction in case of an isolated anterior cruciate ligament rupture. An isolated extra-articular reconstruction improved stability compared to the ruptured state, but did not restore it to normal. Reproduced with permission from Amis and Scammell⁴ (1993)

Additionally, whilst prior studies looked at isolated ACL ruptures, Inderhaug et al.⁷⁵ showed in an in-vitro study, that an isolated ACL reconstruction was not able to restore intact knee kinematics in a combined ACL and anterolateral deficient knee. However, after an additional extra-articular reconstruction routed deep to the LCL (Lemaire or MacIntosh) with 20N tensioning the intact knee kinematics were restored to normal. Both an extra-articular reconstruction superficial to the LCL and the ALL reconstruction failed to restore native knee kinematics. (figure 5.3)

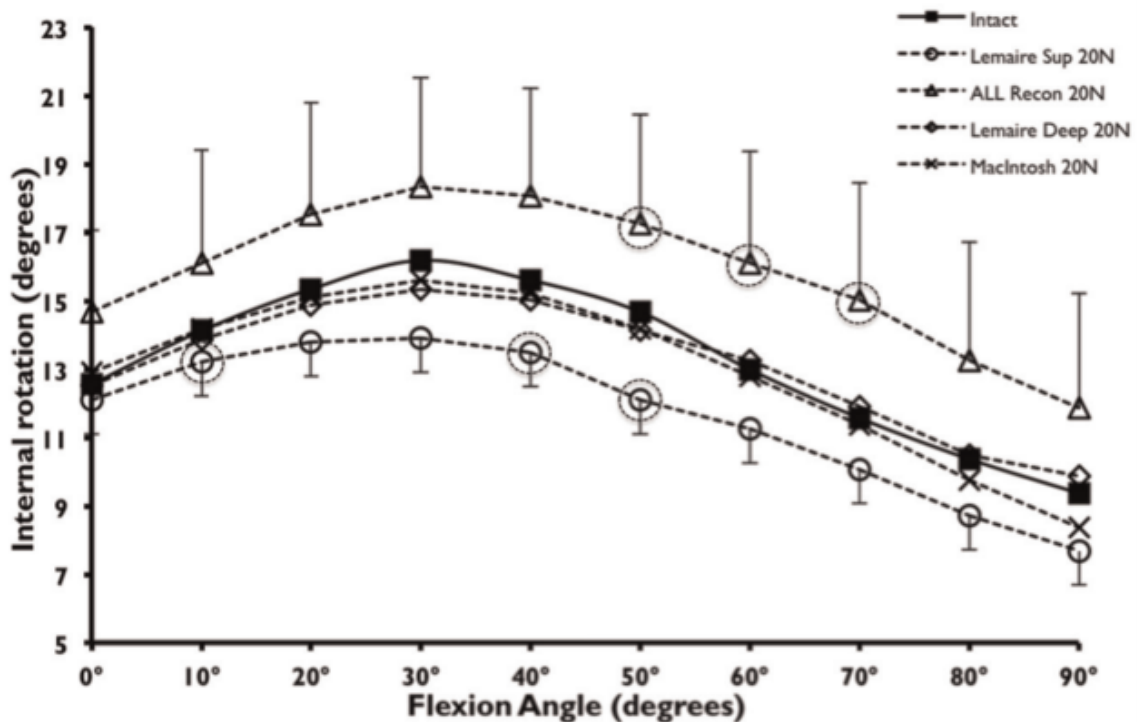


Figure 5.3 An additional Lemaire or MacIntosh reconstruction, which was passed deep to the lateral collateral ligament, restored internal rotation laxity to normal. The anterolateral ligament (ALL Recon) reconstruction presented persistent internal rotation instability at certain flexion angles, whereas the superficial Lemaire (Lemaire Sup) over-constrained this. Statistical significance is indicated by circles. Reproduced with permission from Inderhaug et al.⁷⁵ (2017)

Another study⁷⁵ with the same testing setup, however, showed that an ALL reconstruction tensioned and fixated at full knee extension was able to restore intact knee kinematics, whereas the Lemaire reconstruction was more forgiving and could be tensioned at 0-60° knee flexion angle to produce the same effect. An ALL reconstruction (routed superficial to the LCL), however, fixed at 30° or 60° knee flexion did not control internal rotation sufficiently.

Concerns have been raised as to whether lateral extra-articular procedures may over-constrain the lateral compartment⁷⁰, leading to increased tibiofemoral contact pressure and ultimately osteoarthritis. Inderhaug et al.⁷³ showed in a biomechanical experiment that a MacIntosh tenodesis did not increase tibiofemoral lateral contact pressure when tensioned with 20 N. However, tensioning the MacIntosh graft to 80 N increased lateral compartment contact pressure and resulted in abnormal external rotation compared to the intact state of the knee, especially when the tibia was

free to rotate. Thus, the tibia should be held in neutral rotation when fixating the graft on the femur. Also tensioning the graft in higher knee flexion would imply an increasing posterior force vector, inducing external rotation of the tibia.

5.4 Lateral extra-articular procedures

5.4.1 MacIntosh tenodesis.

The MacIntosh lateral extra-articular tenodesis was the most popular and most used procedure for treatment of ACL injury in the UK.⁵¹ A 20 cm long strip of the middle part of the ITT is taken and left attached at Gerdy`s tubercle. It is then passed deep to the LCL and a periosteal flap (figure 5.4) is created posterior and proximal to the lateral femoral epicondyle. Then the strip is passed through this periosteal flap and the distal termination of the lateral intermuscular septum and looped back onto itself. Newer versions of this tenodesis used suture anchors or staples to fixate the graft proximal to the lateral epicondyle in between the area of the transition between the femoral shaft and the metaphysis.

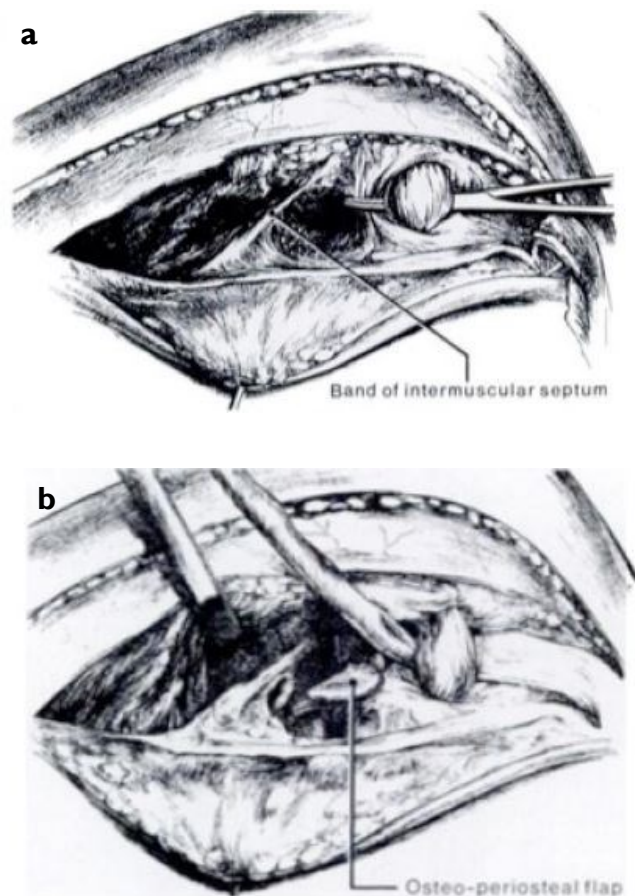


Figure 5.4 A strip of the iliotibial tract, left attached at Gerdy`s tubercle (a) is shuttled deep to the lateral collateral ligament (b) and rerouted on itself after perforating the lateral intermuscular septum through a periosteal tunnel. Reproduced with permission from Ireland and Trickey⁷⁶ (1980)

5.4.2 Lemaire tenodesis

The original description of the Lemaire technique was published in 1967 in French.¹⁰⁰ Similarly to the other lateral extra-articular tenodesis this was used to restrain the anterior subluxation of the lateral tibial plateau as a stand-alone procedure, because arthroscopy was not popular at that time. A 10 mm wide strip of the ITT is left attached at Gerdy`s tubercle, transected proximally and whipstitched. (figure 5.5) The strip is then passed deep to the LCL and through a bony tunnel, which is created between the lateral epicondyle and the gastrocnemius insertion as an entry and 10 mm

anterior as the exit. The graft is then passed again deep to the LCL from proximal and finally stitched on itself.

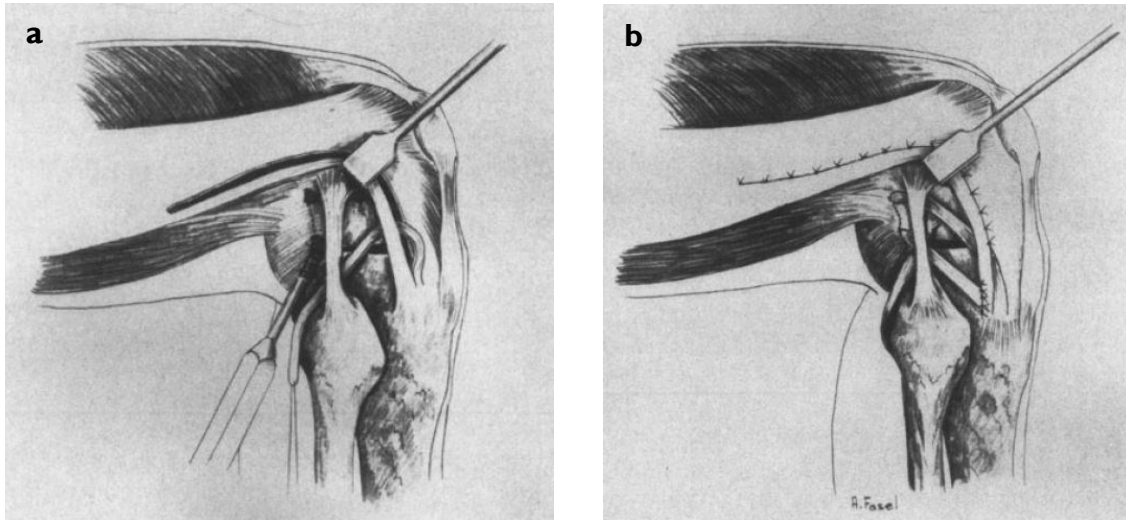


Figure 5.5 Similarly to the MacIntosh tenodesis the iliotibial tract graft is routed deep to the lateral collateral ligament. It is then passed (a) through a semi-circular tunnel, which enters the lateral femoral condyle between the lateral epicondyle and the gastrocnemius tubercle (posterior and proximal to the lateral femoral epicondyle) and exits anteriorly. The graft is then again shuttled deep to the LCL and sutured onto itself (b). Reproduced with permission from Fritschy and Freuler⁴⁹

In 1994 Neyret et al.¹²³ reported retrospectively on 31 amateur skiers with chronic ACL instability, who were treated with an isolated Lemaire extra-articular lateral tenodesis. The poor outcome and persistent pivot-shift phenomenon led them to conclude that an extra-articular tenodesis was not a suitable option for ACL insufficiency.

Newer version of this extra-articular lateral reconstruction utilize interference screw, staple, or anchor fixation proximally and posteriorly to the lateral epicondyle and are mainly used in combination with an intra-articular ACL reconstruction.¹⁶⁹ (figures 5.6 – 5.11)

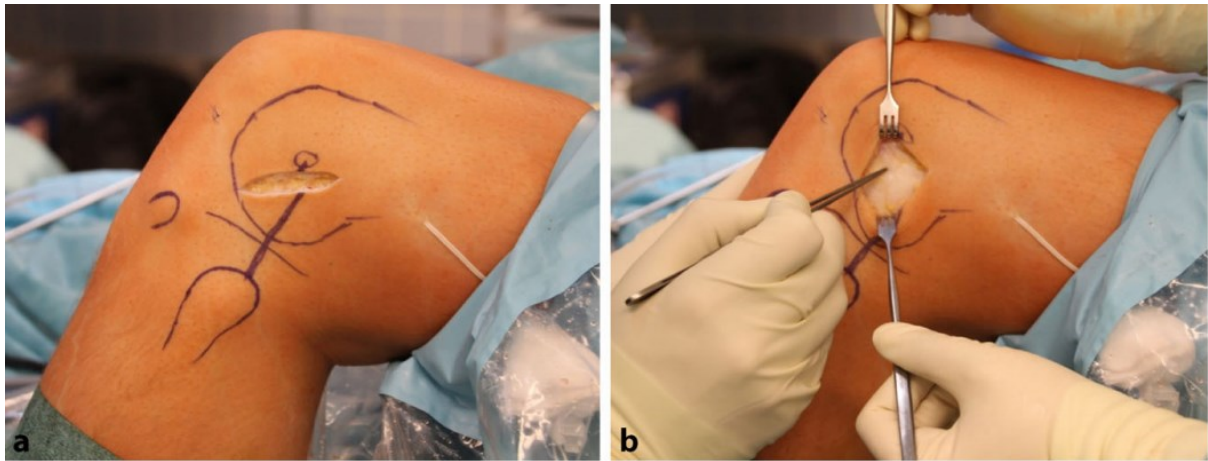


Figure 5.6 The skin incision starts 10 mm proximal to the lateral epicondyle and is expanded towards Gerdy's tubercle (a). The iliotibial tract is then prepared and the lateral epicondyle can be palpated (forceps; b). Reproduced with permission from Wagner et al.¹⁷⁰ (2014)

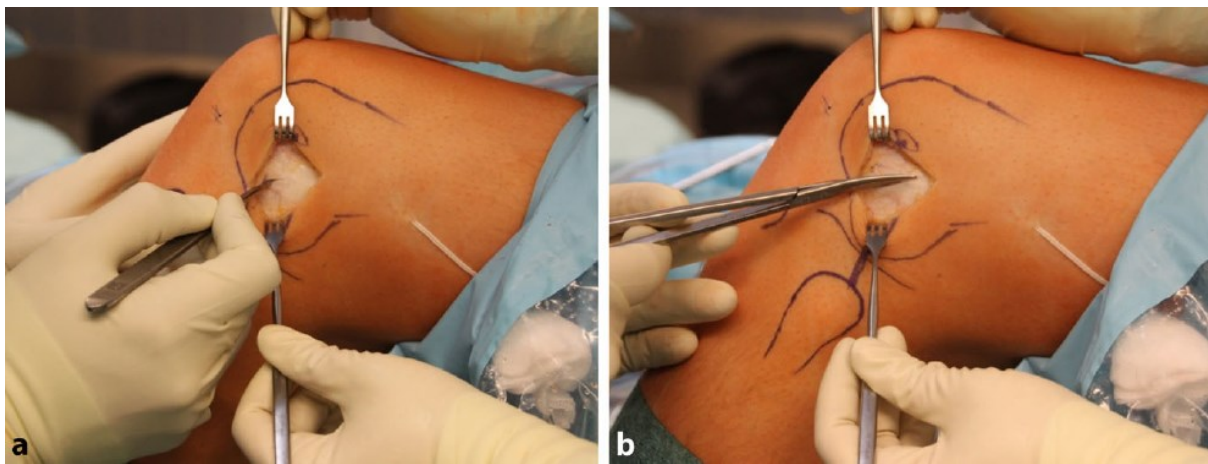


Figure 5.7 The iliotibial tract is incised on the anterior border of Gerdy's tubercle using a scalpel (a). The incision is further expanded approximately 30 mm proximally to the lateral epicondyle using scissors in order to not damage the lateral collateral ligament (b). Reproduced with permission from Wagner et al.¹⁷⁰ (2014)

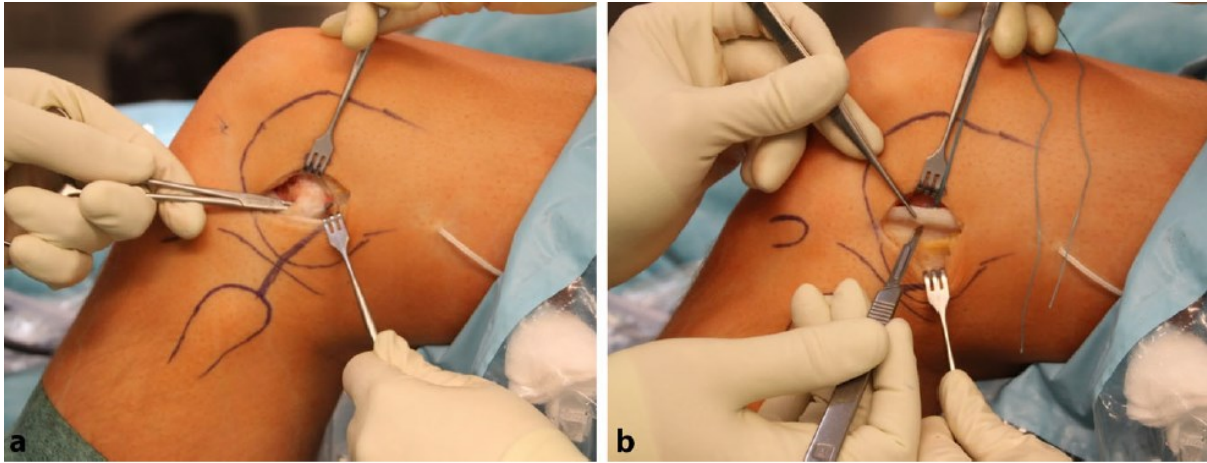


Figure 5.8 The lateral collateral ligament is then dissected and an Overholt-forceps (a) is passed deep to the lateral collateral ligament (LCL). A shuttle suture is passed deep to the LCL to later shuttle the graft proximally deep to the LCL. A 10 mm wide strip of the iliotibial tract, which is still attached to Gerdy's tubercle is then dissected proximally (b). Reproduced with permission from Wagner et al.¹⁷⁰ (2014)

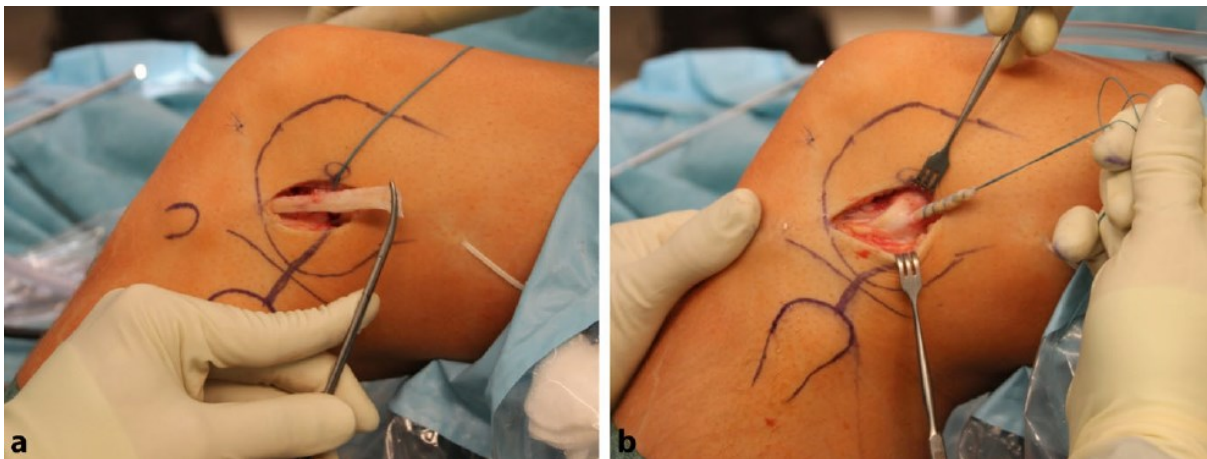


Figure 5.9 The strip of the iliotibial tract is then cut proximally, approximately 30 mm proximal to the lateral epicondyle. (a) It is then whipstitched and shuttled deep to the lateral collateral ligament using the shuttle suture (b). Reproduced with permission from Wagner et al.¹⁷⁰ (2014)

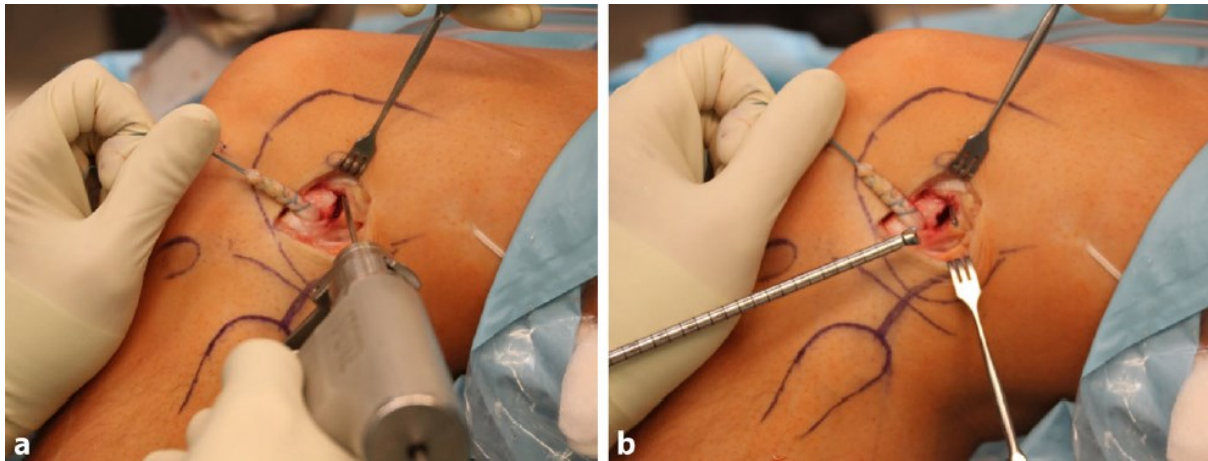


Figure 5.10 A K-wire is then drilled approximately 2 mm proximal and posterior to the tip of the lateral epicondyle (a). This is then overdrilled using a 6 or 7 mm thick drill, depending on the graft size (b). Reproduced with permission from Wagner et al.¹⁷⁰ (2014)

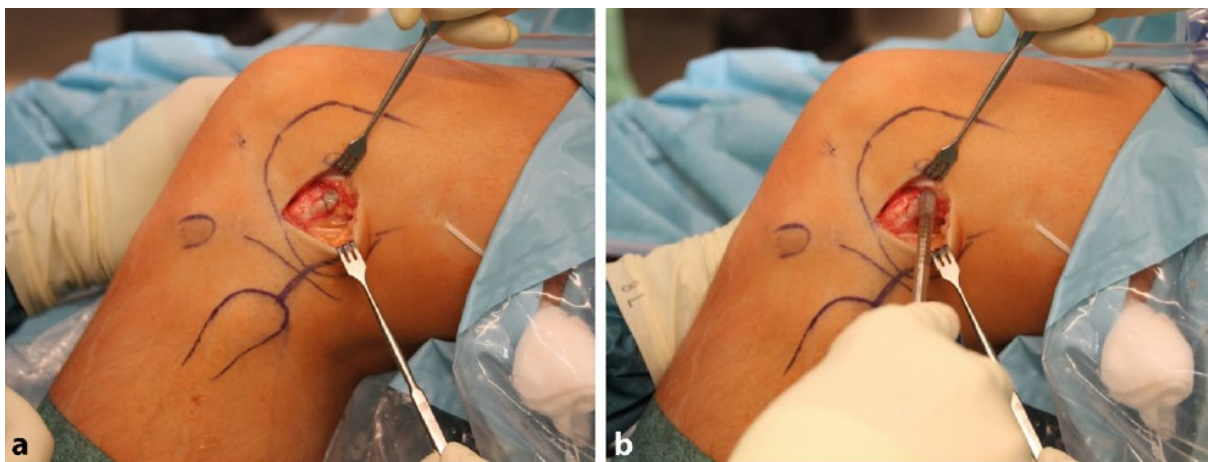


Figure 5.11 The graft is then shuttled into the tunnel using a shuttle suture (a). An interference screw according to the size of the graft is used to fix it into the tunnel (b). Reproduced with permission from Wagner et al.¹⁷⁰ (2014)

5.4.3 The Losee sling and reef operation

Losee et al. published the results of a lateral reconstruction procedure (Fig. 5.12) in 50 of a cohort of 84 patients with anterior subluxation of the lateral tibial condyle, most likely to have been the result of ACL injury.¹¹⁰ The results were good in 41, fair in six, and poor in 3 patients. All of them stated that they would have the operation again.

Similarly to the other lateral extra-articular lateral procedures, this technique was used without an intra-articular ACL reconstruction. A 25 mm wide and 160 mm long strip of the ITT is taken and dissected off the vastus lateralis. Then a tunnel is made just anterior and distal to the lateral epicondyle, (figure 5.12) directed towards the insertion of the lateral gastrocnemius tendon, which is posterior and proximal to the lateral femoral epicondyle. The authors describe that they used home-made carriers made out of beer-can openers in order to pass the strip through this tunnel. As a next step, the strip is twisted twice around the gastrocnemius tendon and diverted distally deep to the LCL. (figure 5.13) The remaining strip is then sutured back to Gerdy`s tubercle. Aftercare treatment involved a full-leg plaster cast in 30-45° of knee flexion and external tibial rotation for seven weeks.

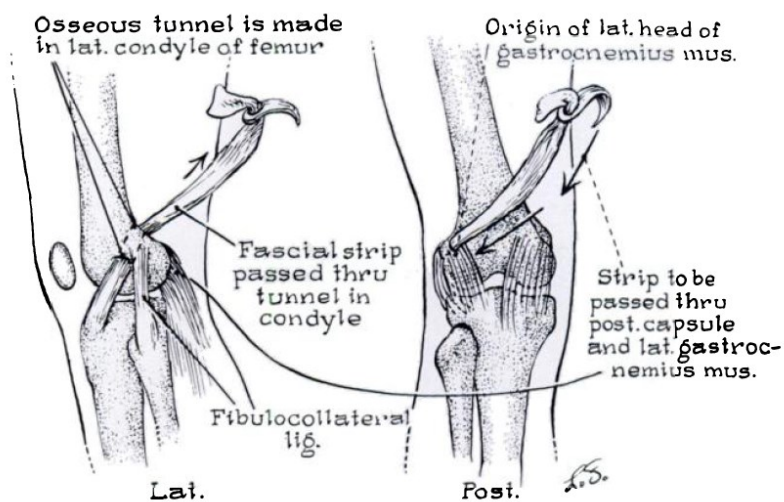


Figure 5.12 The strip of the iliotibial tract is passed through a tunnel from anterior/distal to proximal/posterior on the lateral femoral condyle. Reproduced with permission from Losee et al.¹¹⁰ (1978)

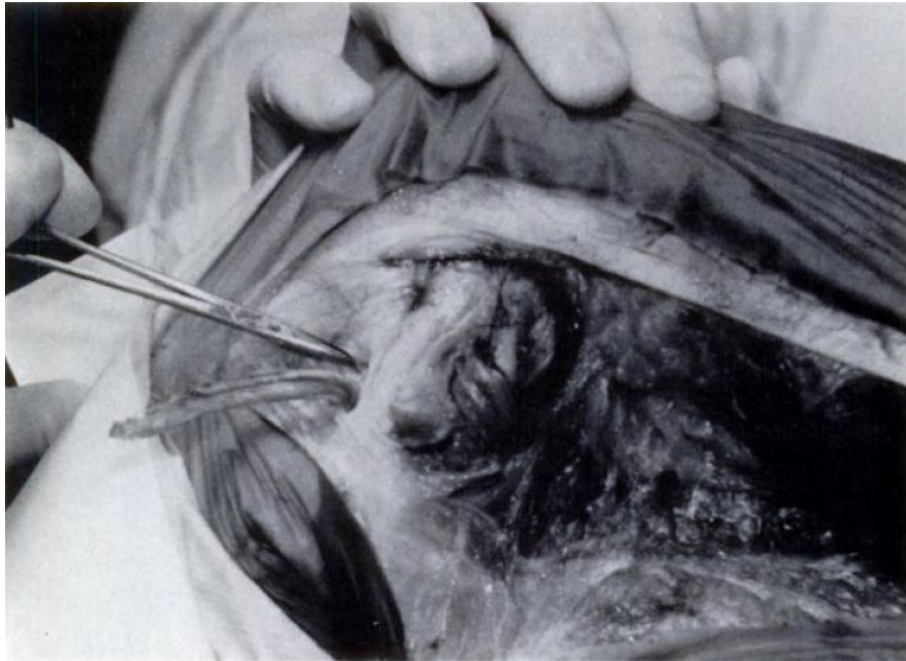


Figure 5.13 The iliotibial strip is then passed deep to the gastrocnemius tendon and deep to the posterolateral structures for the second reefing. Reproduced with permission from Losee et al.¹¹⁰ (1978)

5.4.4 Ellison procedure

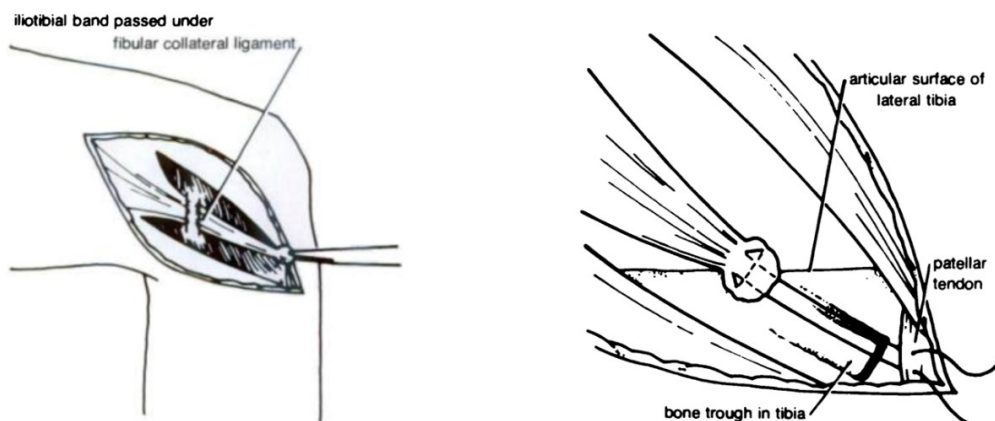


Figure 5.14 A strip of the iliotibial tract with a distal bone plug is rerouted deep to the lateral collateral ligament and then fixed to the bone trough at Gerdy's tubercle using a staple. Reproduced with permission from Ellison³⁹ (1979)

The Ellison technique was introduced in 1978 and was the first procedure, which did not leave the ITT attached at Gerdy's tubercle.⁸⁵ Instead a piece of bone was chiselled from Gerdy's tubercle and

a 15 mm strip of the ITT was then dissected proximally. (figure 5.14) The strip was then rerouted beneath the LCL and fixed back to the bone trough using a staple.

The initial study evaluated 18 patients, on which this technique was performed for chronic recurrent anterolateral instability of the knee. Five to six years postoperatively they rated eight knees excellent, seven good, and three failures. The authors concluded that these results were encouraging and almost all patients returned to sports. Thirteen years later Reid et al.¹³⁶ reported on long-term results seven to fifteen years postoperatively. After their encouraging initial results, they were disappointed by the persistent pain and the high rate (44%) of revision surgery at longer term follow-up.

5.4.5 The Rowe-Zarins technique

This technique was first described in 1986.¹⁸⁰ It involves both intra-articular and extra-articular grafts to restrain the anterior subluxation of the lateral tibial plateau. (figure 5.15) The intra-articular part uses the semitendinosus tendon, which is passed intra-articularly through the tibial tunnel and then routed through the over-the-top position of the lateral femoral condyle. A strip of the ITT (20 mm wide and 250 mm long) is passed from extra-articular to intra-articular - the other way round. Both grafts are then tightened and sutured on each other.

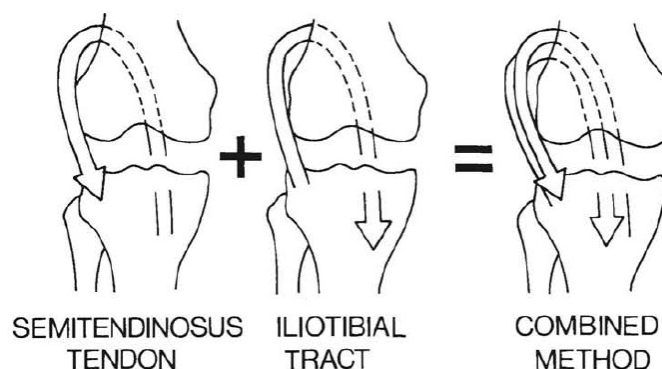


Figure 5.15 The semitendinosus tendon and a strip of the iliotibial tract are rerouted through a tunnel on the anteromedial tibia via the over-the-top position of the lateral femoral condyle, and deep to the lateral collateral ligament and vice versa. Reproduced with permission from Zarins and Rowe¹⁸⁰ (1986)

Between 1977 and 1985 this surgical procedure was used on 317 patients presenting with a chronic ACL instability. Ninety percent of the patients were able to achieve functional stability 3-7.5 years postoperatively.

5.4.6 Anterolateral ligament reconstruction

This modern technique of a combined intra-, and extra-articular reconstruction was first described by Sonnery-Cottet in 2015.¹⁵² (figure 5.16) A combined graft for the two procedures is used, utilising a tripled semitendinosus graft and a single gracilis strand for the intraarticular portion with the remaining gracilis strand used for the extra-articular portion. The femoral ACL tunnel is drilled outside-in, in order to create a tunnel exit proximal and posterior to the lateral femoral epicondyle. The ACL is then fixed using an interference screw and the remaining gracilis portion is routed superficial to the LCL and deep to the ITT towards the anterolateral tibia. On the tibia the graft is passed through a tunnel, whose entry is located at the area of the Segond avulsion and the exit is located at Gerdy's tubercle. It is then sutured back on itself. The remaining Gracilis tendon is then cut. The graft is fixed using an interference screw in the proximal tibial tunnel in full knee extension and neutral rotation. The reported results after two years postoperatively showed a very low (1.1%) re-rupture rate, which is much lower than previously published.

ALL reconstruction places the graft superficial to the LCL according to recent anatomical observations of the anterolateral complex (see figure 2.9)⁸⁶, whereas lateral extra-articular tenodeses imitate fibre orientation of the capsulo-osseous layer of the ITT, by passing it deep to the LCL. ALL reconstruction requires an additional hamstring graft, whereas a lateral tenodesis can be performed using a strip of the ITT.

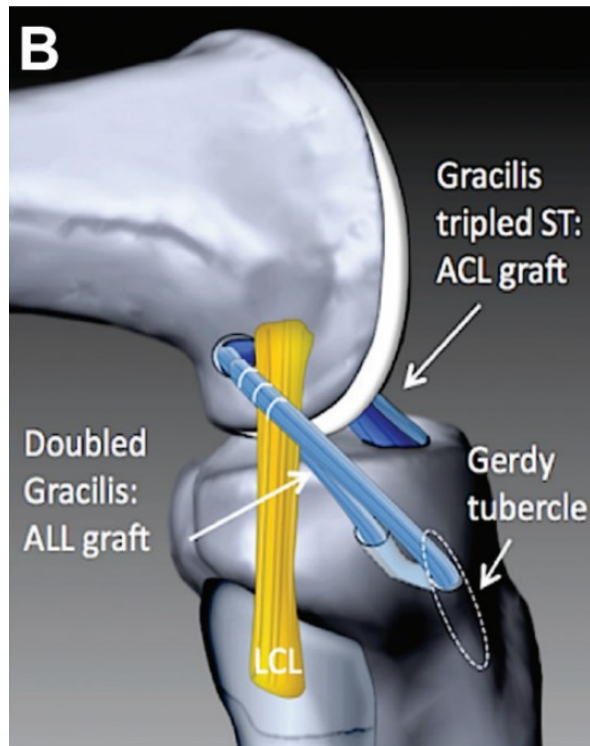


Figure 5.16 A 3fold semitendinosus tendon with a single strand gracilis tendon is taken as the intra-articular anterior cruciate ligament graft. The remaining gracilis tendon graft is used as a triangular lateral extra-articular reconstruction. Reproduced with permission from Sonnery-Cottet et al.¹⁵² (2015)

5.5 Limitations of extra-articular reconstructions

Even though good results were published on extra-articular lateral reconstructions in combination with intraarticular ACL reconstructions¹⁸⁰, these procedures fell from favor after a AOSSM consensus meeting in Snowfall (Colorado). At that time the experts were more concerned with the possible limitation of an additional extra-articular lateral reconstruction than the benefit of adding increased stability. These concerns included over-constraining the lateral compartment and high compression forces, fixed external rotation, and limiting range of motion.⁴⁶ Thus, when performing these lateral tenodeses one should be aware of these limitations. Fixation of the graft with the tibia in neutral rotation, avoiding excessive graft tension and avoiding post-operative immobilisation may all help overcome these limitations.

5.6 Conclusion

Adding an extra-articular lateral procedure to an intra-articular reconstruction is an elegant way to reduce anterolateral subluxation of the tibia. Furthermore, it appears to reduce the re-rupture rate compared to an isolated ACL reconstruction. However, long term studies are missing, and undifferentiated use may cause detrimental effects for the patient.

It would appear that from a biomechanical point of view in terms of normalising tibiofemoral contact pressure and restoration of tibiofemoral knee kinematics a MacIntosh or Lemaire reconstruction routed deep to the LCL and tensioned with 20N in early flexion angles would be preferable. However, concerns regarding different types of over-constraint remain. Thus, further knowledge of extra-articular reconstruction length change patterns, femoral insertion site and graft course would be desirable.

6 Length change pattern of the anterolateral structures and related reconstructions

The majority of this chapter has been published in The American journal of Sports Medicine

Length change patterns in the lateral extra-articular structures of the knee and related reconstructions; The American Journal of Sports Medicine, Volume 43, Number 2, pages: 354-362
C Kittl, C Halewood, JM Stephen, CM Gupte, A Weiler, A Williams, AA Amis

For permissions, see Chapter 9 (Appendix)

6.1 Background

In ligament surgery, length change pattern of the reconstructions are important, because the graft should not be exposed to unphysiological lengthening, nor slackening, when it should restrain a certain movement. From the biomechanical point of view a reconstruction, which has a constant length over the arc of knee flexion would be optimal. However, due to the roll-glide and `screw home` mechanism of the knee, this is not possible.¹⁴⁹ Nature has managed this with different fibre regions for ligaments. For example, the MCL is a flat and approximately one centimetre wide ligament. The anterior fibres femorally attach anterior to the medial epicondyle, whereas the posterior fibres attach posteriorly.²³ Thus, the anterior fibres will be taut in flexion, whereas the posterior fibres will be taut in extension.¹²

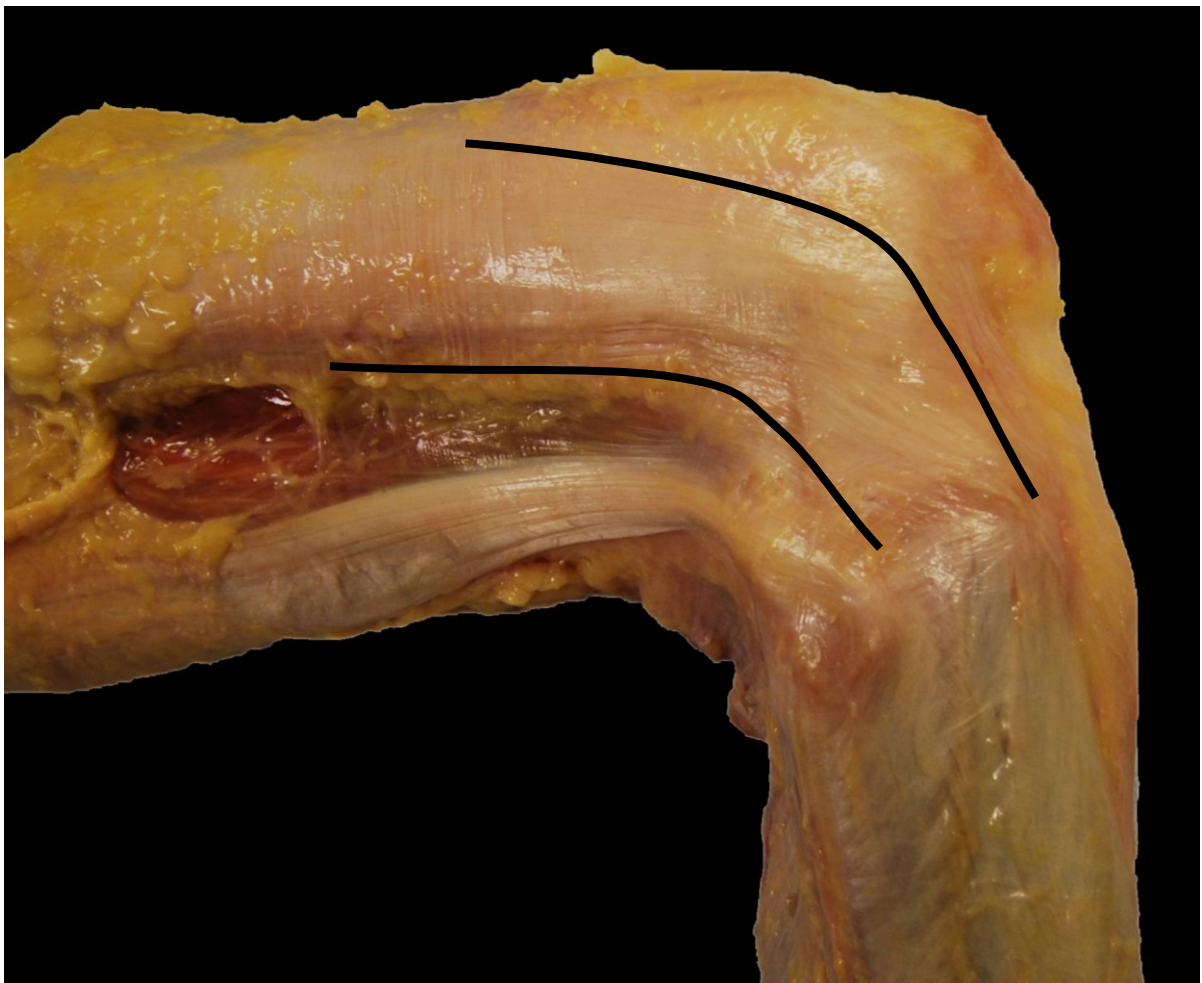

Figure 6.1 Right knee, lateral side. Anterior and posterior border of the iliotibial tract.

Similarly, to the medial side, the ITT also has a broad attachment on the anterolateral aspect of the tibia. Birnbaum et al.¹⁵ found the attachment site to be 40 mm wide. This suggests different fibre regions with different functions through the range of knee flexion⁴³. (figure 6.1) Furthermore two recent anatomical studies of the ALL described the femoral attachment anterior and distal to the lateral femoral epicondyle and suspected this ligament to restrain the anterolateral subluxation of the tibia.^{22,168} Thus knowledge of length change pattern of these native structures are crucial for future reconstructions.

The principle of isometry indicates a constant distance between two moving points, where the points are on either side of a joint. Precise isometric behaviour rarely exists and has not been found for the ACL¹²⁹ or lateral extra-articular soft-tissue reconstructions.¹⁴⁹ However, it is widely accepted that a degree of isometry in a ligament reconstruction reduces the likelihood of unwanted graft behavior.⁵ Inappropriate graft positioning and tensioning of a lateral extra-articular soft-tissue reconstruction may excessively stretch the graft at certain knee flexion angles. This may over-constrain the lateral compartment of the tibiofemoral joint and ultimately lead to graft failure, excessive compressive load on the articular cartilage in the lateral compartment, and compromise graft healing to the surrounding bone.³ It has been found that an increase in separation distance between attachment points of just 6% could lead to permanent graft stretching.¹³⁴ Conversely, if a graft becomes slack at a particular knee flexion angle, it may not be able to adequately replicate the function of the reconstructed ligament. Only a few studies of the isometry of lateral extra-articular reconstructions have been published, with none of these considering a graft passing deep to the LCL.^{36,92,93,149} Given that a lateral reconstruction is intended to stabilize the weight-bearing knee, and that the knee has greater rotational laxity when flexed, it may be desirable for a graft to tend to be tighter in extension and slacker in flexion.

6.2 Aims

The aims of the present study were to: 1. Determine the effect of changing tibial and femoral attachment points on ligament and graft length change pattern through knee range of motion. 2.

Investigate the effect of altering the path of the graft in relation to the LCL (superficial or deep). 3. Examine the length change pattern of native tissue structures, extra-articular soft-tissue reconstructions and previously-described isometric combinations^{36,92,149} on the anterolateral side of the knee. 4. Compare length change patterns of the different tibio-femoral point combinations.^{36,92,149}

6.3 Materials and Methods

6.3.1 Specimen preparation

Eight fresh-frozen left knees from donors with a mean age of 76 years (range: 69-86, 5 male and 3 female) were obtained from a tissue bank after ethical approval was given by the local research ethics committee. Prior to testing, the specimens were thawed for 24 hours; the femur was cut approximately 180 mm from the joint line, and the tibia 160 mm from the joint line. An intramedullary rod was then cemented into the femur and another into the tibia using PMMA bone cement. The skin and subcutaneous fat were then removed, leaving the muscles and the fascia intact. The ITT was then dissected away from the vastus lateralis longus and vastus lateralis obliquus muscles. The lateral retinaculum (iliopatellar band) was horizontally incised to the point where the lateral femoral condyle became clearly visible. The lateral retinaculum was sutured back after the preparation was finished. The ITT was then cut from the intermuscular septum and its deep layer (Kaplan fibres). The capsulo-osseous layer of the ITT was resected from its proximal attachment at the supraepicondylar region and its distal attachment at the lateral tibial joint margin. Thus, only the superficial ITT layer was left attached at Gerdy's tubercle. Consistent with the technique used in previous studies, the quadriceps muscle was separated into its six anatomical parts: Rectus femoris, Vastus intermedius, Vastus medialis longus, Vastus lateralis longus, Vastus medialis obliquus and Vastus lateralis obliquus.^{56,156} Cloth strips were sutured to the proximal parts of the quadriceps and to the ITT, to augment the soft tissues and to prevent slippage of the loading cables. (figure 6.2; figure 6.3)




Figure 6.2 Medial aspect of a left knee mounted into the knee extension rig. The muscles were loaded using hanging weights and a pulley system. 1 Patella; 2 Femur; 3 Vastus medialis obliquus; 4 Vastus medialis longus; 5 Rectus femoris and Vastus intermedius; 6 Vastus lateralis longus.

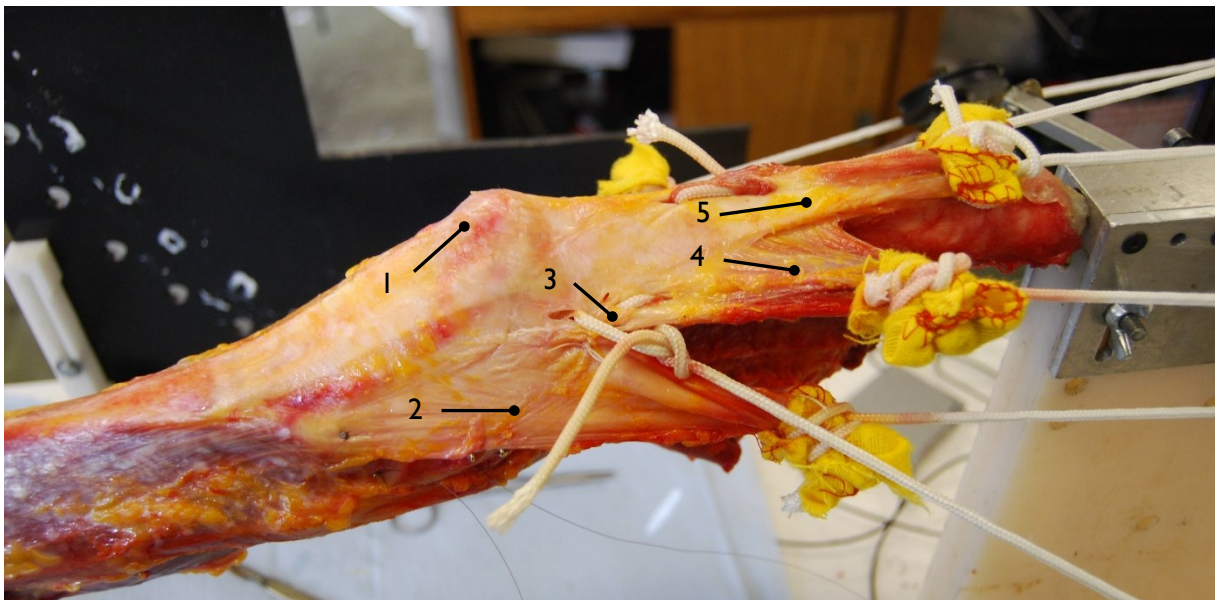


Figure 6.3 Lateral aspect of a left knee mounted into the knee extension rig. The muscles were loaded using hanging weights and a pulley system. 1 Patella; 2 Iliotibial tract left attached at Gerdy's tubercle; 3 Vastus lateralis obliquus; 4 Vastus lateralis longus; 5 Rectus femoris and Vastus intermedius.




Figure 6.4 Knee extension rig. The muscles were loaded according to their fibre direction and cross section area using hanging weights and a pulley system. The horizontal restraining bar limited the knee extension to any flexion angle. Reproduced with permission from Stephen et al.¹⁵⁶ (2012)

The femoral intramedullary rod was secured into a knee extension test rig (figure 6.4). The posterior condylar axis of the femur was aligned parallel to the base of the rig.¹⁵⁶ The anatomical parts of the quadriceps muscle and the ITT were then loaded according to their fibre orientations, using hanging weights and a pulley system. Based on previous studies, a total of 175 N was applied to the quadriceps muscle parts and 30 N to the ITT.^{56,156} According to Farahmand et al.⁴⁴ the different parts of the quadriceps muscle were loaded according to their normalised physiological cross-section area: Rectus femoris and vastus intermedius 35%, vastus lateralis longus 33%, vastus lateralis obliquus 9%, vastus medialis longus 14%, vastus medialis obliquus 9%. This replicated an unloaded open chain extension.⁵⁹ Loading states using higher forces were not tested in order to prevent muscle damage. This tension extended the knee fully, which could then be flexed and held at up to 90° of flexion (in 10° increments) using a horizontal bar anterior to the tibial rod. Prior to the length change measurements, the loaded knee was cycled ten times between 0° and 90° flexion in order to minimize the effects of soft tissue hysteresis. According to experiments it has been shown that after 10-20 cycles a steady state has been achieved¹¹⁶.

Table 6.1. Femoral eyelet positioning and corresponding tibio-femoral point combinations (four native tissue structures, four reconstructions and three femoral isometric points). ALL = anterolateral ligament; ITT = iliotibial tract; LCL = lateral collateral ligament.

Femoral Eyelet	Position (from lateral femoral epicondyle)	Tibial pin	
		pinG	pinA
E1	2mm anterior, 2mm distal	anterior part of the Losee reconstruction ¹¹⁰	mid-third lateral capsular ligament ⁷¹ ALL defined by Claes et al. ²²
E2	10mm posterior, 4mm distal	Isometric point Draganich et al. ³⁶	
E3	4mm posterior, 8mm proximal	Lemaire reconstruction ¹⁰¹ *	ALL defined by Dodds et al. ³³
E4	6mm posterior, 10mm proximal	Isometric point Sidles et al. ¹⁴⁹	
E5	over-the -top position	Rowe-Zarins reconstruction ¹⁸⁰ *	
		Isometric point F9 Krackow and Brooks ⁹² posterior part of the Losee reconstruction ¹¹⁰ *	
E6	posterior femoral cortex at the distal termination of the intramuscular septum	anterior fibres of the ITT MacIntosh reconstruction ¹¹² *	posterior fibres of the ITT

* indicates course deep to the LCL

Length changes between tibial and femoral attachments were measured by attaching small pins to the tibia and eyelets on the femur. Femoral eyelets were placed independent from knee size, due to some original publications only describing the attachment site or isometric point in a distance from the lateral femoral epicondyle. Sutures connected the pins to a displacement transducer, positioned on the base plate of the rig, via the eyelets. One tibial pin was positioned at the tip of Gerdy's tubercle (pinG), and another at the rim of the lateral tibial condyle halfway between the fibular head and Gerdy's tubercle (pinA), which has been reported as the tibial attachment site of the capsulo-osseous layer of the ITT¹⁶¹, the mid-third lateral capsular ligament⁷¹ and the ALL described by Claes

et al.²² and Dodds et al.³³. A monofilament suture was attached to each of these two pins. Three femoral eyelets, termed E1, E3, and E6, were positioned according to the anatomical structures. (figure 6.5, Table 6.1).

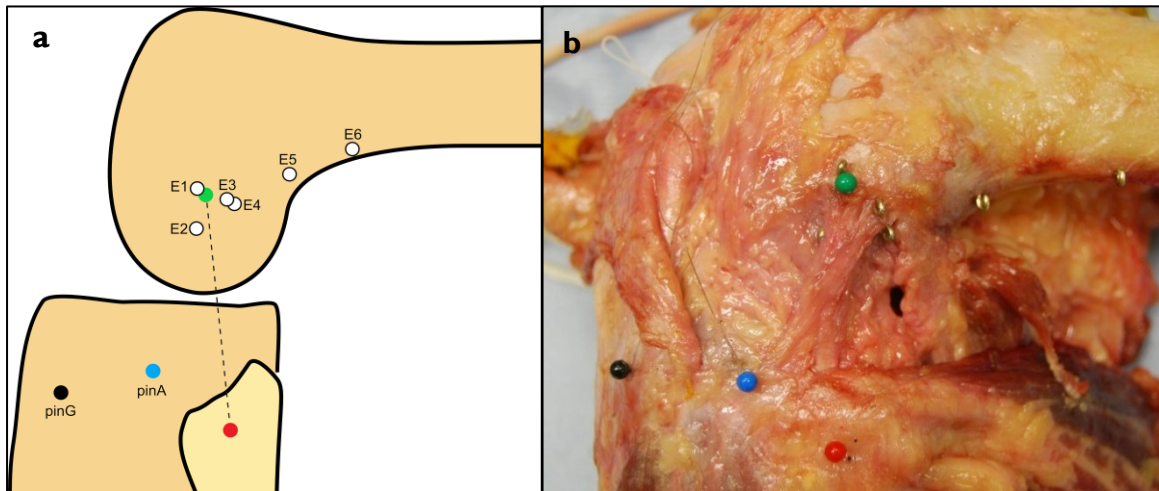


Figure 6.5 Femoral eyelet positioning (white). Tibio-femoral point combinations account for structures on the lateral side, extra-articular soft-tissue reconstructions and femoral isometric points. (a) pinG (black): Gerdy's tubercle; pinA (blue): Area of the Segond avulsion; Dashed line: lateral collateral ligament; green pin: lateral epicondyle. (b) black pin: Gerdy's tubercle; blue pin: Area of the Segond avulsion; red pin: fibular head; green pin: lateral epicondyle.

These lateral extra-articular soft-tissue reconstructions typically route a strip of the ITT beneath the LCL and loop it back to Gerdy's tubercle via a bone tunnel in the lateral femoral condyle (Lemaire, Losee), via a suture fixation on the intermuscular septum (MacIntosh), or via the over-the-top position after an intra-articular ACL reconstruction (Rowe-Zarins).

The monofilament suture was collinearly knotted to a linear variable displacement transducer (LVDT) (Solartron Metrology, Bognor Regis, UK), thereby enabling measurement of length changes between a pin and an eyelet at knee flexion angles between 0 and 90° (in 10° increments). The monofilament suture was constantly under a small tension due to the weight of the sliding core of the LVDT (0.5 N). (figure 6.6 and figure 6.7) Knot slippage was not observed throughout the whole experiment.

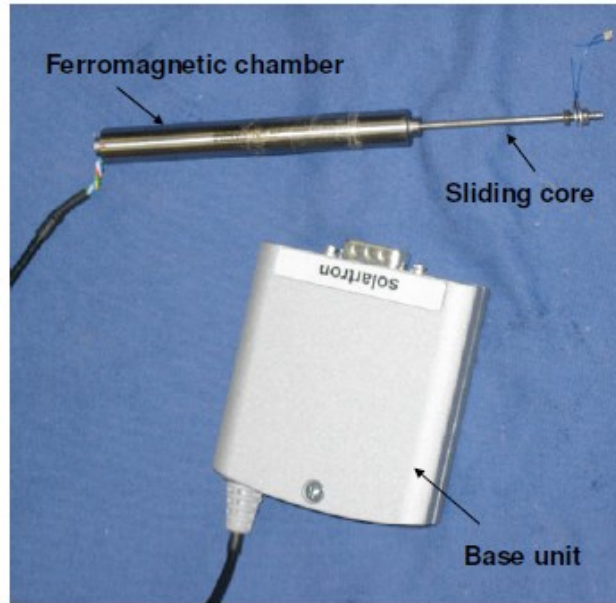


Figure 6.6 Linear variable displacement transducer setup. Depending on the location of the sliding core the ferromagnetic chamber produces a voltage change, which is transmitted to the Solartron base unit. This voltage change can be converted to millimetre length change and stored to an Excel sheet on the local computer. Reproduced with permission from Ghosh KM⁵⁵, The Effects of Total Knee Replacement on the Extensor Retinaculum of the Knee; a thesis for the degree of MD(Res) and Diploma of Imperial College. (2009)

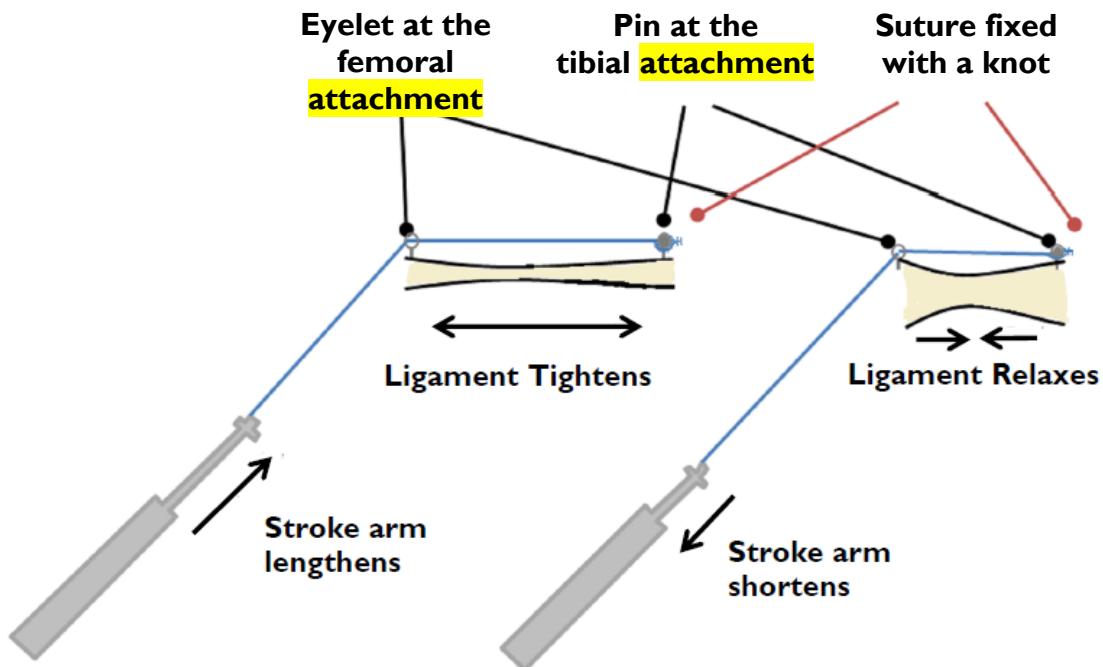


Figure 6.7 A monofilament suture connected the tibia with the femur using a pin and an eyelet. When the ligament tightened the stroke arm of the linear variable displacement transducer (LVDT) lengthened, whereas when the ligament relaxed the stroke arm of the LVDT shortened. Reproduced with permission and adapted from Ghosh et al.⁵⁵ (2009), and Stephen et al.¹⁵⁵ (2014)

Depending on the structure, lateral reconstruction method or isometric point being assessed, the suture was guided either superficial or deep to the LCL. (Table 6.1) Length change measurement data were collected for each of the 16 ligaments or reconstructions in each of the 8 knees, then processed using Solatron “Orbit” Excel software (Solatron Metrology). Each measurement was repeated three times and the average results were used for analysis. Duration of testing for the 48 repetitions per knee was approximately ten hours.

6.3.2 Data analysis

At full extension the sutures were marked at the femoral pin using a pen and absolute lengths between the tibial pin and the mark were measured using a ruler, to +/- 0.5 mm at 0°. The length change data were then normalized to percentage (strain = $\frac{\text{length change}}{\text{length at } 0^\circ} \times 100\%$) with reference to the length at 0° knee flexion.

In order to compare the isometry of the different tibio-femoral combinations, the total strain range (TSR = maxStrain – minStrain) was calculated for each knee and then averaged. Low values of TSR reflect near-isometry, and high values non-isometry.

6.3.3 Statistical Analysis:

The Kolmogorov-Smirnov test confirmed the normal distribution of the data.

1. Overall effects of changing the graft attachment position on the tibia (pinA and pinG) and the femur (E1 to E6) and knee flexion (0°-90°) were calculated using a repeated measures ANOVA. The course past the LCL was constant (superficial).

2. A repeated measures ANOVA was performed to investigate the effects of: graft path relative to the LCL (deep and superficial), femoral position (E3 to E6) and knee flexion (0°-90°). The tibial position was constant (pinG)

3. Three 2-way repeated measures ANOVAs were conducted to compare length changes on:

a) Native tissue structures of the anterolateral side (pinA/E1, pinA/E3, pinA/E6, and pinG/E6) vs. flexion angle (0°-90°).

b) Lateral extra-articular soft-tissue reconstructions (pinG/E1, pinG/E3*, pinG/E5*) (* deep to the LCL) vs. flexion angle (0°-90°).

c) Femoral isometric combinations (pinG/E2, pinG/E4 and pinG/E5) vs. flexion angle (0°-90°)

4. Three one-way ANOVAs were performed comparing TSR for native tissue structures, lateral extra-articular soft-tissue reconstructions and femoral isometric points.

Pairwise comparisons with Bonferroni corrections were performed where appropriate. Statistical analysis was performed in SPSS (Statistical Package for the Social Sciences, IBM Corp., Armonk, New, York, U.S.) version 21, with significance level set at $P < 0.05$.

6.4 Results

6.4.1 Attachment sites.

Altering the femoral attachment site had a large effect on the length changes ($P < .001$): for example, changing from pinA/E1 to pinA/E3 changed the pattern from slackening to tightening with knee flexion (figure 6.8). The tibial attachment location had a smaller effect on length change pattern, but was still significant ($P < .001$), for example changing from pinA/E6 to pinG/E6.

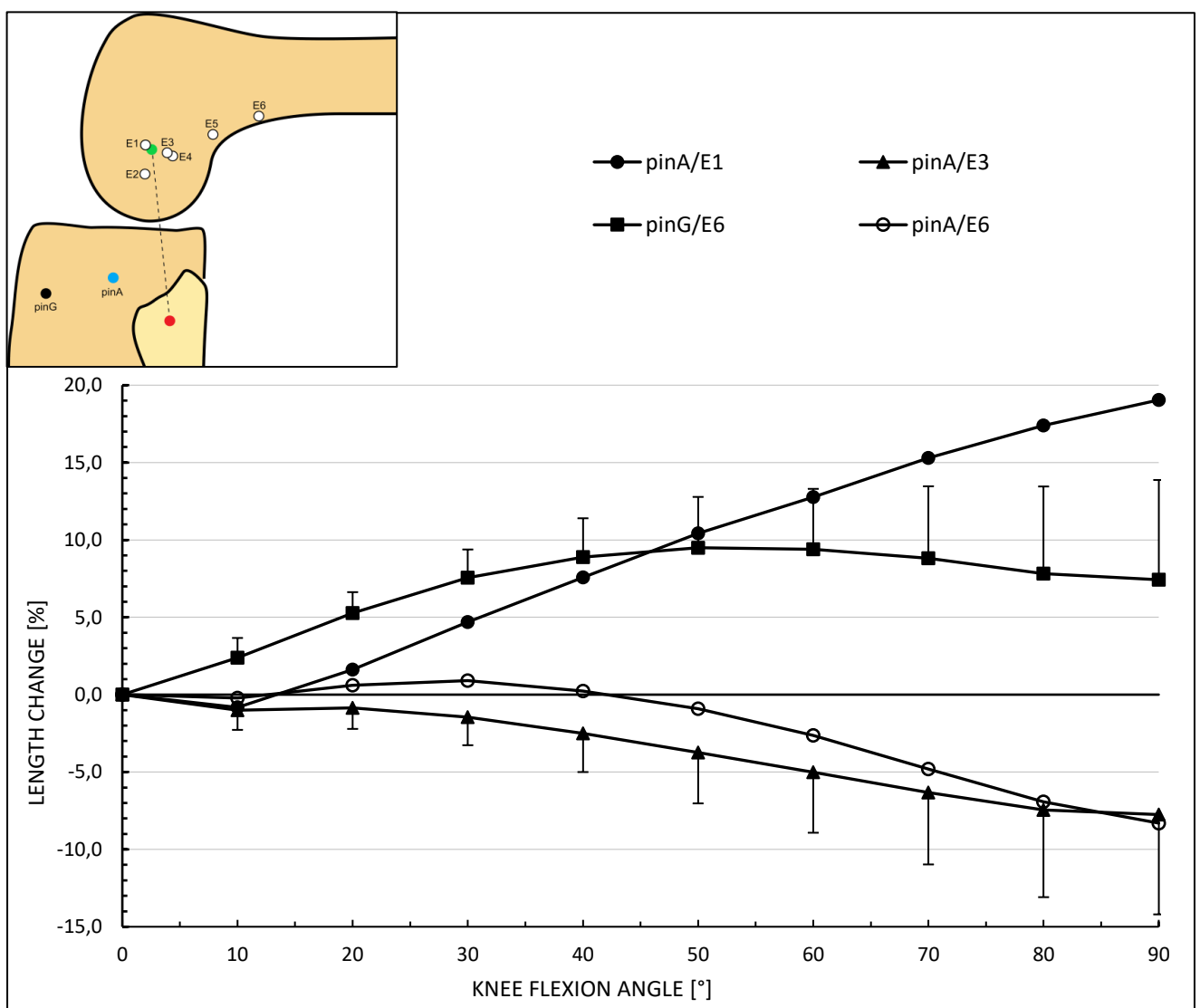


Figure 6.8 Length change pattern of all tested native tissue structures with pooled 95% confidence interval. In relation to tibial pin A, a change from femoral eyelet E1 to E3 changed the length change from a mean 19mm elongation to 8mm shortening. Moving from G to A on the tibia had a smaller effect, in relation to femoral eyelet E6.

6.4.2 Graft course:

Graft length change patterns were significantly different depending on whether the graft ran superficial or deep to the LCL ($P < .001$, figure 6.9). There was a tendency for the superficial grafts to lengthen during early knee flexion, whereas those running deep to the LCL tended to decrease in length.

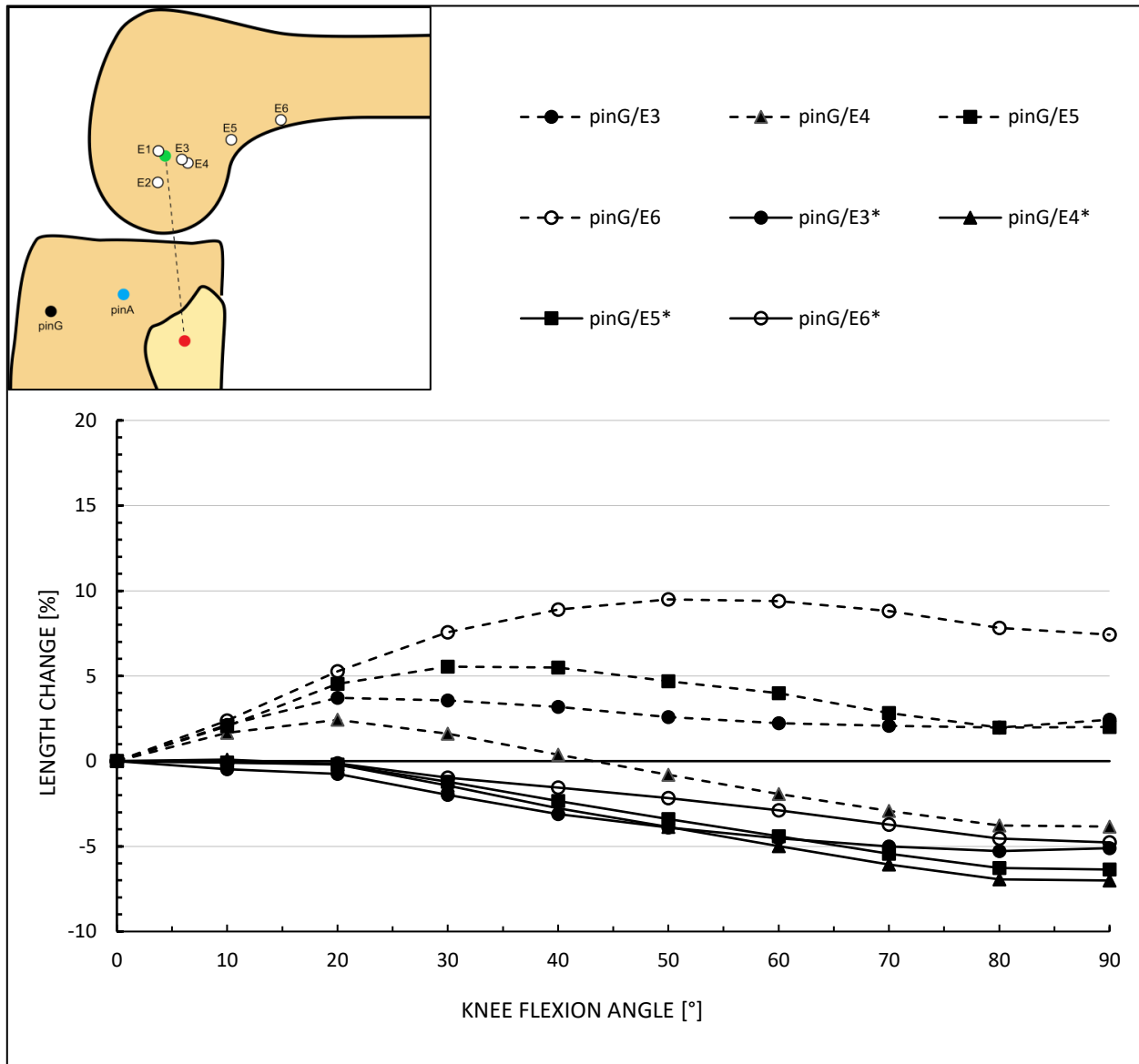


Figure 6.9 Differences between tibio-femoral point combinations superficial and deep (*) to the lateral collateral ligament (LCL). The combinations guided deep to the LCL displayed less variability in length change patterns.

6.5 Length change pattern and total strain range

6.5.1 Native tissue structures of the anterolateral side of the knee

The attachment points of the ALL described by Dodds et al.³³ (pinA/E3 combination) was most isometric among the ligaments on the anterolateral side (TSR = $8.7 \pm 5.7\%$; mean \pm SD), decreasing in length between 30° and 80° of knee flexion (where a decrease in length between the points means a tendency for a graft to slacken, and vice-versa). However, no significant difference in TSR value was found compared to the other ligament combinations tested (figures 6.8 and 6.10, Tables 6.2 and 6.3).

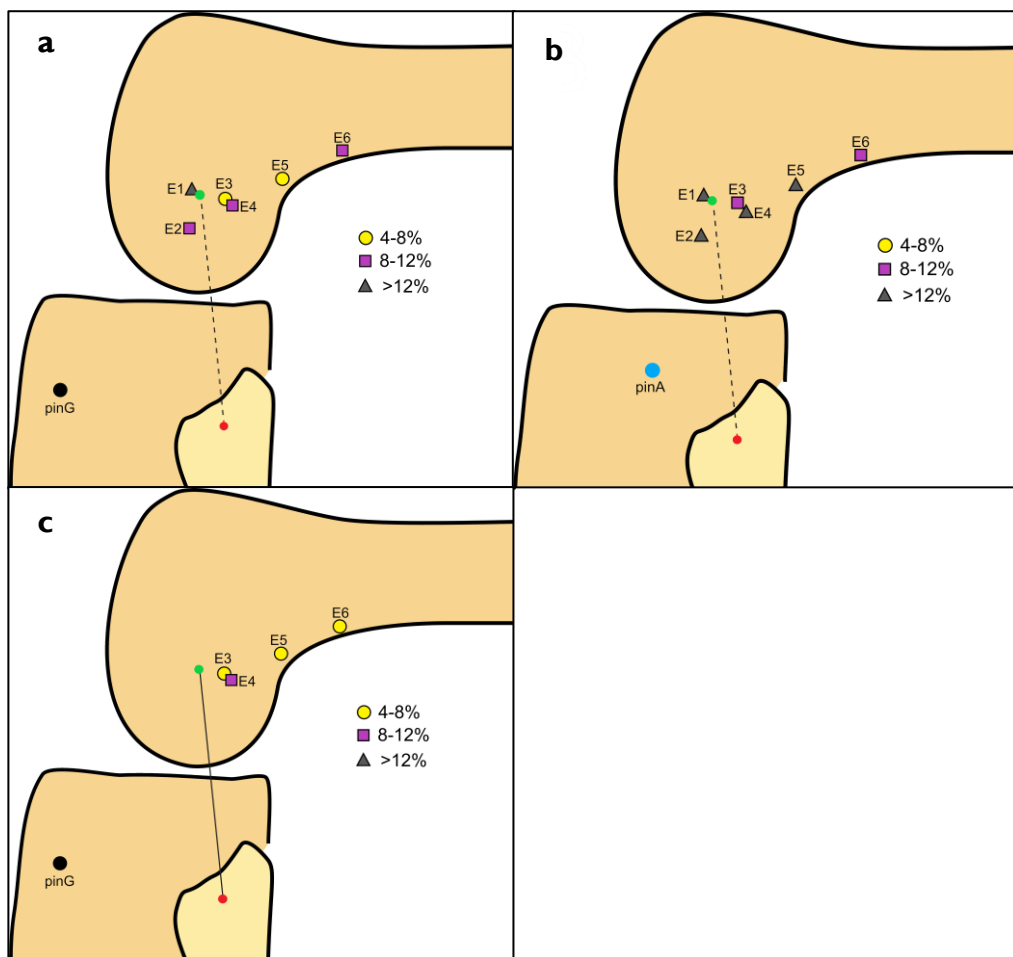


Figure 6.10 Extra-articular isometry map for various tibio-femoral point combinations. Total strain range values (TSR) were plotted onto the femur. Low values indicate near isometry and high values non-isometry. Green pin: lateral femoral epicondyle; red pin: fibula head; black pin Gerdy's tubercle; blue pin: Area of the Second avulsion. (a) TSR values in combination with pinG, the suture was guided superficial to the lateral collateral ligament (LCL). (b): TSR values in combination with pinA, the suture was guided superficial to the LCL. (c): TSR values in combination with pinG, the suture was guided deep to the LCL.

The length between the attachment points of the ALL described by Claes et al.²² (the pinA/E1 combination) gradually increased between 10° and 90° flexion, with the greatest overall TSR of 20.2 ± 8.4% among all ligament combinations. This length change pattern was significantly different compared to both the ALL of Dodds et al.³³ (pinA/E3: P < .001) and the posterior fibres of the ITT (pinA/E6: P < .001).

The posterior fibres of the ITT (pinA/E6 combination) were almost isometric at flexion angles between 0° and 50°, then displayed a decrease in length from 50° to 90° (TSR = 9.4 ± 3.3%). The anterior fibres of the ITT (pinG/E6 combination) increased in length between 0° and 40° of flexion (TSR = 10.4 ± 3.4%), and were then almost isometric from 40° to 90°. There was a significant difference in overall length change pattern between these two combinations (P < .001).

No significant differences in TSR values were found among all ligament combinations tested.

Table 6.2: Length change (%) and significant differences at each flexion angle for ligament tibio-femoral point combinations.

Native tissue structures		pinA/E1 #,†		pinA/E3 *,§		pinG/E6 #,†		pinA/E6 *,§	
Knee flexion angle (°)	Mean	SD	Mean	SD	Mean	SD	Mean	SD	
0	0.0	0.0	0.0	0.0	0.0	0.0	0.0	0.0	
10	-0.8 §	1.7	-1.0 §	1.5	2.4 *,#,†	1.1	-0.2 §	0.5	
20	1.6 #,§	1.8	-0.9 *,§,†	1.4	5.3 *,#,†	1.2	0.6 #,§	0.8	
30	4.7 #,†	2.6	-1.4 *,§,†	1.9	7.6 #,†	1.3	0.9 *,#,§	1.1	
40	7.6 #,†	3.4	-2.5 *,§,†	2.6	8.9 #,†	2.0	0.2 *,#,§	1.8	
50	10.4 #,†	4.4	-3.7 *,§,†	3.2	9.5 #,†	2.9	-0.9 *,#,§	2.3	
60	12.8 #,†	5.4	-5.0 *,§	3.8	9.4 #,†	3.3	-2.6 *,§	2.7	
70	15.3 #,†	6.5	-6.3 *,§	4.6	8.8 #,†	4.0	-4.8 *,§	2.8	
80	17.4 #,§,†	8.0	-7.5 *,§	5.4	7.8 *,#,†	4.7	-6.9 *,§	3.3	
90	19.0 #,§,†	8.8	-7.8 *,§	6.5	7.4 *,#,†	5.5	-8.3 *,§	4.1	

* indicates statistical significance from pinA/E1

indicates statistical significance from pinA/E3

§ indicates statistical significance from pinG/E6

† indicates statistical significance from pinA/E6

SD: Standard Deviation

Table 6.3 Total strain range values of each tested tibio-femoral point combination. LCL = lateral collateral ligament,

Femoral eyelet	Superficial to LCL				Deep to LCL	
	pinG		pinA		pinG	
	Mean	SD	Mean	SD	Mean	SD
E1	25.9	9.8	20.2	8.4		
E2	9.5	3.4	14.2	5.9		
E3	7.2	1.9	8.7	5.7	7.1	3.5
E4	8.0	3.9	15.3	5.3	8.7	4.3
E5	8.0	3.2	14.1	4.2	7.3	2.7
E6	10.4	3.4	9.4	3.3	5.5	2.4

SD: Standard Deviation

6.5.2 Lateral Extra-articular soft-tissue reconstructions

The suture following the course of the MacIntosh procedure¹² (pinG/E6 combination), routed deep to the LCL, was closest to isometry among all tibio-femoral point combinations tested (figures 6.9 and 6.10, Tables 6.3 and 6.4), with an overall TSR of $5.5 \pm 2.4\%$. The length change patterns of the MacIntosh, Rowe-Zarins¹⁸⁰/posterior part of the Losee¹¹⁰ and Lemaire¹⁰¹ lateral extra-articular soft-tissue reconstruction (pinG/E6, pinG/E5 and pinG/E3) were all similar when guided deep to the LCL (figures 6.9 and 6.11), particularly between 0° and 30°. The three corresponding femoral attachments (eyelets E3, E5 and E6) were located on a straight oblique line on the lateral aspect.

The anterior part of the Losee reconstruction¹¹⁰ (pinG/E1 combination) displayed a uniform increase in length between 0° and 90° of knee flexion (TSR = $25.9 \pm 9.8\%$), and its length change pattern was significantly different ($P < .001$) compared to those of all other tested reconstructions. Also, the TSR value was significantly higher than that of the Lemaire (pinG/E3; $P = .024$), Rowe-Zarins/posterior part of the Losee reconstruction (pinG/E5; $P = .017$), and the MacIntosh reconstruction (pinG/E6; $P = .010$).

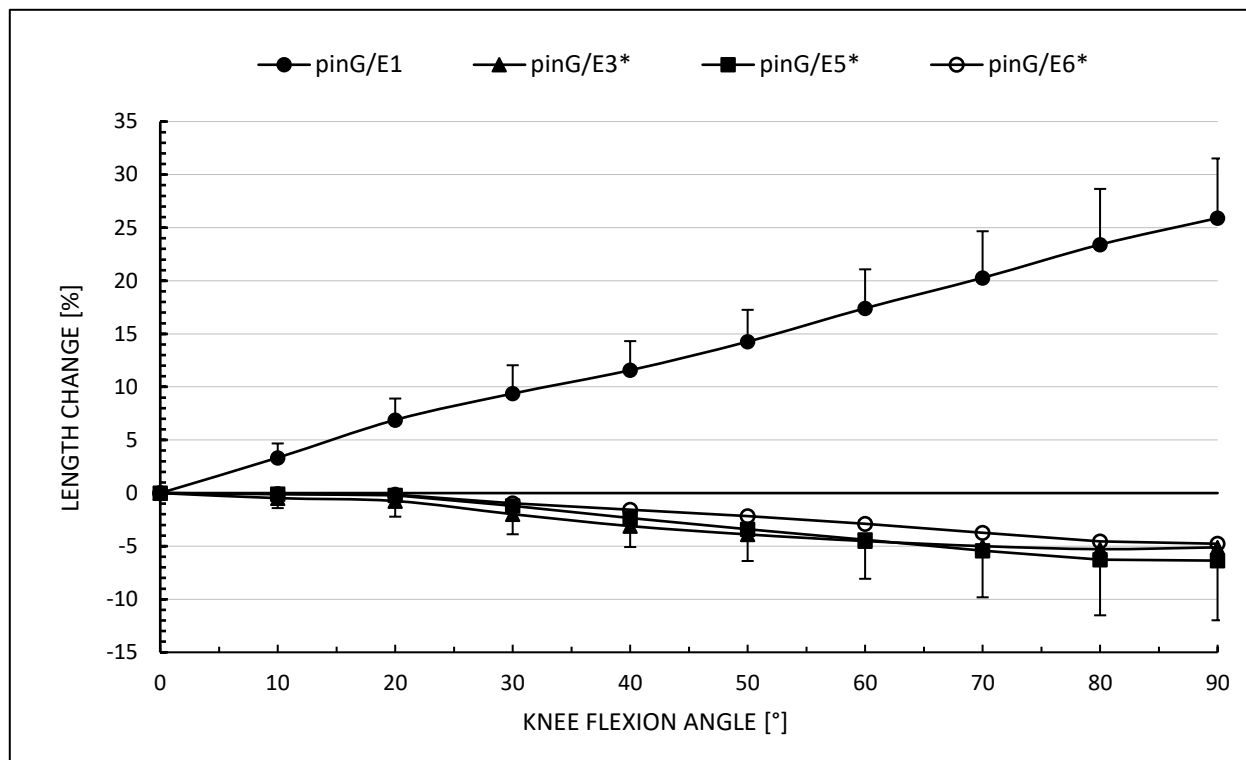


Figure 6.1 | Length change pattern of all tested reconstructions with pooled 95% confidence interval. Femoral insertion points proximal to the lateral epicondyle display similar length change pattern. *: graft passed deep to the lateral collateral ligament.

Table 6.4 Length change (%) and significant differences at each flexion angle for reconstruction tibio-femoral point combinations. The course of the suture was deep to the lateral collateral ligament.

Reconstructions Knee flexion angle (°)	pinG/E1 #,§,†		pinG/E3 *		pinG/E5 *,†		pinG/E6 *,§	
	Mean	SD	Mean	SD	Mean	SD	Mean	SD
0	0.0	0.0	0.0	0.0	0.0	0.0	0.0	0.0
10	3.3 #,§,†	1.5	-0.5 *	1.8	-0.1 *	1.0	-0.1 *	0.9
20	6.9 #,§,†	2.1	-0.7 *	2.7	-0.2 *	1.7	-0.1 *	1.4
30	9.4 #,§,†	3.3	-2.0 *	3.1	-1.2 *	2.3	-1.0 *	1.6
40	11.6 #,§,†	4.0	-3.1 *	2.8	-2.3 *,†	1.9	-1.6 *,§	1.5
50	14.3 #,§,†	4.9	-3.9 *,†	2.5	-3.4 *,†	1.8	-2.2 *,§	1.5
60	17.4 #,§,†	6.3	-4.5 *	2.8	-4.4 *,†	1.9	-2.9 *,§	1.5
70	20.3 #,§,†	7.7	-5.0 *	3.3	-5.4 *,†	2.1	-3.7 *,§	1.7
80	23.4 #,§,†	9.2	-5.3 *	3.8	-6.3 *,†	2.6	-4.5 *,§	1.9
90	25.9 #,§,†	9.8	-5.1 *	4.1	-6.4 *,†	2.8	-4.8 *,§	2.4

* indicates statistical significance from pinG/E1

indicates statistical significance from pinG/E3

§ indicates statistical significance from pinG/E5

† indicates statistical significance from pinG/E6

SD: Standard Deviation

6.5.3 Femoral isometric points

The isometric pair of points of Krackow and Brooks⁹² (pinG/E5, passing superficial to the LCL) displayed a slight length increase between 0° and 30° and a slight decrease between 40° and 80° (TSR = $8.0 \pm 3.2\%$; figures 6.10 and 6.12, Table 6.5). The length changes of this combination, the isometric points of Sidles et al.¹⁴⁹ (pinG/E4; TSR = $8.0 \pm 3.9\%$), and of Draganich et al.³⁶ (pinG/E2; TSR = 9.5 ± 3.4) all followed a broadly similar pattern.

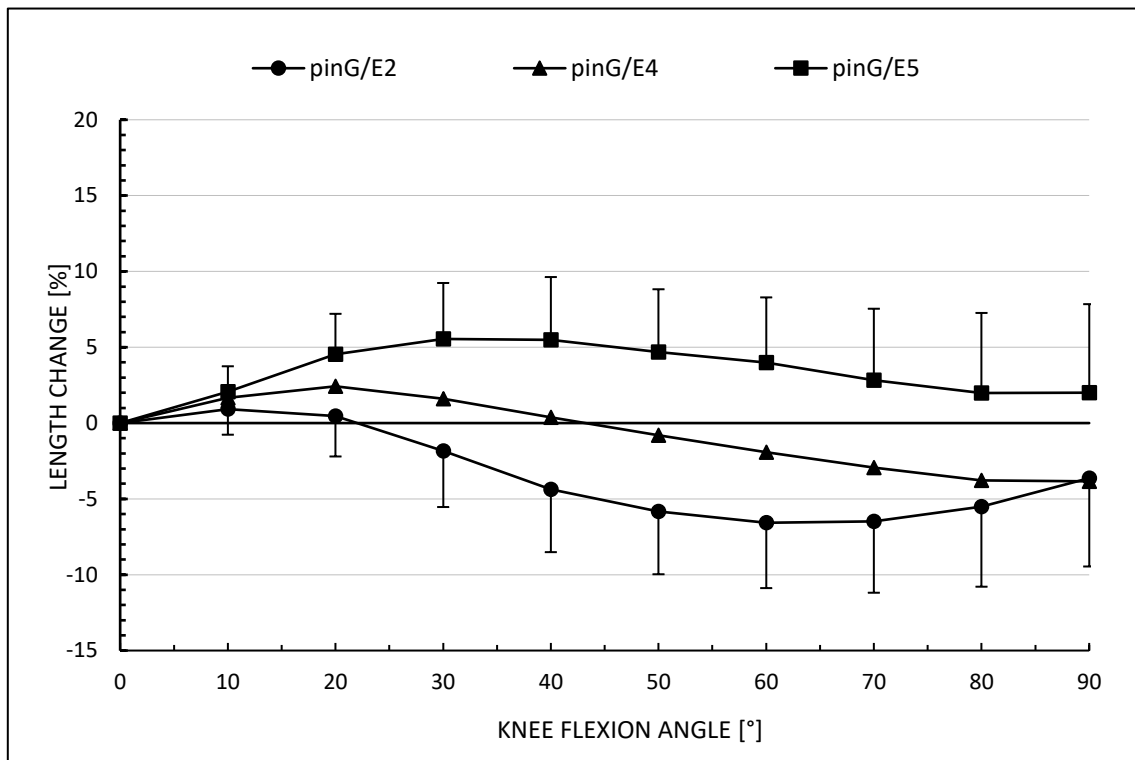


Figure 6.12 Length change pattern of all tested femoral isometric points with pooled 95% confidence interval.

Table 6.5 Length change (%) and significances at each flexion angle for tested femoral isometric points.

Isometric Points						
Knee flexion angle (°)	pinG/E2 #,§		pinG/E4 *,§		pinG/E5 *,#	
	Mean	SD	Mean	SD	Mean	SD
0	0.0	0.0	0.0	0.0	0.0	0.0
10	0.9 §	1.6	1.7	1.8	2.1 *	1.6
20	0.5 §	3.0	2.4 §	2.4	4.5 *,#	2.6
30	-1.8 #,§	4.1	1.6 *,§	3.3	5.5 *,#	3.7
40	-4.4 #,§	4.4	0.4 *,§	3.4	5.5 *,#	4.5
50	-5.8 #,§	4.0	-0.8 *,§	3.5	4.7 *,#	4.8
60	-6.6 #,§	3.9	-1.9 *,§	3.8	4.0 *,#	5.0
70	-6.5 #,§	4.6	-2.9 *,§	4.4	2.8 *,#	5.2
80	-5.5 §	5.1	-3.8 §	5.1	2.0 *,#	5.6
90	-3.6 §	5.5	-3.8	5.5	2.0 *	6.5

* indicates statistical significance from pinG/E2

indicates statistical significance from pinG/E4

§ indicates statistical significance from pinG/E5

SD: Standard Deviation

6.6 Discussion

The purpose of the present study was to assess length change patterns and isometry of several combinations of tibial and femoral points on the lateral side of the knee. This is the first study to our knowledge to investigate the course of a graft running deep to the LCL, which makes it relevant to previously described surgical techniques of lateral extra-articular soft-tissue reconstructions. All tibio-femoral reconstruction combinations inserting proximal to the lateral epicondyle and with a course deep to the LCL (pinG/E3, pinG/E5, and pinG/E6) were close to being isometric between 0° and 90° knee flexion, with only a slight increase in length as the knee was extended. These are ideal properties for a lateral extra-articular soft-tissue reconstruction. These reconstruction combinations had very similar length change patterns. This similarity was because their course was deep to the LCL, and therefore the lateral epicondyle, with the proximal LCL attachment, acted as a pulley,

retaining the graft posterior to the knee flexion axis of rotation within the investigated range of motion. Conversely, there was much greater variability in length change patterns when the suture was guided superficial to the LCL. In this case, the epicondyle acted as a 'hump' and the suture remained anterior for low flexion angles and moved posteriorly as flexion angle increased.

Krackow and Brooks⁹² examined various tibio-femoral point combinations with a flexible ruler. They applied a central load to the whole quadriceps muscle group and did not load the ITT, in contrast to this study. The length change pattern of their 'T3 to F9' combination was close to isometric, and a similar result was found in this study when reproducing it using the pinG/E5 combination.

Furthermore, we also observed Gerdy's tubercle moving slightly laterally/posteriorly in terminal knee extension due to the 'screw home mechanism'. Thus, length slightly decreased at low flexion angles (figure 6.12). With regard to the effect of alteration of the femoral eyelet observed by Krackow and Brooks, the length change plot displayed a uniform lengthening during knee flexion when the femoral insertion site was distal and anterior to the lateral epicondyle (pinG/E1).

Conversely, when moving the femoral insertion site proximal and posterior to the lateral femoral epicondyle (pinG/E3 and pinG/E4), the length change plot showed an increase in length in low flexion angles, and then decreasing length in high flexion angles.

The most isometric combination of the present study was the pinG/E6 combination, corresponding to the MacIntosh reconstruction.¹¹² This suture path deep to the LCL does not represent a native structure of the knee. However, the MacIntosh reconstruction anchors the ITT to its natural attachment on the femur at the distal termination of the intermuscular septum (Kaplan fibres), which may explain the high degree of isometry. The most isometric femoral point combination with Gerdy's tubercle reported by Sidles et al.¹⁴⁹ (corresponding to the pinG/E4 combination) in a quadriceps-loaded knee was approximately 10 mm proximal and 6 mm posterior to the lateral femoral epicondyle. That reported by Draganich et al.³⁶ (corresponding to the pinG/E2 combination) was 4 mm distal and 10 mm posterior to the lateral femoral epicondyle. However, analogous to Sidles et al. and Draganich et al., no perfectly isometric combination was found. Further comparisons of the data in this study to those two studies are difficult, because both of them involved calculations

of a theoretical 3-D straight-line distance, rather than the actual path accounting for anatomical irregularities and the course deep to the LCL.

The data for the length change measurements of the capsular ALL of Claes et al.,²² who found an average length increase from full extension to 90° flexion of 3 mm, were consistent with this study. However, this study measured a length increase in the pinA/E1 combination of more than double that amount (7.4 ± 3.0 mm), resulting in a strain of $19.0 \pm 8.8\%$ at 90° flexion. These results imply that the ALL described by Claes et al. and the mid-third lateral capsular ligament are slack in low flexion angles, which is where the pivot-shift occurs, because soft tissues cannot sustain large strain cycles. Dodds et al.³³ found a mild decrease in length of their ALL of 5.8 ± 4.1 mm from 0°-90°, and the matching pinA/E3 combination in this study had a similar length decrease of 4.0 ± 3.5 mm.

In good agreement with length change measurements in previous studies of the ITT,^{64,108} the anterior fibres (pinG/E6) displayed a plateau of increased length in high flexion angles, whereas the posterior fibres (pinA/E6) had a plateau of increased length in low flexion angles. This implies that different ITT fibre areas are taut in different flexion ranges. These findings suggest that it is not the ALL alone that controls anterolateral rotation of the tibia, and that other structures such as parts of the ITT may have a role. This is emphasized by the findings of Terry and Laprade, that the anterior arm of the short head of the biceps femoris muscle, the capsulo-osseous layer of the ITT and the mid-third lateral capsular ligament were attached at the site of the Segond fragment.¹⁶²

It is known from previous clinical studies that extra-articular soft-tissue reconstructions in combination with an intra-articular ACL reconstruction are capable of controlling the anterior subluxation of the lateral tibial plateau.^{102,120,144,166} This is supported by this study, as all tested reconstructions except for the anterior part of the Losee reconstruction showed a lengthening as the knee approached full extension. The femoral insertion sites of these reconstructions, passing deep to the LCL, were all located on an oblique line on the distal femur from just proximal to the lateral epicondyle to the posterior edge of the lateral aspect of the femur at the metaphysis. It is possible that all points on this line may have similar length change patterns and low TSR values, thereby presenting a safe area for positioning the extra-articular femoral insertion point. However,

care must be taken when combining length change data with other factors such as femoral graft fixation and tensioning. The length change plots only represent the mean length change of eight specimens, which included minor inter-specimen variability. This may be due to different knee kinematics and anatomic variations. For example, in one knee there was a thicker femoral insertion of the lateral gastrocnemius tendon, which changed the path of the suture.

6.7 Limitations

In addition to the age and number of knees, there are some limitations of this study to note. First, an active loading state was created by loading the quadriceps muscle parts and the ITT according to their fibre directions. Only one loading state, independent from knee size was tested, and others were not considered. A second limitation was the use of a suture to measure tibiofemoral point length changes. This reduced the complex fibre bundle structure of a ligament or a graft to effectively a single fibre, which may have had an effect, particularly when passing the suture deep to the LCL. This study has provided data on the changes of length between attachment points in the intact knee; use of tendon grafts in actual reconstructions would add further variables: the type of graft, the tension, the fixation method, the angle of knee flexion and of tibial internal-external rotation would all affect the results and may be studied separately. Thirdly, the maximum unloaded length¹⁰³ of each ligament was not measured (That is: the point of transition from the ligament being slack, to being taut.); hence, we can only speculate on the actual tensile strain. However, the strain of reconstruction grafts can also be influenced by varying the flexion angle of graft fixation, and pre-tensioning. Additionally, we felt that it was preferable to 'normalize' all femoral eyelet locations. This proved to be less straightforward than imagined, because of the variable ligament attachment sites, ambiguous anatomical descriptions and different knee sizes. For example, the main femoral attachment of the mid-third lateral capsular ligament has been described at the tip of the lateral femoral epicondyle.^{22,71} However we observed an attachment site slightly anterior and distal, resulting in a 2mm distance between actual and described attachment sites (Table 6.1). Extensive

dissection of the ITT and the lateral retinaculum may have changed knee kinematics and the results. However, once the pins were placed the retinaculum was sutured and the ITT was loaded, which minimised the possible error. Finally: lateral extra-articular reconstruction is usually used to control tibial internal rotational laxity, and so data showing the effects of tibial rotation on the structures examined would be of interest. However, we faced the practical limitation of the time required to make those extra measurements on the set of knees, which would have been excessive, and also the consideration that it would be more clinically relevant to perform measurements of restraint to tibial rotation, rather than length changes.

6.8 Conclusion

The results of this study provide a rationale regarding the course and the behaviour of the graft for an extra-articular lateral-based reconstruction. The sutures representing grafts that ran deep to the LCL, with insertion sites proximal to the lateral epicondyle, showed desirable length-change patterns, having relatively low length changes during knee flexion-extension, and being longer (tighter) near knee extension, implying an ability to prevent anterior subluxation of the lateral tibial plateau. This path and femoral attachment site did not correspond to any anatomical structure. The ALL of Dodds et al. ⁸ passed over the LCL and gave a similar length-change pattern, but some other ligaments or lateral extra-articular soft-tissue reconstructions did not provide this. Further studies should determine which of the lateral structures resist the loads that tend to cause tibial internal rotational subluxation, and address the biomechanical behaviour of lateral extra-articular reconstructions.

7 General discussion and future work

Some parts of this chapter have been published in The American Journal of Sports Medicine

The role of the anterolateral structures and the ACL in controlling laxity of the intact and ACL-deficient knee: response; The American Journal of Sports Medicine, Volume 44, Number 4, pages: NP15-NP18

C Kittl, H El-Daou, KK Athwal, CM Gupte, A Weiler, A Williams, AA Amis

For permissions, see Chapter 9 (Appendix)

7.1 Research findings

7.1.1 Anatomy of the anterolateral complex (Chapter 2)

The most important finding of chapter 2 was that the anatomy of the anterolateral side of the knee is complex and difficult to understand. This is emphasised by numerous studies describing the ALL differently. The first studies by Vincent et al.¹⁶⁸, and Claes et al.²² described the attachment distal to the lateral epicondyle, whereas later studies found the attachment proximal to it.

Werner Mueller¹²¹ explained in the ESSKA knee video, where he dissected a whole knee: Big structures – big function, small structures – small function. By big structures, he implicated the role of the ITT. This broad strong band of fibres extends on the lateral side of the knee and can be divided into a proximal dynamic portion, and a distal static portion, which he called the “ligamentum femorotibiale laterale anterius”. This was previously also called the “capsulo-osseous layer” in the Anglo-American literature.

One of the main problems of the existing anatomical descriptions is that studies have described different structures and given them the same names. For example, Terry et al.¹⁶¹ and Viera et al.¹⁶⁷ called the distal, deep portion of the ITT the ALL of the knee. Later, several other research groups found a distinct capsular ligament, which was also named the ALL of the knee.

According to Mueller the anatomy of the anterolateral side of the knee in this thesis was dissected from anterior to posterior. This revealed the Kaplan fibre network and the capsulo-osseous layer of the ITT, which could be obviously tightened, when internal rotation of the tibia was applied.

7.1.2 Biomechanics of the anterolateral structures (Chapter 3)

ACL rupture causes the loss of the screw home mechanism and shifts the axis of rotation medially. This leads to a positive pivot-shift phenomenon. From the literature it remained unclear as to how integrity of the anterolateral structures influences the pivot-shift test, which is elicited by the examiner applying internal tibial rotation, valgus rotation, anterior tibial translation and knee flexion. In one of the pilot knees following the cutting study of this thesis, the layered anatomy of the ITT was dissected and internal rotation was applied. A tensioning of the “Kaplan fibres” and the superficial ITT could be clearly seen, whereas the anterolateral capsule was only a little stretched. This led to the testing of the contributions of the lateral structures in restraining knee laxity presented in the following chapter.

7.1.3 The role of the anterolateral structures in restraining knee laxity (Chapter 4)

As hypothesised from manually manipulating the pilot knee specimen, the six degree of freedom robotic setup demonstrated the ITT to be the primary restraint to internal rotation at 30°, 60°, and 90° of flexion. At full extension, the restraint with the highest contribution was the ACL, which was not expected, because of its small lever arm for rotation of the knee.

As described in chapter 2, the screw home mechanism is due to the tension in the ACL, which is lost in ACL-deficient knees. This biomechanical study confirmed that loss of ACL integrity results into increased internal rotation at full extension, when the ACL is ruptured. This fact adds to the knowledge of the pivot-shift phenomenon and may explain why the pivot-shift test is positive in an isolated ACL injury.

Another key finding of this study was that, in the ACL-deficient knee, the ITT (especially the deep fibres), took over the internal rotation restraining role from the ACL in full knee extension. This may imply that in a chronic ACL insufficient knee the ITT will be exposed to an increased load, which then may “stretch-out” over time and cause excessive ALRI.

7.1.4 Extra-articular lateral reconstructions (Chapter 5)

This chapter gave an overview of existing extra-articular lateral reconstructions. The main finding of this chapter was that a combined intra-, and extra-articular reconstruction can share the load and reduced the re-rupture rate in large cohort studies.¹⁵¹ However, clear indications and long-term studies are still missing.

7.1.5 Length change pattern of the anterolateral structures and related reconstructions (Chapter 6)

The study presented in chapter 6 was the first study conducted in the context of this thesis. Prior literature showed that the natural behaviour of the native anterolateral structures and their related reconstructions were poorly understood. Length changes of the native anterolateral structures and lateral extra-articular reconstructions were determined using LVDTs and a suture.

One important finding of this chapter was that the anterior and posterior parts of the ITT have a reciprocal tensioning pattern. The length of the anterior part increased in flexion, whereas the length of the posterior part increased in extension. This seems logical, because the roll-glide mechanism of the knee causes a point located posterior to the lateral epicondyle and a point on the lateral tibia will approach each other with knee flexion. Conversely, when extending the knee, a point anterior to the lateral epicondyle approaches a point on the anterolateral tibia.

A key finding was, that reconstructions guided deep to the LCL had a uniform length change pattern, whereas when placed superficial to the LCL behaviour was variable and highly dependent on the femoral attachment site. Thus, a Lemaire or MacIntosh reconstruction had preferable length change pattern, being tight in extension and slacken in flexion, implying a potent role in restraining the pivot-shift phenomenon, whereas a possible ALL reconstruction according to the anatomy described by

Claes et al (with the femoral attachment anterior to the lateral epicondyle) had a tensioning pattern less likely to effectively control the pivot.

7.2 Limitations

7.2.1 Knee specimens

The anatomical observations and the biomechanical studies in this thesis used elderly cadaveric specimens with a mean age of 71 years. Injuries and reconstructions of the ACL and anterolateral structures mostly occur in a younger population and structural properties of ligaments tend to decrease with age.¹⁷³ Thus, the elderly specimens used in this study might not represent the behaviour of the structures in younger adults typically affected by sports injuries. However, in the first set of experiments presented in chapter four comparison was made to the intact state and it is likely that differences in loads may be similar in proportion between young and older specimens. In the study presented in chapter six, the specimens were used only to anatomically place the pins, from which suture lengths between them was determined. Thus, the age of the specimens is likely to be irrelevant to this investigation.

7.2.2 Specimen dissection method and biomechanical testing

After publishing the paper “The role of the anterolateral structures and the ACL in controlling laxity of the intact and ACL-deficient knee” a letter to the editor was written by the “ALL” group led by Bertrand Sonnery-Cottet, questioning the dissection method used in this thesis. There would appear to be two different methods of viewing the anatomy and evaluating the biomechanics of the anterolateral side of the knee. One is where the structures are dissected from posterior to anterior as described by Dagett et al.²⁶ The other one, which was used in this thesis, dissected the anterolateral structures from anterior to posterior¹²¹. This may explain the difference of opinion as to the importance of the ALL as a restraint of tibial internal rotation laxity. This difference has arisen because of the differing methods of study, both anatomical and biomechanical. Anatomically, the

structure defined as the ALL complex in the figure 2.8 is bulkier than the relatively flimsy ALL which had been described at the time when the cutting study (chapter 4) started^{1,3}, which had no connection to the ITT. Some fibres seen here would have been defined as belonging to the deep capsulo-osseous layer of the ITT in this study, which were dissected them from the underlying ALL by separating the layers from proximal to distal, whereas the preparation in the figure was dissected from posterior to the ITT and left the distal attachment around the rim of the tibia.

Most of the biomechanical studies have been based on observations of changes of laxity when the ALL was cut (force-controlled mode), whereas our study moved the tibia by a fixed amount and measured the reduction of force and/or torque needed after a structure was cut (position or displacement controlled method). While changes of laxity are what are observed during clinical examination and are familiar to surgeons, it is the measurement of changes of load needed to displace the tibia which is necessary to discover the primary and secondary restraints. Use of that method found that the ITT resisted much more of the tibial internal rotation torque than the ALL.

Cutting the different anterolateral structures in chapter 4 did not relate to “real-world” injuries. In these, when sustaining an ACL rupture, the anterolateral structures may stretch or a combined injury to the deep ITT structures and the anterolateral knee capsule may occur. This, of course, cannot be imitated by complete resection of these structures.

7.2.3 Testing setup:

The biomechanical cutting study presented in chapter four used a highly precise robotic setup. The results in this study relate only to the passive stabilizing structures on the anterolateral aspect of the knee and the ACL. In vivo kinematics of the knee, however, strongly depend upon the dynamic restraints and proprioception, which was not tested in our experiments. Furthermore, in the robotic setup the knee could only be tested in specific flexion angles and a dynamic testing, like the pivot-

shift test, was not possible. In order to elicit the pivot shift phenomenon in the robot, four difference forces/torques (internal tibial rotation, valgus rotation, anterior tibial translation and knee flexion) have to be applied. Also, the ITT has to be loaded in order to reduce the lateral tibial plateau after it had been subluxed. In the current testing protocol a simulated pivot shift was tested, which only combined internal rotation and valgus torques. Several other robotic studies applied an additional anterior tibial force, which probably would have increased the influence of the ACL in this study. The methods used are well accepted for testing the restraints to tibiofemoral laxity and much of our present understanding of the mechanical roles of knee ligaments has come from the use of sequential cutting methods.

The second set of knees were tested in a muscle loading rig, which was previously designed for evaluating patellofemoral questions. In the experiment described in chapter 6.3.1 only the different parts of the quadriceps muscle and the ITT were loaded and the hamstrings muscles were ignored. Presumably, this would have made an impact in rotational control of the tibia and may have influenced the length changes. However, this rig was designed to simulate an open chain extension against gravity, where the hamstrings are elongated rather than actively contracting.

7.2.4 Measurement methods

An LVDT and an attached suture had previously been validated and showed an accuracy of 0.01 mm, which is beyond the accuracy of the reported results of 0.1 mm.⁵⁶ A suture was then used to measure the length changes. One problem was that the suture sometimes slid over bony irregularities and caused sudden length changes. A second limitation was that the suture was only able to follow the middle portion of the ligaments and reconstructions and were rerouted to the anterior portion (nearest to the LCL) of a reconstruction when guided deep to the LCL. Therefore,

a second suture has been taken to measure, for example, the anterior and posterior aspect of the ITT.

Robotic data were analyzed using a custom made Matlab script written by Hadi el Daou. The midpoint of the pot was taken as reference point and distances were measured using vectors. Forces and torques were measured using the universal force/moment sensor.

7.3 Future work

7.3.1 Robotic testing:

As already reported in chapter 4, after cutting the anterolateral structures and the ACL a large portion of the load was still restraining internal rotation. Therefore, the medial structures were cut. However, this was only done at 30° of flexion. Results from a position controlled robotic setup, when cutting the medial structures would be interesting and would determine the primary and secondary restraints to internal/external rotation on the medial side. Recently, Kim et al. looked at the knee position in an ACL rupture by overlapping the tibial and femoral bone bruise in MRI and found a mean flexion angle near full extension, 5° of valgus rotation, 15° of internal rotation and 22 mm of ATT. Based on these data a more realistic laboratory ACL injury could be created. Another interesting work would be to evaluate the dynamic restraints of the knee. This has already been done by Herbort et al.⁶⁸ and Kittl et al.⁸⁷ at the medial side, evaluating the restraining role of the Semitendinosus/gracilis tendon and the Semimembranosus. Further work should focus on the impact of muscular control and the dynamic restraints of the knee, which unfortunately have been widely ignored so far.

Robotic testing in our setup only evaluated the static restraints of the anterolateral side. A dynamic robotic testing would be capable of eliciting the clinical pivot shift test, which would further add to our knowledge of ALRI. A future work would then comprise a non-contact simulated ACL injury model, which could then determine additional injuries to the anterolateral/medial side by adjusting the magnitude and rate of loading.

7.3.2 Clinical trials

It is pertinent to translate the in-vitro studies into the clinical setting. Sonnery-Cottet et al.¹⁵¹ already showed in a large cohort study that the re-rupture rate can be lowered by using an additional extra-articular lateral reconstruction in an ACL deficient knee. However, this study setup suffered from all the limitations of a retrospective study. Just recently, Getgood et al.⁵⁴ conducted a prospective randomized clinical trial comparing single bundle ACL reconstruction with or without lateral extra-articular reconstruction. They demonstrated a reduction in ACL graft ruptures from 11% to 4%, when using a modified Lemaire technique (similar to the one described in chapter 5.4.2), routed deep to the LCL, based on some of the work in this thesis.

Recommended indications for an additional lateral procedure have been described in the results from the International anterolateral complex consensus group meeting.⁵³ These included revision ACL reconstruction, high-grade pivot-shift test, generalised ligamentous laxity/genu recurvatum, and young patients returning to pivoting activities. However, long term results are still missing and historical doubts regarding over-constraint of the lateral compartment still exist, especially in knees with prior lateral meniscectomy and valgus malalignment.

7.4 Recommendations to surgeons

This thesis leads to some suggested surgical recommendations. These could help form the basis of further randomised controlled trials.

Based on the anatomical observations and length change measurements presented in this thesis, the ITT was shown to exhibit different length change behaviour. The anterior part increased in length in knee flexion, whereas the posterior part increased in length in knee extension. Additionally, in the anatomical dissections of this thesis the capsulo-osseous layer was found deep to the posterior part of the ITT. Thus, when performing a lateral extra-articular reconstruction a strip of the anterior part of the ITT would prevent injury to the capsulo-osseous layer of the ITT, when harvesting the strip. This capsulo-osseous layer was also found to be one of the major restraints to internal tibial rotation and should therefore be protected.

Another aim of this thesis was to investigate the effect on length changes when guiding the lateral tenodesis deep or superficial to the LCL. Results showed a much higher variability of length change pattern when guiding the graft superficial to the LCL. Due to the pulley effect of the lateral epicondyle, which retained the graft posterior to the flexion-extension axis, length change patterns were favourable for restraining the pivot-shift test, when guiding the strip of the ITT deep to the LCL. Furthermore, a femoral insertion site proximal to the lateral epicondyle (when guided deep to the LCL) has shown high grade of isometry and increase in length in knee extension. Thus, guiding the graft deep to the LCL and fixing it proximal to the lateral epicondyle in the safe area described in this thesis, may effectively restrain the pivot-shift test.

8 References

1. Amis AA, Bull AM, Lie DT. Biomechanics of rotational instability and anatomic anterior cruciate ligament reconstruction. *Oper Tech Orthop.* 2005;15(1):29-35.
2. Amis AA, Dawkins GP. Functional anatomy of the anterior cruciate ligament. Fibre bundle actions related to ligament replacements and injuries. *J Bone Joint Surg Br.* 1991;73(2):260-267.
3. Amis AA, Jakob RP. Anterior cruciate ligament graft positioning, tensioning and twisting. *Knee Surg Sports Traumatol Arthrosc.* 1998;6(1):S2-S12.
4. Amis AA, Scammell BE. Biomechanics of intra-articular and extra-articular reconstruction of the anterior cruciate ligament. *J Bone Joint Surg Br.* 1993;75(5):812-817.
5. Amis AA, Zavras TD. Isometricity and graft placement during anterior cruciate ligament reconstruction. *The Knee.* 1995;2(1):5-17.
6. Andersen H, Dyhre-Poulsen P. The anterior cruciate ligament does play a role in controlling axial rotation in the knee. *Knee Surg Sports Traumatol Arthrosc.* 1997;5(3):145-149.
7. Andrews JR, Sanders R. A "mini-reconstruction" technique in treating anterolateral rotatory instability (ALRI). *Clin Orthop Relat Res.* 1983(172):93-96.
8. Andriacchi TP, Dyrby CO. Interactions between kinematics and loading during walking for the normal and ACL deficient knee. *J Biomech.* 2005;38(2):293-298.
9. Ardern CL, Webster KE, Taylor NF, Feller JA. Return to sport following anterior cruciate ligament reconstruction surgery: a systematic review and meta-analysis of the state of play. *Br J Sports Med.* 2011;45(7):596-606.
10. Athwal K. Assessing the contributions of soft tissue to the stability of total knee replacements. *A thesis for the degree of PhD and Diploma of Imperial College London.* 2016.
11. Barrett G, Richardson K. The effect of added extra-articular procedure on results of ACL reconstruction. *Am J Knee Surg.* 1994;8:1-6.
12. Bartel D, Marshall J, Schieck R, Wang J. Surgical repositioning of the medial collateral ligament. An anatomical and mechanical analysis. *J Bone Joint Surg Am.* 1977;59(1):107-116.
13. Bedi A, Musahl V, Lane C, et al. Lateral compartment translation predicts the grade of pivot shift: a cadaveric and clinical analysis. *Knee Surg Sports Traumatol Arthrosc.* 2010;18(9):1269-1276.

14. Bignozzi S, Zaffagnini S, Lopomo N, et al. Does a lateral plasty control coupled translation during antero-posterior stress in single-bundle ACL reconstruction? An in vivo study. *Knee Surg Sports Traumatol Arthrosc.* 2009;17(1):65-70.
15. Birnbaum K, Siebert C, Pandorf T, et al. Anatomical and biomechanical investigations of the iliotibial tract. *Surg Radiol Anat.* 2004;26(6):433-446.
16. Birrer S. The popliteus tendon and its fascicles at the popliteal hiatus: gross anatomy and functional arthroscopic evaluation with and without anterior cruciate ligament deficiency. *Arthroscopy.* 1990;6(3):209-220.
17. Bourke HE, Salmon LJ, Waller A, Patterson V, Pinczewski LA. Survival of the anterior cruciate ligament graft and the contralateral ACL at a minimum of 15 years. *Am J Sports Med.* 2012;40(9):1985-1992.
18. Bull AM, Andersen HN, Basso O, Targett J, Amis AA. Incidence and Mechanism of the Pivot Shift: An In Vitro Study. *Clin Orthop Relat Res.* 1999;363:219-231.
19. Butler DL, Noyes FR, Grood ES. Ligamentous restraints to anterior-posterior drawer in the human knee. A biomechanical study. *J Bone Joint Surg Am.* 1980;62(2):259-270.
20. Carson WG, Jr. Extra-articular reconstruction of the anterior cruciate ligament: lateral procedures. *The Orthopedic clinics of North America.* 1985;16:191-211.
21. Caterine S, Litchfield R, Johnson M, Chronik B, Getgood A. A cadaveric study of the anterolateral ligament: re-introducing the lateral capsular ligament. *Knee Surg Sports Traumatol Arthrosc.* 2015;23(11):3186-3195.
22. Claes S, Vereecke E, Maes M, et al. Anatomy of the anterolateral ligament of the knee. *J Anat.* 2013;223:321-328.
23. Clary CW, Wyss JG, Wright AP, et al. Management of MCL Tension in Deep Flexion: Influence of Implant Shape. *ORS.* 2012;Poster #1990.
24. Cohn AK, Mains DB. Popliteal hiatus of the lateral meniscus: anatomy and measurement at dissection of 10 specimens. *Am J Sports Med.* 1979;7(4):221-226.
25. Colombet PD. Navigated intra-articular ACL reconstruction with additional extra-articular tenodesis using the same hamstring graft. *Knee Surg Sports Traumatol Arthrosc.* 2011;19(3):384-389.

26. Daggett M, Busch K, Sonnery-Cottet B. Surgical dissection of the anterolateral ligament. *Arthroscopy techniques*. 2016;5(1):e185-e188.
27. Daggett M, Claes S, Helito CP, et al. The Role of the Anterolateral Structures and the ACL in Controlling Laxity of the Intact and ACL-Deficient Knee: Letter to the Editor. *Am J Sports Med*. 2016;44(4):NP14-NP15.
28. Daggett M, Ockuly AC, Cullen M, et al. Femoral origin of the anterolateral ligament: an anatomic analysis. *Arthroscopy*. 2015.
29. Dahlstedt LJ, Dalén N, Jonsson U. Extraarticular repair of the unstable knee: Disappointing 6-year results of the Slocum and Ellison operations. *Acta Orthop*. 1988;59:687–691.
30. Daniel DM, Stone ML, Sachs R, Malcom L. Instrumented measurement of anterior knee laxity in patients with acute anterior cruciate ligament disruption. *Am J Sports Med*. 1985;13(6):401-407.
31. Davis DS, Post WR. Segond fracture: lateral capsular ligament avulsion. *J Orthop Sports Phys Ther*. 1997;25(2):103-106.
32. Diermann N, Schumacher T, Schanz S, et al. Rotational instability of the knee: internal tibial rotation under a simulated pivot shift test. *Arch Orthop Trauma Surg*. 2009;129:353-358.
33. Dodds A, Halewood C, Gupte C, Williams A, Amis A. The anterolateral ligament: anatomy, length changes and association with the Segond fracture. *Bone Joint J*. 2014;96(3):325-331.
34. Dodds AL, Gupte CM, Neyret P, Williams AM, Amis AA. Extra-articular techniques in anterior cruciate ligament reconstruction a literature review. *J Bone Joint Surg Br*. 2011;93-B:1440-1448.
35. Donaldson WF, Warren RF, Wickiewicz T. A comparison of acute anterior cruciate ligament examinations: Initial versus examination under anesthesia. *Am J Sports Med*. 1985;13(1):5-10.
36. Draganich LF, Hsieh Y-F, Reider B. Iliotibial Band Tenodesis: A New Strategy for Attachment. *Am J Sports Med*. 1995;23:186-195.
37. Draganich LF, Reider B, Ling M, Samuelson M. An in vitro study of an intraarticular and extraarticular reconstruction in the anterior cruciate ligament deficient knee. *Am J Sports Med*. 1990;18:262-266.

38. Draganich LF, Reider B, Miller PR. An in vitro study of the Müller anterolateral femorotibial ligament tenodesis in the anterior cruciate ligament deficient knee. *Am J Sports Med.* 1989;17:357-362.
39. Ellison A. Distal iliotibial-band transfer for anterolateral rotatory instability of the knee. *J Bone Joint Surg Am.* 1979;61(3):330-337.
40. Ellison AE. The pathogenesis and treatment of anterolateral rotatory instability. *Clin Orthop Relat Res.* 1980(147):51-55.
41. Engebretsen L, Lew WD, Lewis JL, Hunter RE. The effect of an iliotibial tenodesis on intraarticular graft forces and knee joint motion. *Am J Sports Med.* 1990;18(2):169-176.
42. Engebretsen L, Lew WD, Lewis JL, Hunter RE, Benum Pa. Anterolateral rotatory instability of the knee: cadaver study of extraarticular patellar-tendon transposition. *Acta Orthop.* 1990;61:225–230.
43. Fairclough J, Hayashi K, Toumi H, et al. The functional anatomy of the iliotibial band during flexion and extension of the knee: implications for understanding iliotibial band syndrome. *J Anat.* 2006;208(3):309-316.
44. Farahmand F, Sejiavongse W, Amis AA. Quantitative study of the quadriceps muscles and trochlear groove geometry related to instability of the patellofemoral joint. *J Orthop Res.* 1998;16(1):136-143.
45. Fardin PBA, Lizardo JHdF, Baptista JdS. Study of the anterolateral ligament of the knee in formalin-embedded cadavers. *Acta Ortop Bras.* 2017;25(2):89-92.
46. Ferretti A. Extra-articular reconstruction in the anterior cruciate ligament deficient knee: a commentary. *Joints.* 2014;2(1):41.
47. Fleming RE, Jr., Blatz DJ, McCarroll JR. Lateral reconstruction for anterolateral rotatory instability of the knee. *Am J Sports Med.* 1983;11(5):303-307.
48. Freedman KB, D'Amato MJ, Nedeff DD, Kaz A, Bach BR, Jr. Arthroscopic anterior cruciate ligament reconstruction: a metaanalysis comparing patellar tendon and hamstring tendon autografts. *Am J Sports Med.* 2003;31(1):2-11.
49. Fritschy D, Freuler C. Extraartikuläre laterale Bandplastiken. In: *Kniegelenk und Kreuzbänder.* Springer; 1990:428-435.

50. Fujie H, Mabuchi K, Woo SL-Y, et al. The use of robotics technology to study human joint kinematics: a new methodology. *J Biomech Eng.* 1993;115(3):211-217.
51. Galway HR, MacIntosh DL. The lateral pivot shift: a symptom and sign of anterior cruciate ligament insufficiency. *Clin Orthop Relat Res.* 1980:45-50.
52. Garcia R, Jr, Brunet ME, Timon S, Barrack RL. Lateral extra-articular knee reconstruction: long-term patient outcome and satisfaction. *J South Orthop Assoc.* 2000;9:19-23.
53. Getgood A, Brown C, Lording T, et al. The anterolateral complex of the knee: results from the International ALC Consensus Group Meeting. *Knee Surg Sports Traumatol Arthrosc.* 2018:1-11.
54. Getgood AMJ, Bryant DM, Litchfield R, et al. Lateral Extra-articular Tenodesis Reduces Failure of Hamstring Tendon Autograft Anterior Cruciate Ligament Reconstruction: 2-Year Outcomes From the STABILITY Study Randomized Clinical Trial. *Am J Sports Med.* 2020;48(2):285-297.
55. Ghosh KM. The effects of total knee replacement on the extensor retinaculum of the knee. A thesis for the degree of MD(Res) and Diploma of Imperial College London. 2009.
56. Ghosh KM, Merican AM, Iranpour-Boroujeni F, Deehan DJ, Amis AA. Length change patterns of the extensor retinaculum and the effect of total knee replacement. *J Orthop Res.* 2009;27:865–870.
57. Godin JA, Chahla J, Moatshe G, et al. A comprehensive reanalysis of the distal iliotibial band: quantitative anatomy, radiographic markers, and biomechanical properties. *Am J Sports Med.* 2017;45(11):2595-2603.
58. Goldman A, Pavlov H, Rubenstein D. The Segond fracture of the proximal tibia: a small avulsion that reflects major ligamentous damage. *Am J Roentgenol.* 1988;151(6):1163-1167.
59. Grood ES, Suntay WJ, Noyes FR, Butler D. Biomechanics of the knee-extension exercise. Effect of cutting the anterior cruciate ligament. *J Bone Joint Surg Am.* 1984;66(5):725-734.
60. Group M. Descriptive epidemiology of the Multicenter ACL Revision Study (MARS) cohort. *Am J Sports Med.* 2010;38(10):1979-1986.
61. Gupte C, Smith A, McDermott I, et al. Menisofemoral ligaments revisited: anatomical study, age correlation and clinical implications. *J Bone Joint Surg Br.* 2002;84(6):846-851.

62. Harner CD, Giffin JR, Dunteman RC, Annunziata CC, Friedman MJ. Evaluation and treatment of recurrent instability after anterior cruciate ligament reconstruction. *Instr Course Lect.* 2001;50:463-474.
63. Harner CD, Honkamp NJ, Ranawat AS. Anteromedial portal technique for creating the anterior cruciate ligament femoral tunnel. *Arthroscopy.* 2008;24(1):113-115.
64. Hassler H, Jakob R. Ein Beitrag zur Ursache der anterolateralen Instabilität des Kniegelenkes. *Arch Orthop Trauma Surg.* 1981;98(1):45-50.
65. Hefti E, Müller W, Jakob R, Stäubli H-U. Evaluation of knee ligament injuries with the IKDC form. *Knee Surg Sports Traumatol Arthrosc.* 1993;1(3-4):226-234.
66. Hefzy M, Grood E. Sensitivity of insertion locations on length patterns of anterior cruciate ligament fibers. *J Biomech Eng.* 1986;108(1):73-82.
67. Helito CP, Demange MK, Bonadio MB, et al. Anatomy and histology of the knee anterolateral ligament. *Orthop J Sports Med.* 2013;1(7):2325967113513546.
68. Herbort M, Michel P, Raschke MJ, et al. Should the ipsilateral hamstrings be used for anterior cruciate ligament reconstruction in the case of medial collateral ligament insufficiency? Biomechanical investigation regarding dynamic stabilization of the medial compartment by the hamstring muscles. *Am J Sports Med.* 2017;45(4):819-825.
69. Herbst E, Hoser C, Tecklenburg K, et al. The lateral femoral notch sign following ACL injury: frequency, morphology and relation to meniscal injury and sports activity. *Knee Surg Sports Traumatol Arthrosc.* 2015;23(8):2250-2258.
70. Hewison CE, Tran MN, Kaniki N, et al. Lateral extra-articular tenodesis reduces rotational laxity when combined with anterior cruciate ligament reconstruction: a systematic review of the literature. *Arthroscopy.* 2015;31(10):2022-2034.
71. Hughston JC, Andrews JR, Cross MJ, Moschi A. Classification of knee ligament instabilities. Part II. The lateral compartment. *J Bone Joint Surg Am.* 1976;58(2):173-179.
72. Imhauser C, Mauro C, Choi D, et al. Abnormal tibiofemoral contact stress and its association with altered kinematics after center-center anterior cruciate ligament reconstruction: an in vitro study. *Am J Sports Med.* 2013;41(4):815-825.

73. Inderhaug E, Stephen JM, El-Daou H, Williams A, Amis AA. The effects of anterolateral tenodesis on tibiofemoral contact pressures and kinematics. *Am J Sports Med.* 2017;45(13):3081-3088.
74. Inderhaug E, Stephen JM, Williams A, Amis AA. Anterolateral tenodesis or anterolateral ligament complex reconstruction: effect of flexion angle at graft fixation when combined with ACL reconstruction. *Am J Sports Med.* 2017;45(13):3089-3097.
75. Inderhaug E, Stephen JM, Williams A, Amis AA. Biomechanical comparison of anterolateral procedures combined with anterior cruciate ligament reconstruction. *Am J Sports Med.* 2017;45(2):347-354.
76. Ireland J, Trickey E. Macintosh tenodesis for anterolateral instability of the knee. *The Journal of bone and joint surgery British volume.* 1980;62(3):340-345.
77. Jakob RP, Staubli HU, Deland JT. Grading the pivot shift. Objective tests with implications for treatment. *J Bone Joint Surg Br.* 1987;69(2):294-299.
78. Jaureguito JW, Paulos LE. Why grafts fail. *Clin Orthop Relat Res.* 1996(325):25-41.
79. Johannsen AM, Civitarese DM, Padalecki JR, et al. Qualitative and quantitative anatomic analysis of the posterior root attachments of the medial and lateral menisci. *Am J Sports Med.* 2012;40(10):2342-2347.
80. Johnson DL, Swenson TM, Livesay GA, et al. Insertion-site anatomy of the human menisci: gross, arthroscopic, and topographical anatomy as a basis for meniscal transplantation. *Arthroscopy.* 1995;11(4):386-394.
81. Johnson LL. Lateral capsular ligament complex: anatomical and surgical considerations. *Am J Sports Med.* 1979;7(3):156-160.
82. Kaeding CC, Pedroza AD, Reinke EK, et al. Risk factors and predictors of subsequent ACL injury in either knee after ACL reconstruction: prospective analysis of 2488 primary ACL reconstructions from the MOON cohort. *Am J Sports Med.* 2015;43(7):1583-1590.
83. Kanamori A, Woo SL, Ma CB, et al. The forces in the anterior cruciate ligament and knee kinematics during a simulated pivot shift test: a human cadaveric study using robotic technology. *Arthroscopy.* 2000;16(6):633-639.
84. Kaplan EB. The iliotibial tract; clinical and morphological significance. *J Bone Joint Surg Am.* 1958;40-A(4):817-832.

85. Kennedy J, Stewart R, Walker DM. Anterolateral rotatory instability of the knee joint. An early analysis of the Ellison procedure. *J Bone Joint Surg Am.* 1978;60(8):1031-1039.
86. Kennedy MI, Claes S, Fuso FAF, et al. The anterolateral ligament: an anatomic, radiographic, and biomechanical analysis. *Am J Sports Med.* 2015;43(7):1606-1615.
87. Kittl C, Becker DK, Raschke MJ, et al. Dynamic Restraints of the Medial Side of the Knee: The Semimembranosus Corner Revisited. *Am J Sports Med.* 2019;47(4):863-869.
88. Kittl C, El-Daou H, Athwal KK, et al. The Role of the Anterolateral Structures and the ACL in Controlling Laxity of the Intact and ACL-Deficient Knee. *Am J Sports Med.* 2015.
89. Kittl C, Halewood C, Stephen JM, et al. Length change patterns in the lateral extra-articular structures of the knee and related reconstructions. *Am J Sports Med.* 2015;43(2):354-362.
90. Kittl C, Weiler A, Amis A. Anterolaterale Rotationsinstabilität. *Arthroskopie.* 2014;27(3):170-176.
91. Kondo E, Merican AM, Yasuda K, Amis AA. Biomechanical comparison of anatomic double-bundle, anatomic single-bundle, and nonanatomic single-bundle anterior cruciate ligament reconstructions. *Am J Sports Med.* 2011;39(2):279-288.
92. Krackow KA, Brooks RL. Optimization of knee ligament position for lateral extraarticular reconstruction. *Am J Sports Med.* 1983;11:293-302.
93. Kurosawa H, Yasuda K, Yamakoshi K-I, Kamiya A, Kaneda K. An experimental evaluation of isometric placement for extraarticular reconstructions of the anterior cruciate ligament. *Am J Sports Med.* 1991;19:384-388.
94. Lane JG, Irby SE, Kaufman K, Rangger C, Daniel DM. The anterior cruciate ligament in controlling axial rotation. An evaluation of its effect. *Am J Sports Med.* 1994;22(2):289-293.
95. LaPrade RF. *Posterolateral knee injuries: anatomy, evaluation, and treatment.* Thieme; 2006.
96. LaPrade RF, Gilbert TJ, Bollom TS, Wentorf F, Chaljub G. The magnetic resonance imaging appearance of individual structures of the posterolateral knee - A prospective study of normal knees and knees with surgically verified grade III injuries. *Am J Sports Med.* 2000;28(2):191-199.

97. LaPrade RF, Resig S, Wentorf F, Lewis JL. The effects of grade III posterolateral knee complex injuries on anterior cruciate ligament graft force. A biomechanical analysis. *Am J Sports Med.* 1999;27(4):469-475.
98. Larsen E, Blyme P, Hede A. Pes anserinus and iliotibial band transfer for anterior cruciate insufficiency. *Am J Sports Med.* 1991;19:601-604.
99. Last RJ. Some anatomical details of the knee joint. *J Bone Joint Surg Br.* 1948;30(4):683-688.
100. Lemaire M. Ruptures anciennes du ligament croise anterieur du genou. *J Chir.* 1967;93(3):311-320.
101. Lemaire M, Combelles F. Technique actuelle de plastie ligamentaire pour rupture ancienne du ligament croisé antérieur. *Rev Chir Orthop.* 1980;66:523-525.
102. Lerat JL, Chotel F, Besse JL, et al. [The results after 10-16 years of the treatment of chronic anterior laxity of the knee using reconstruction of the anterior cruciate ligament with a patellar tendon graft combined with an external extra-articular reconstruction]. *Rev Chir Orthop Reparatrice Appar Mot.* 1998;84:712-727.
103. Lewis JL. Maximum unloaded length (MUL) and graft force as criteria for anterior cruciate ligament graft fixation. *Knee Surg Sports Traumatol Arthrosc.* 1998;6:S25-S29.
104. Lie DT, Bull AM, Amis AA. Persistence of the mini pivot shift after anatomically placed anterior cruciate ligament reconstruction. *Clin Orthop Relat Res.* 2007;457:203-209.
105. Lind M, Menhert F, Pedersen AB. Incidence and outcome after revision anterior cruciate ligament reconstruction: results from the Danish registry for knee ligament reconstructions. *Am J Sports Med.* 2012;40(7):1551-1557.
106. Lipke JM, Janecki CJ, Nelson CL, et al. The role of incompetence of the anterior cruciate and lateral ligaments in anterolateral and anteromedial instability. A biomechanical study of cadaver knees. *J Bone Joint Surg Am.* 1981;63(6):954-960.
107. Lobenhoffer P, Biedert R, Stauffer E, et al. Occurrence and distribution of free nerve endings in the distal iliotibial tract system of the knee. *Knee Surg Sports Traumatol Arthrosc.* 1996;4(2):111-115.
108. Lobenhoffer P, Posel P, Witt S, Piehler J, Wirth CJ. Distal femoral fixation of the iliotibial tract. *Arch Orthop Trauma Surg.* 1987;106:285-290.

109. Lord B, Amis AA. The envelope of laxity of the pivot shift test. In: *Rotatory Knee Instability*. Springer; 2017:223-234.
110. Losee R, Johnson T, Southwick W. Anterior subluxation of the lateral tibial plateau. A diagnostic test and operative repair. *J Bone Joint Surg Am*. 1978;60:1015-1030.
111. M. Dageff CH, B. Sonnery-Cottet. The Anterolateral Ligament Exists, Now What? Part 1 of 2. <https://www.umedicom/video/the-anterolateral-ligament-exists-now-what-part-1-of-2/>. 2016.
112. MacIntosh D, Darby T. Lateral substitution reconstruction. *Proceedings of the Canadian Orthopaedic Association J Bone Joint Surg Br*. 1976;58:142.
113. Mannel H, Marin F, Claes L, Dürselen L. Anterior cruciate ligament rupture translates the axes of motion within the knee. *Clin Biomech (Bristol, Avon)*. 2004;19(2):130-135.
114. Marcacci M, Zaffagnini S, Iacono F, et al. Arthroscopic intra- and extra-articular anterior cruciate ligament reconstruction with gracilis and semitendinosus tendons. *Knee Surg Sports Traumatol Arthrosc*. 1998;6:68-75.
115. Markolf KL, Park S, Jackson SR, McAllister DR. Anterior-posterior and rotatory stability of single and double-bundle anterior cruciate ligament reconstructions. *J Bone Joint Surg Am*. 2009;91(1):107-118.
116. Martin RB, Burr DB, Sharkey NA, Fyhrie DP. *Skeletal tissue mechanics*. Vol 190: Springer; 1998.
117. Matsumoto H. Mechanism of the pivot shift. *J Bone Joint Surg Br*. 1990;72-B:816-821.
118. Matsumoto H, Seedhom B. Treatment of the Pivot-Shift Intraarticular Versus Extraarticular or Combined Reconstruction Procedures A Biomechanical Study. *Clin Orthop Relat Res*. 1994;299:298-304.
119. Monaco E, Ferretti A, Labianca L, et al. Navigated knee kinematics after cutting of the ACL and its secondary restraint. *Knee Surg Sports Traumatol Arthrosc*. 2012;20:870-877.
120. Monaco E, Labianca L, Conteduca F, Carli AD, Ferretti A. Double bundle or single bundle plus extraarticular tenodesis in ACL reconstruction? *Knee Surg Sports Traumatol Arthrosc*. 2007;15:1168-1174.
121. Müller W. *Anatomy of the knee*. ESSKA DVD; 2006.

122. Müller W. *Das Knie: Form, Funktion und ligamentäre Wiederherstellungschirurgie*. Springer-Verlag; 2013.
123. Neyret P, Palomo J, Donell S, Dejour H. Extra-articular tenodesis for anterior cruciate ligament rupture in amateur skiers. *Br J Sports Med*. 1994;28(1):31-34.
124. Noyes F, Butler D, Grood E, Zernicke R, Hefzy M. Biomechanical analysis of human ligament grafts used in knee-ligament. *J Bone Joint Surg Am*. 1984;66:344-352.
125. Noyes FR, Barber SD. The effect of an extra-articular procedure on allograft reconstructions for chronic ruptures of the anterior cruciate ligament. *J Bone Joint Surg Am*. 1991;73:882-892.
126. Noyes FR, Grood ES, Butler DL, Paulos LE. Clinical biomechanics of the knee: ligament restraints and functional stability. *AAOS Symposium on the Athlete's Knee*. 1980:1-35.
127. Noyes FR, Grood ES, Cummings JF, Wroble RR. An analysis of the pivot shift phenomenon. The knee motions and subluxations induced by different examiners. *Am J Sports Med*. 1991;19(2):148-155.
128. O'Brien SJ, Warren RF, Wickiewicz TL, et al. The iliotibial band lateral sling procedure and its effect on the results of anterior cruciate ligament reconstruction. *Am J Sports Med*. 1991;19:21-25.
129. O'Meara PM, O'Brien WR, Henning CE. Anterior cruciate ligament reconstruction stability with continuous passive motion. The role of isometric graft placement. *Clin Orthop Relat Res*. 1992(277):201-209.
130. Oh YK, Kreinbrink JL, Ashton-Miller JA, Wojtys EM. Effect of ACL Transection on Internal Tibial Rotation in an in Vitro Simulated Pivot Landing. *J Bone Joint Surg Am*. 2011;93:372-380.
131. Olsen O-E, Myklebust G, Engebretsen L, Bahr R. Injury mechanisms for anterior cruciate ligament injuries in team handball a systematic video analysis. *Am J Sports Med*. 2004;32(4):1002-1012.
132. Parsons EM, Gee AO, Spiekerman C, Cavanagh PR. The biomechanical function of the anterolateral ligament of the knee. *Am J Sports Med*. 2015;43(3):669-674.
133. Paterno MV, Rauh MJ, Schmitt LC, Ford KR, Hewett TE. Incidence of contralateral and ipsilateral anterior cruciate ligament (ACL) injury after primary ACL reconstruction and return to sport. *Clin J Sport Med*. 2012;22(2):116.

134. Penner DA, Daniel DM, Wood P, Mishra D. An in vitro study of anterior cruciate ligament graft placement and isometry. *Am J Sports Med.* 1988;16(3):238-243.
135. Rahnama-Azar AA, Miller RM, Guenther D, et al. Structural properties of the anterolateral capsule and iliotibial band of the knee. *Am J Sports Med.* 2016;44(4):892-897.
136. Reid J, Hanks G, Kalenak A, Kottmeier S, Aronoff V. The Ellison iliotibial-band transfer for a torn anterior cruciate ligament of the knee. Long-term follow-up. *J Bone Joint Surg Am.* 1992;74:1392-1402.
137. Reid JS, Van Slyke MA, Moulton MJ, Mann TA. Safe placement of proximal tibial transfixation wires with respect to intracapsular penetration. *J Orthop Trauma.* 2001;15(1):10-17.
138. Ristanis S, Stergiou N, Patras K, et al. Follow-up evaluation 2 years after ACL reconstruction with bone-patellar tendon-bone graft shows that excessive tibial rotation persists. *Clin J Sport Med.* 2006;16(2):111-116.
139. Robinson JR, Bull AM, Amis AA. Structural properties of the medial collateral ligament complex of the human knee. *J Biomech.* 2005;38(5):1067-1074.
140. Robinson JR, Bull AM, Thomas RR, Amis AA. The role of the medial collateral ligament and posteromedial capsule in controlling knee laxity. *Am J Sports Med.* 2006;34(11):1815-1823.
141. Roth J, Kennedy J, Lockstadt H, McCallum C, Cuning L. Intra-articular reconstruction of the anterior cruciate ligament with and without extra-articular supplementation by transfer of the biceps femoris tendon. *J Bone Joint Surg Am.* 1987;69:275-278.
142. Runer A, Birkmaier S, Pamminger M, et al. The anterolateral ligament of the knee: a dissection study. *The Knee.* 2016;23(1):8-12.
143. Sanchez AR, Sugalski MT, LaPrade RF. Anatomy and biomechanics of the lateral side of the knee. *Sports Med Arthrosc.* 2006;14(1):2-11.
144. Saragaglia D, Pison A, Refaie R. Lateral tenodesis combined with anterior cruciate ligament reconstruction using a unique semitendinosus and gracilis transplant. *Int Orthop.* 2013;37:1575-1581.
145. Seebacher JR, Inglis AE, Marshall JL, Warren RF. The structure of the posterolateral aspect of the knee. *J Bone Joint Surg Am.* 1982;64(4):536-541.

146. Segond P. *Recherches cliniques et experimentales sur les epanchements sanguins du genou par entorse*. Aux Bureaux du Progrès médical; 1879.
147. Shaikh H, Herbst E, Rahnama-Azar AA, et al. The Segond fracture is an avulsion of the anterolateral complex. *Am J Sports Med*. 2017;45(10):2247-2252.
148. Shelbourne KD, Gray T, Haro M. Incidence of subsequent injury to either knee within 5 years after anterior cruciate ligament reconstruction with patellar tendon autograft. *Am J Sports Med*. 2009;37(2):246-251.
149. Sidles JA, Larson RV, Garbini JL, Downey DJ, Matsen FA. Ligament length relationships in the moving knee. *J Orthop Res*. 1988;6:593–610.
150. Sonnery-Cottet B, Lutz C, Daggett M, et al. The Involvement of the Anterolateral Ligament in Rotational Control of the Knee. *Am J Sports Med*. 2016.
151. Sonnery-Cottet B, Saithna A, Cavalier M, et al. Anterolateral ligament reconstruction is associated with significantly reduced ACL graft rupture rates at a minimum follow-up of 2 years: a prospective comparative study of 502 patients from the SANTI study group. *Am J Sports Med*. 2017;45(7):1547-1557.
152. Sonnery-Cottet B, Thauinat M, Freychet B, et al. Outcome of a combined anterior cruciate ligament and anterolateral ligament reconstruction technique with a minimum 2-year follow-up. *Am J Sports Med*. 2015;43(7):1598-1605.
153. Spencer L, Burkhart TA, Tran MN, et al. Biomechanical analysis of simulated clinical testing and reconstruction of the anterolateral ligament of the knee. *Am J Sports Med*. 2015;43(9):2189-2197.
154. Sta H-U, Birrer S. The popliteus tendon and its fascicles at the popliteal hiatus: gross anatomy and functional arthroscopic evaluation with and without anterior cruciate ligament deficiency. *Arthroscopy*. 1990;6(3):209-220.
155. Stephen J. The biomechanics of the Medial Patellofemoral Ligament. A thesis for the degree of PhD and Diploma of Imperial College London. 2014.
156. Stephen JM, Lumpaopong P, Deehan DJ, Kader D, Amis AA. The Medial Patellofemoral Ligament Location of Femoral Attachment and Length Change Patterns Resulting From Anatomic and Nonanatomic Attachments. *Am J Sports Med*. 2012;40:1871-1879.

157. Stijak L, Bumbaširević M, Radonjić V, et al. Anatomic description of the anterolateral ligament of the knee. *Knee Surg Sports Traumatol Arthrosc.* 2016;24(7):2083-2088.
158. Strum GM, Fox JM, Ferkel RD, et al. Intraarticular versus intraarticular and extraarticular reconstruction for chronic anterior cruciate ligament instability. *Clin Orthop Relat Res.* 1989;245:188–198.
159. Suero EM, Njoku IU, Voigt MR, et al. The role of the iliotibial band during the pivot shift test. *Knee Surg Sports Traumatol Arthrosc.* 2013;21(9):2096-2100.
160. Tashman S, Collon D, Anderson K, Kolowich P, Anderst W. Abnormal rotational knee motion during running after anterior cruciate ligament reconstruction. *Am J Sports Med.* 2004;32(4):975-983.
161. Terry GC, Hughston JC, Norwood LA. The anatomy of the iliopatellar band and iliotibial tract. *Am J Sports Med.* 1986;14:39-45.
162. Terry GC, LaPrade RF. The biceps femoris muscle complex at the knee Its anatomy and injury patterns associated with acute anterolateral-anteromedial rotatory instability. *Am J Sports Med.* 1996;24(1):2-8.
163. Terry GC, LaPrade RF. The posterolateral aspect of the knee. Anatomy and surgical approach. *Am J Sports Med.* 1996;24(6):732-739.
164. Terry GC, Norwood LA, Hughston JC, Caldwell KM. How iliotibial tract injuries of the knee combine with acute anterior cruciate ligament tears to influence abnormal anterior tibial displacement. *Am J Sports Med.* 1993;21:55-60.
165. Trojani C, Beaufils P, Burdin G, et al. Revision ACL reconstruction: influence of a lateral tenodesis. *Knee Surg Sports Traumatol Arthrosc.* 2012;20:1565-1570.
166. Vadalà AP, Iorio R, Carli AD, et al. An extra-articular procedure improves the clinical outcome in anterior cruciate ligament reconstruction with hamstrings in female athletes. *Int Orthop.* 2013;37:187-192.
167. Vieira ELC, Vieira EÁ, Teixeira da Silva R, et al. An Anatomic Study of the Iliotibial Tract. *Arthroscopy.* 2007;23:269-274.
168. Vincent J-P, Magnussen RA, Gezmez F, et al. The anterolateral ligament of the human knee: an anatomic and histologic study. *Knee Surg Sports Traumatol Arthrosc.* 2012;20:147-152.

169. Wagner M, Kittl C, Weiler A. Anterolateral stabilization. Surgical technique. *Arthroskopie*. 2017;30(1):44-48.
170. Wagner M, Weiler A. Anterolaterale Stabilisierung. *Arthroskopie*. 2014;27(3):198-201.
171. Waldeyer AJ. *Waldeyer–Anatomie des Menschen*. Walter de Gruyter; 2011.
172. Webster KE, Feller JA, Leigh WB, Richmond AK. Younger patients are at increased risk for graft rupture and contralateral injury after anterior cruciate ligament reconstruction. *Am J Sports Med*. 2014;42(3):641-647.
173. Woo SL-Y, Hollis JM, Adams DJ, Lyon RM, Takai S. Tensile properties of the human femur-anterior cruciate ligament-tibia complex: the effects of specimen age and orientation. *Am J Sports Med*. 1991;19(3):217-225.
174. Wright RW, Magnussen RA, Dunn WR, Spindler KP. Ipsilateral graft and contralateral ACL rupture at five years or more following ACL reconstruction: a systematic review. *J Bone Joint Surg Am*. 2011;93(12):1159.
175. Wroble RR, Grood ES, Cummings JS, Henderson JM, Noyes FR. The role of the lateral extraarticular restraints in the anterior cruciate ligament-deficient knee. *Am J Sports Med*. 1993;21(2):257-262; discussion 263.
176. Yamamoto Y, Hsu WH, Fisk JA, et al. Effect of the iliotibial band on knee biomechanics during a simulated pivot shift test. *J Orthop Res*. 2006;24(5):967-973.
177. Zaffagnini S, Marcacci M, Presti ML, et al. Prospective and randomized evaluation of ACL reconstruction with three techniques: a clinical and radiographic evaluation at 5 years follow-up. *Knee Surg Sports Traumatol Arthrosc*. 2006;14:1060-1069.
178. Zantop T, Herbort M, Raschke MJ, Fu FH, Petersen W. The role of the anteromedial and posterolateral bundles of the anterior cruciate ligament in anterior tibial translation and internal rotation. *Am J Sports Med*. 2007;35(2):223-227.
179. Zantop T, Schumacher T, Diermann N, et al. Anterolateral rotational knee instability: role of posterolateral structures. *Arch Orthop Trauma Surg*. 2007;127(9):743-752.
180. Zarins B, Rowe C. Combined anterior cruciate-ligament reconstruction using semitendinosus tendon and iliotibial tract. *J Bone Joint Surg Am*. 1986;68:160-177.

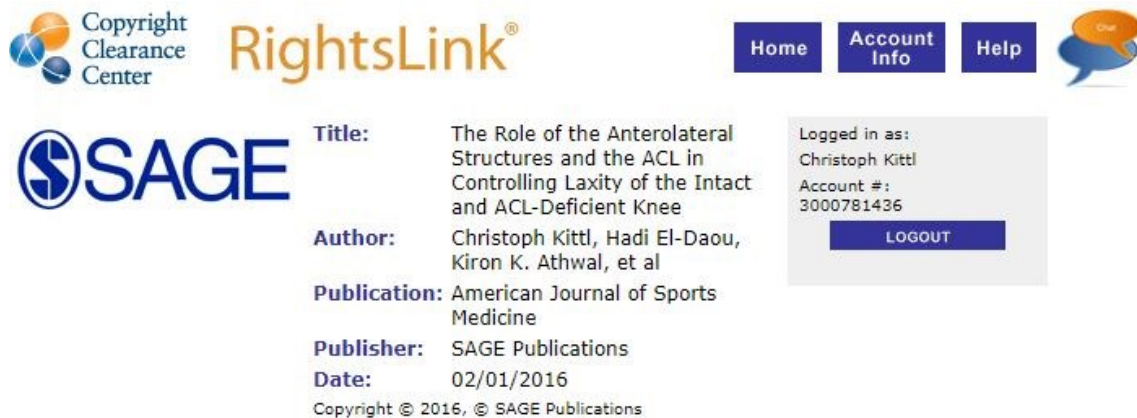
181. Zavras T, Race A, Bull A, Amis A. A comparative study of 'isometric' points for anterior cruciate ligament graft attachment. *Knee Surg Sports Traumatol Arthrosc.* 2001;9(1):28-33.
182. Zdanowicz U, Śmigielski R. Meniscus Anatomy. In: *The Menisci.* Springer; 2017:1-8.
183. Zens M, Feucht MJ, Ruhhammer J, et al. Mechanical tensile properties of the anterolateral ligament. *J Exp Orthop.* 2015;2(1):7.

9 Appendix

Permissions for previously published papers were attained from the Copyright Clearance Center from the corresponding publisher.

- I. The role of the anterolateral structures and the ACL in controlling laxity of the intact and ACL-deficient knee; The American Journal of Sports Medicine, Volume 44 , Number 2, pages: 345-354

C Kittl, H El-Daou, KK Athwal, CM Gupte, A Weiler, A Williams, AA Amis



The screenshot shows the RightsLink interface. At the top left is the Copyright Clearance Center logo. To its right is the RightsLink logo. Further right are navigation buttons for Home, Account Info, and Help, along with a chat icon. Below the logos is the SAGE logo. The main content area displays article details: Title: The Role of the Anterolateral Structures and the ACL in Controlling Laxity of the Intact and ACL-Deficient Knee; Author: Christoph Kittl, Hadi El-Daou, Kiron K. Athwal, et al; Publication: American Journal of Sports Medicine; Publisher: SAGE Publications; Date: 02/01/2016. A copyright notice at the bottom of this section reads 'Copyright © 2016, © SAGE Publications'. On the right side, a user information box shows 'Logged in as: Christoph Kittl' and 'Account #: 3000781436', with a LOGOUT button below.

Welcome to RightsLink

SAGE Publications has partnered with Copyright Clearance Center's RightsLink service to offer a variety of options for reusing SAGE Publications content.

I would like to...

Important Notice Regarding Content:

This RightsLink service only provides permission for reuse. You may purchase an article through our Pay-Per-View service by selecting the "Full-Text (PDF)" link from the Journal table of contents on [SAGE Journals](#) or refer to our [Full Text Access Options](#) page for more information.

Copyright © 2019 Copyright Clearance Center, Inc. All Rights Reserved. [Privacy statement](#). [Terms and Conditions](#).
Comments? We would like to hear from you. E-mail us at customercare@copyright.com

2. Length change patterns in the lateral extra-articular structures of the knee and related reconstructions; The American Journal of Sports Medicine, Volume 43, Number 2, pages: 354-362

C Kittl, C Halewood, JM Stephen, CM Gupte, A Weiler, A Williams, AA Amis



RightsLink®

Home

Account Info

Help



Title: Length Change Patterns in the Lateral Extra-articular Structures of the Knee and Related Reconstructions

Author: Cristoph Kittl, Camilla Halewood, Joanna M. Stephen, et al

Publication: American Journal of Sports Medicine

Publisher: SAGE Publications

Date: 02/01/2015

Copyright © 2015, © SAGE Publications

Logged in as:
Christoph Kittl
Account #:
3000781436

LOGOUT

If you are a SAGE journal author requesting permission to reuse material from your journal article, please note you may be able to reuse your content without requiring permission from SAGE. Please review SAGE's author re-use and archiving policies at <https://us.sagepub.com/en-us/nam/journal-author-archiving-policies-and-re-use> for more information.

If your request does not fall within SAGE's reuse guidelines, please proceed with submitting your request by selecting one of the other reuse categories that describes your use. Please note, a fee may be charged for reuse of content requiring permission. Please contact permissions@sagepub.com if you have questions.

BACK

CLOSE WINDOW

Copyright © 2019 Copyright Clearance Center, Inc. All Rights Reserved. [Privacy statement](#). [Terms and Conditions](#).
Comments? We would like to hear from you. E-mail us at customer-care@copyright.com

3. The role of the anterolateral structures and the ACL in controlling laxity of the intact and ACL-deficient knee: response; The American Journal of Sports Medicine, Volume 44, Number 4, pages: NPI5-NPI8
C Kittl, H El-Daou, KK Athwal, CM Gupte, A Weiler, A Williams, AA Amis



RightsLink®

Home

Account Info

Help



Title: The Role of the Anterolateral Structures and the ACL in Controlling Laxity of the Intact and ACL-Deficient Knee: Response

Author: Christoph Kittl, Hadi El-Daou, Kiron K. Athwal, et al

Publication: American Journal of Sports Medicine

Publisher: SAGE Publications

Date: 04/01/2016

Copyright © 2016, © SAGE Publications

Logged in as:
Christoph Kittl
Account #:
3000781436

LOGOUT

If you are a SAGE journal author requesting permission to reuse material from your journal article, please note you may be able to reuse your content without requiring permission from SAGE. Please review SAGE's author re-use and archiving policies at <https://us.sagepub.com/en-us/nam/journal-author-archiving-policies-and-re-use> for more information.

If your request does not fall within SAGE's reuse guidelines, please proceed with submitting your request by selecting one of the other reuse categories that describes your use. Please note, a fee may be charged for reuse of content requiring permission. Please contact permissions@sagepub.com if you have questions.

BACK

CLOSE WINDOW

Copyright © 2019 Copyright Clearance Center, Inc. All Rights Reserved. [Privacy statement](#). [Terms and Conditions](#). Comments? We would like to hear from you. E-mail us at customercare@copyright.com

4. Anterolaterale Rotationsinstabilität; Arthroskopie, Volume 27, Number 3, pages: 170-176

C Kittl, A Weiler, AA Amis



RightsLink®

Home

Account Info

Help



SPRINGER NATURE

Title: Anterolaterale Rotationsinstabilität
Author: C. Kittl, A. Weiler, A.A. Amis
Publication: Arthroskopie
Publisher: Springer Nature
Date: Jan 1, 2014
Copyright © 2014, Springer-Verlag Berlin Heidelberg

Logged in as:

Christoph Kittl

Account #: 3000781436

LOGOUT

Order Completed

Thank you for your order.

This Agreement between Christoph Kittl ("You") and Springer Nature ("Springer Nature") consists of your license details and the terms and conditions provided by Springer Nature and Copyright Clearance Center.

Your confirmation email will contain your order number for future reference.

[printable details](#)

License Number	4570020772394
License date	Apr 15, 2019
Licensed Content Publisher	Springer Nature
Licensed Content Publication	Arthroskopie
Licensed Content Title	Anterolaterale Rotationsinstabilität
Licensed Content Author	C. Kittl, A. Weiler, A.A. Amis
Licensed Content Date	Jan 1, 2014
Licensed Content Volume	27
Licensed Content Issue	3
Type of Use	Thesis/Dissertation
Requestor type	academic/university or research institute
Format	electronic
Portion	full article/chapter
Will you be translating?	yes, including original language
Number of languages	1
Circulation/distribution	<501
Author of this Springer Nature content	yes
Title	The anterolateral structures of the knee: Anatomy, biomechanics, and related reconstructions
Institution name	Imperial college London
Expected presentation date	Jun 2019
Specific Languages	english
Requestor Location	Christoph Kittl Melrose Gardens, Melrose House, Penthouse London, W6 7RW United Kingdom Attn: Christoph Kittl
Total	0.00 EUR

ORDER MORE

CLOSE WINDOW

Copyright © 2019 Copyright Clearance Center, Inc. All Rights Reserved. [Privacy statement](#). [Terms and Conditions](#).
Comments? We would like to hear from you. E-mail us at customercare@copyright.com

5. Biomechanics of the anterolateral structures of the knee; Clinics in Sports Medicine, Volume 37, Number 1, pages: 21-31

C Kittl, E Inderhaug, A Williams, AA Amis

HomeAccount InfoHelp



Title: Biomechanics of the Anterolateral Structures of the Knee
Author: Christoph Kittl, Eivind Inderhaug, Andy Williams, Andrew A. Amis
Publication: Sports Medicine Clinics
Publisher: Elsevier
Date: January 2018
© 2017 Elsevier Inc. All rights reserved.

Logged in as:
Christoph Kittl
Account #: 3000781436
[LOGOUT](#)

Please note that, as the author of this Elsevier article, you retain the right to include it in a thesis or dissertation, provided it is not published commercially. Permission is not required, but please ensure that you reference the journal as the original source. For more information on this and on your other retained rights, please visit: <https://www.elsevier.com/about/our-business/policies/copyright#Author-rights>

BACKCLOSE WINDOW

Copyright © 2019 Copyright Clearance Center, Inc. All Rights Reserved. [Privacy statement](#), [Terms and Conditions](#).
Comments? We would like to hear from you. E-mail us at customercare@copyright.com

6. Biomechanical Role of Lateral Structures in Controlling Anterolateral Rotatory Laxity: The Iliotibial Tract; Operative Techniques in Orthopaedics, Volume 27, Number 2, pages: 96-101
C Kittl, A Williams, AA Amis

 **Copyright Clearance Center**  **RightsLink®**  **Home**  **Account Info**  **Help** 

 **Title:** Biomechanical Role of Lateral Structures in Controlling Anterolateral Rotatory Laxity: The Iliotibial Tract
Author: Christoph Kittl, Andy Williams, Andrew A. Amis
Publication: Operative Techniques in Orthopaedics
Publisher: Elsevier
Date: June 2017
© 2017 Elsevier Inc. All rights reserved.

Logged in as:
Christoph Kittl
Account #: 3000781436
 **LOGOUT**

Please note that, as the author of this Elsevier article, you retain the right to include it in a thesis or dissertation, provided it is not published commercially. Permission is not required, but please ensure that you reference the journal as the original source. For more information on this and on your other retained rights, please visit: <https://www.elsevier.com/about/our-business/policies/copyright#Author-rights>

 **BACK**




 **CLOSE WINDOW**


Copyright © 2019 Copyright Clearance Center, Inc. All Rights Reserved. [Privacy statement](#). [Terms and Conditions](#).
Comments? We would like to hear from you. E-mail us at customercare@copyright.com

7. Scientific Basis and Surgical Technique for Iliotibial Band Tenodesis Combined with ACL

Reconstruction; Controversies in the Technical Aspects of ACL Reconstruction, pages: 393-404

C Kittl, E Inderhaug, J Stephen, H El-Daou, A Williams, AA Amis





Title: Scientific Basis and Surgical Technique for Iliotibial Band Tenodesis Combined with ACL Reconstruction
Author: Christoph Kittl, Eivind Inderhaug, Joanna Stephen et al
Publication: Springer eBook
Publisher: Springer Nature
Date: Jan 1, 2017
Copyright © 2017, ISAKOS

Logged in as:
Christoph Kittl
Account #: 3000781436
[LOGOUT](#)

Order Completed
Thank you for your order.

This Agreement between Christoph Kittl ("You") and Springer Nature ("Springer Nature") consists of your license details and the terms and conditions provided by Springer Nature and Copyright Clearance Center.

Your confirmation email will contain your order number for future reference.

[printable details](#)

License Number	4570021162308
License date	Apr 15, 2019
Licensed Content Publisher	Springer Nature
Licensed Content Publication	Springer eBook
Licensed Content Title	Scientific Basis and Surgical Technique for Iliotibial Band Tenodesis Combined with ACL Reconstruction
Licensed Content Author	Christoph Kittl, Eivind Inderhaug, Joanna Stephen et al
Licensed Content Date	Jan 1, 2017
Type of Use	Thesis/Dissertation
Requestor type	academic/university or research institute
Format	electronic
Portion	full article/chapter
Will you be translating?	no
Circulation/distribution	<501
Author of this Springer Nature content	yes
Title	The anterolateral structures of the knee: Anatomy, biomechanics, and related reconstructions
Institution name	Imperial college London
Expected presentation date	Jun 2019
Requestor Location	Christoph Kittl Melrose Gardens, Melrose House, Penthouse London, W6 7RW United Kingdom Attn: Christoph Kittl
Total	0.00 EUR

[ORDER MORE](#) [CLOSE WINDOW](#)

Copyright © 2019 Copyright Clearance Center, Inc. All Rights Reserved. [Privacy statement](#). [Terms and Conditions](#).
Comments? We would like to hear from you. E-mail us at customercare@copyright.com