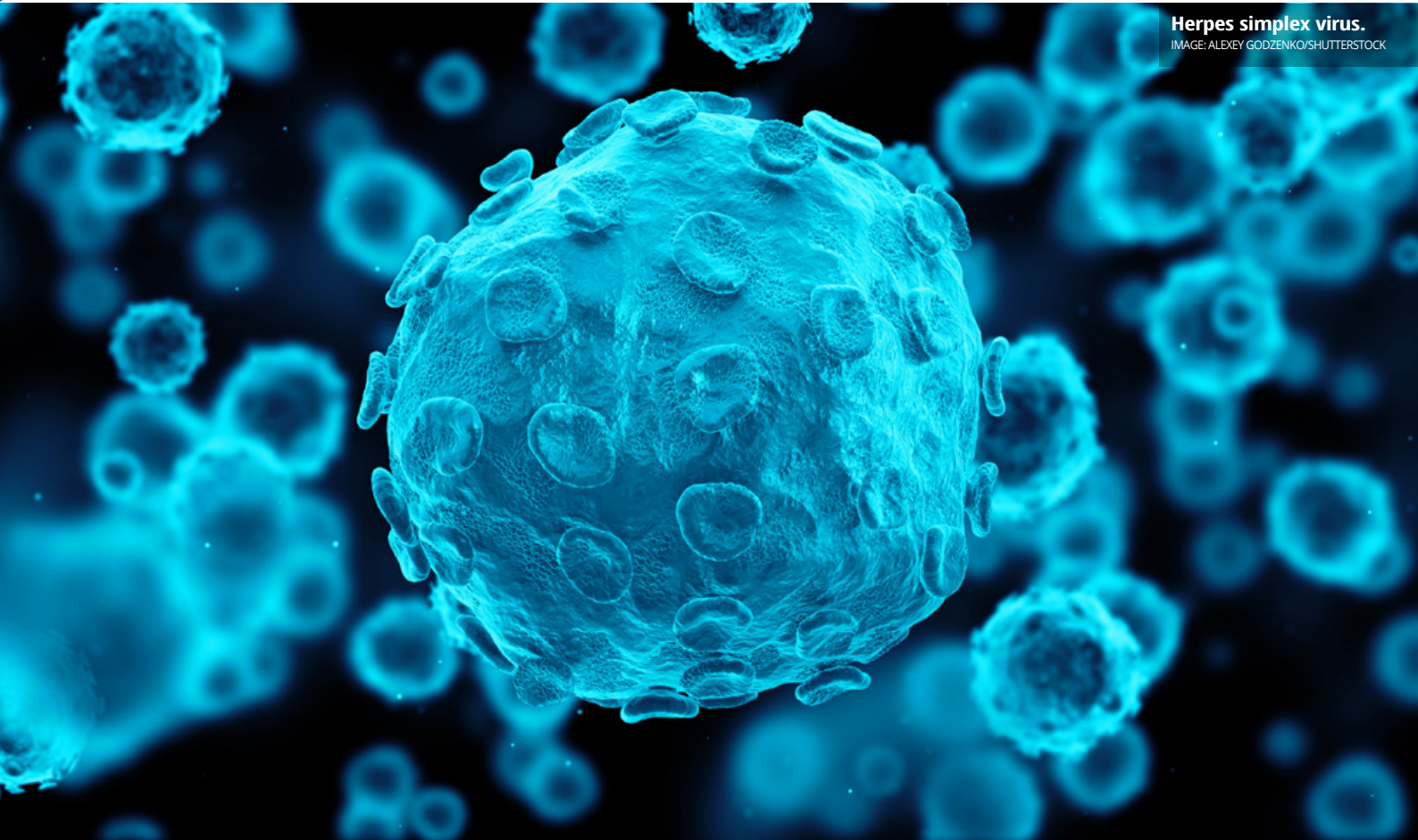


# Community Eye Health *Journal*

Herpes simplex virus.  
IMAGE: ALEXY GODZENKO/SHUTTERSTOCK



## Viral diseases of the eye



**Jeremy Hoffman**  
Clinical Research  
Fellow: International  
Centre for Eye Health,  
London School of  
Hygiene & Tropical  
Medicine, UK.



**Allen Foster**  
Professor,  
International Centre  
for Eye Health,  
London School of  
Hygiene & Tropical  
Medicine, UK.

Viruses are tiny particles that cannot replicate – or survive for very long – outside the cells of their host organism; yet they remain an ongoing risk to our health and our eye health.

**G**lobally, viral infections of the eye are common. They are a significant cause of acute red eye and visual loss. Any part of the eye and adnexa – from the eyelids to the retina and optic nerve – can be affected by viral disease. Some ocular viral infections, such as viral conjunctivitis due to adenovirus or influenza virus, are short lived, with limited ocular complications. However, other viral infections can cause serious complications, such as corneal scarring from stromal keratitis due to herpes simplex virus (HSV) or retinal detachment resulting from cytomegalovirus (CMV) retinitis.

Certain viral eye diseases demonstrate clear clinical signs that enable diagnosis (such as the dendritic

ulcers due to HSV or the unilateral trigeminal nerve distribution of herpes zoster ophthalmicus). In other cases (for example follicular conjunctivitis or uveitis), a variety of different viral infections may be responsible for the same clinical signs. Making a specific diagnosis can therefore be very challenging.

Antibiotics are not effective against viruses, but evidence-based anti-viral treatments exist for several viral infections, including herpes simplex (HSV), varicella zoster (VZV), cytomegalovirus (CMV) and human immune-deficiency virus (HIV).

*Continues overleaf* ►



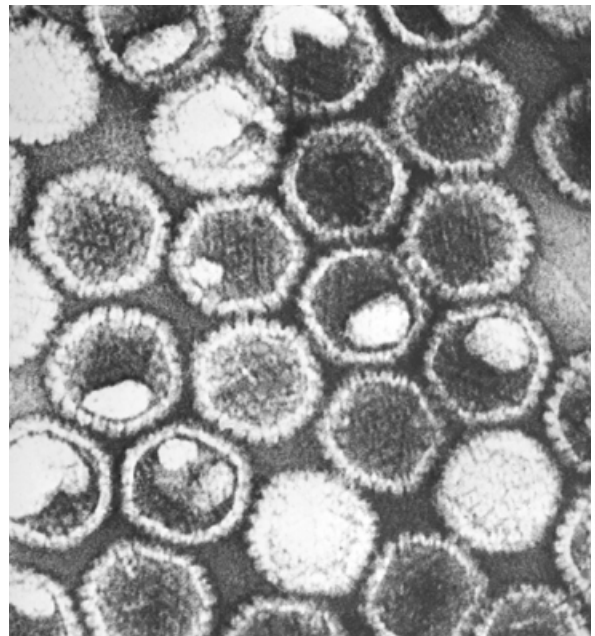
## About this issue

Viral infections of the eye can affect any part of the eye and surrounding tissues; they are a significant cause of acute red eye and visual loss. In this issue, we present an overview of the most common and important ocular viral infections, including diagnosis, management and prevention.

## Contents

- 65 Viral diseases of the eye**  
Jeremy Hoffman and Allen Foster
- 68 Herpes simplex infection of the eye: an introduction**  
Bhupesh Bagga, Anahita Kate, Joveeta Joseph and Vivek Pravin Dave
- 71 How to manage herpes zoster ophthalmicus**  
Stephen Tuft
- 73 Adenovirus: ocular manifestations**  
Jeremy Hoffman
- 76 HIV and the eye**  
Stephen Gichuhi and Simon Arunga
- 79 Cytomegalovirus: clinical features and management**  
Jonel Steffan and James Rice
- 81 Ebola and the eye**  
Gerry Clare
- 82 Zika infection and the eye**  
Olivia A Zin and Andrea Zin
- 85 Overview of antiviral medications used in ophthalmology**  
Jeremy Hoffman
- 89 TRACHOMA: Why disability inclusion is essential for trachoma elimination**  
KH Martin Kollmann, Sofia Abrahamsson and Tim Jesudason
- 90 Questions and answers on viral diseases of the eye**
- 91 Picture quiz**
- 91 Announcements and resources**
- 92 KEY MESSAGES**

**Figure 1** Electron micrograph image of several herpes simplex viruses, showing the lipid envelopes (studded with glycoprotein 'spikes'). Inside each envelope is the nucleocapsid, which houses the viral DNA.



PUBLIC DOMAIN/CENTERS FOR DISEASE CONTROL AND PREVENTION/DR. FRED MURPHY AND SYLVIA WHITFIELD, CONTENT PROVIDERS/1975

## What you will learn

In this issue, we present reviews of eye disease due to herpes simplex and herpes zoster. These are both DNA viruses (see p. 67) and tend to lie dormant in nerve ganglia. Adenovirus is another DNA virus; it usually causes an infectious follicular conjunctivitis. There are also review articles on viral diseases which have come into more prominence in the last two to three decades: HIV, CMV and, more recently, Ebola and Zika. Finally, we have included an article that reviews our current understanding of the available treatments for ocular viral infections.

The aim of this issue is to present an overview of the common and important ocular viral infections, how a clinical diagnosis can be made, and the steps that can be taken to prevent and treat ocular viral infections in order to reduce eye disease and visual loss. If you find it useful, please share it with your colleagues and team members.

## How viruses work

Viruses are very small infectious agents (Figure 2). They consist of:

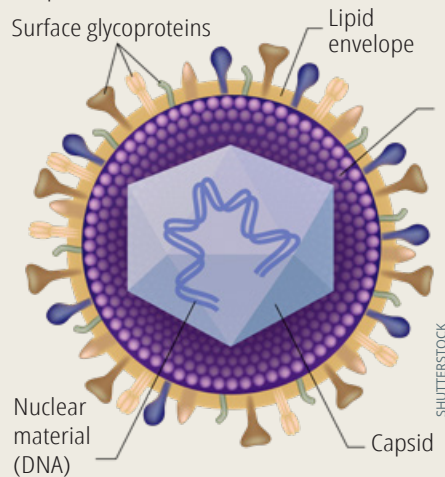
- Genetic material (RNA or DNA)
- A protein coat (the capsid) that surrounds or protects the genetic material
- A lipid envelope around the capsid, studded with unique surface proteins (glycoproteins). Some viruses do not have an envelope.

Viruses are very simple organisms and can only multiply within the living cells of a host organism, such as a human being. A virus will enter the cell and trick it into making copies of the virus until the cell bursts and releases the copies, often destroying the cell in the process.

The viruses – known as viral particles or virions when outside a cell – can then invade other cells or be transmitted to another host. The main mechanisms of transmission are:

- Exchange of bodily fluids (e.g., via blood transfusion, kissing or sexual intercourse)
- Inhalation of airborne viral particles (after an infected person coughs or sneezes)
- Transfer of viral particles from contaminated surfaces to the eyes, nose or mouth, usually via the hands. Surfaces – including ophthalmic equipment – can become contaminated when an infected person coughs or sneezes, or touches the surface after touching their nose, mouth or eyes
- Contaminated surgical instruments that come into contact with body tissues and fluids during surgery.

**Figure 2** Simplified diagram of the herpes simplex virus.



Viruses cause disease in two ways:

- The direct action of the virus on cells. For example, herpes simplex dendritic ulcer.
- The body's immune response to the virus and/or virus-infected cells. For example, herpes simplex disciform endotheliitis (p. 69).

### The immune response

The body's immune system responds to a viral infection by making specific antibodies (the immunoglobulins IgM and IgG) designed to bind either to the unique viral surface proteins, or to viral fragments that remain outside the host cell. The antibody can help to mark the virus or infected cell for destruction by the body's T lymphocyte cells (also known as killer T cells). Once the viral infection has been halted, the memory to make antibodies remains in the immune system of the host, which allows the immune system to recognise the same virus immediately and act to stop a new infection.

Immunisation takes advantage of this fact. It involves exposing the host to a non-pathogenic version of the virus: so that the person doesn't become ill, but the immune system produces antibodies against future exposure to a pathogenic version of the virus. This approach is used successfully with some viruses, such as measles and rubella, which are considered 'stable'. However, with other viruses, such as HIV, the surface proteins are continually changing, so that antibodies do not work effectively. The immune system struggles to fight such virus infections and immunisation is therefore problematic.

### Prevention

Some viral infections can also be prevented by reducing transmission between people. Avoiding unprotected sexual intercourse reduces the risk of transmission of human immunodeficiency virus (HIV) and herpes simplex virus 1 (HSV-1). Regular and effective handwashing helps to prevent the transmission of some viruses e.g., adenovirus.

In a hospital or clinic setting, you can reduce transmission between doctor and patient, and from patient to patient, by practising good hygiene. This includes:

- Close attention to handwashing (scrubbing)
- Cleaning of all surfaces, equipment and instruments using appropriate methods and antiviral solutions
- Wearing protective clothing such as gloves and, in some circumstances, a mask.

*Editorial team*

### Support our work

**We rely on subscriptions and donations from charities and generous individuals to carry out our work.**

To support us, visit:

[www.cehjournal.org/donate](http://www.cehjournal.org/donate)

or contact: Anita Shah:

[admin@cehjournal.org](mailto:admin@cehjournal.org)

### Correspondence articles

We accept submissions of 550 words about readers' experiences.

Contact Anita Shah:

[correspondence@cehjournal.org](mailto:correspondence@cehjournal.org)

Published by the International Centre for Eye Health, London School of Hygiene & Tropical Medicine.

Unless otherwise stated, authors share copyright for articles with the *Community Eye Health Journal*. Illustrators and photographers retain copyright for images published in the journal.

Please note that articles are published online first and may have been shortened to fit the available space in this printed edition.

Unless otherwise stated, journal content is licensed under a Creative Commons Attribution-NonCommercial (CC BY-NC) license which permits unrestricted use, distribution, and reproduction in any medium for non-commercial purposes, provided that the copyright holders are acknowledged.

ISSN 0953-6833.

### Disclaimer

Signed articles are the responsibility of the named authors alone and do not necessarily reflect the views of the London School of Hygiene & Tropical Medicine (the School). Although every effort is made to ensure accuracy, the School does not warrant that the information contained in this publication is complete and correct and shall not be liable for any damages incurred as a result of its use.

The mention of specific companies or of certain manufacturers' products does not imply that they are endorsed or recommended by the School in preference to others of a similar nature that are not mentioned. The School does not endorse or recommend products or services for which you may view advertisements in this Journal.

The *Community Eye Health Journal* is supported by:





**Bhupesh Bagga**  
 Consultant  
 Ophthalmologist :  
 Cornea Institute,  
 L V Prasad Eye  
 Institute,  
 Hyderabad, India.

# Herpes simplex infection of the eye: an introduction

Herpes simplex virus has affected two-thirds of the global population at one time or another. It can affect the eyes when the patient is first infected, or years later when the latent virus is reactivated.



**Anahita Kate**  
 Consultant  
 Ophthalmologist:  
 Cornea Institute,  
 L V Prasad Eye  
 Institute,  
 Hyderabad, India.

According to the World Health Organization (WHO), more than 3.7 billion people under 50 years – 67% of the global population – have been infected with herpes simplex virus at some point in their life.<sup>1</sup> Herpes simplex infection can be particularly severe in patients who are immunodeficient, e.g., those with acquired immune deficiency syndrome (AIDS).

Herpes simplex virus is categorised into two distinct types: HSV-1 and HSV-2.

- HSV-1 is transmitted via direct contact, usually via saliva, and commonly presents as cold sores or fever blisters. It is also a cause of eye infection and significant visual impairment.<sup>2</sup>
- HSV-2 is transmitted via sexual contact or from mother to child during birth (neonatal herpes simplex infection). It causes genital herpes infections and, occasionally, ocular neonatal infection.

Herpes simplex virus is usually acquired in childhood or adolescence. After the initial infection, the virus can enter nerve cells in the dorsal ganglia and lie dormant, or latent.

**Primary ocular herpes infection** is often asymptomatic. The virus can present with cold sores or fever blisters (vesicular dermatitis – see Figure 1), follicular blepharo-conjunctivitis, superficial punctate keratitis (SPKs) and/or dendritic ulcer. Treatment is controversial as it is often self-limiting, but topical and systemic antivirals have been used. Aciclovir eye ointment 3% five times/day or ganciclovir 0.15%, 5-times daily for 7 days, and then three times daily for a further 7 days is recommended for dendritic ulcers.

**Recurrent ocular herpes infection** is due to activation of latent herpes virus in the nerve cells (for example, the trigeminal ganglion), usually in response

to a ‘trigger’ such as fever or stress.

Clinically, ocular infection can be subdivided into keratitis, uveitis and retinitis, each of which will be discussed in this article.

## Herpes simplex keratitis

This can manifest as<sup>3</sup>:

- Infectious epithelial keratitis
- Neurotrophic keratopathy
- Stromal keratitis
- Endotheliitis

### 1. Infectious epithelial keratitis

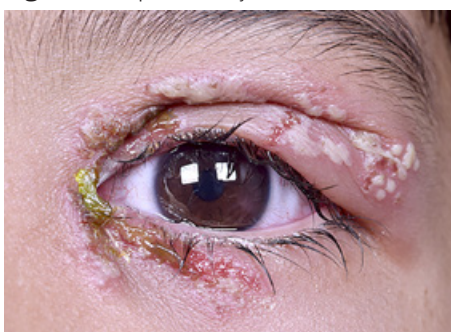**Clinical features.** The earliest presentation is corneal vesicles which later coalesce to form a dendritic ulcer. The dendritic ulcer (Figure 2) presents as a branching linear lesion with terminal bulbs. The base of the ulcer stains with fluorescein while the margins (virus-infected epithelial cells) stain positively with Rose Bengal stain. When these ulcers enlarge, they appear geographical (Figure 3) with well-defined, scalloped margins.

**Diagnosis.** This is based on typical clinical signs. Occasionally, it may be necessary to confirm the diagnosis with a sample taken from a corneal scraping which is sent for virological examination, cell culture or polymerase chain reaction (PCR).<sup>4</sup>

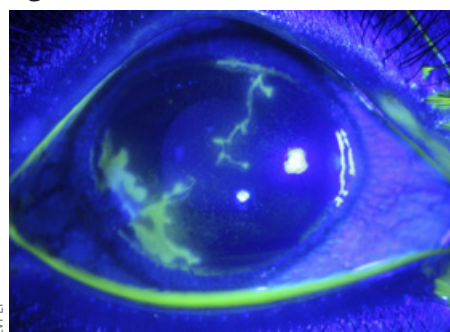
**Treatment.** The usual treatment recommended is topical aciclovir eye ointment 3% five times/day until the ulcer has healed. Trifluridine is an alternative that is used in the USA. Topical ganciclovir 0.15% five times/day is an alternative treatment. If there are many recurrences, consider prescribing oral aciclovir 200 to 400 mg twice/day as prophylaxis. This drug is considered safe for long-term use with 6-monthly evaluation of renal function tests.

Figures 1 to 9 show different clinical presentation of ocular HSV infection.

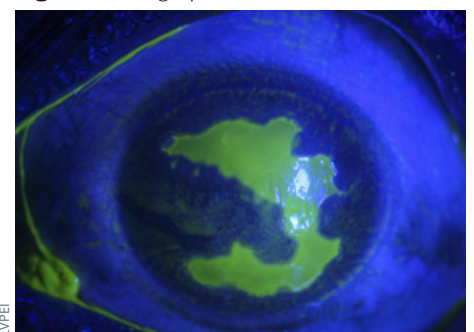
**Figure 1** Blepharo-conjunctivitis



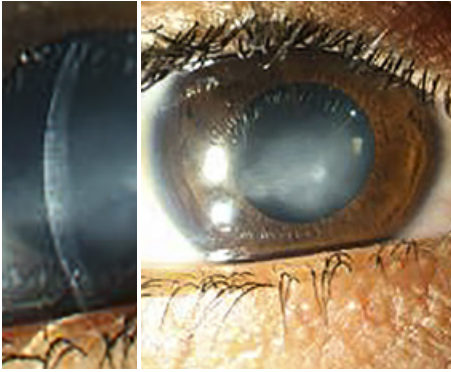
**Figure 2** Dendritic ulcer



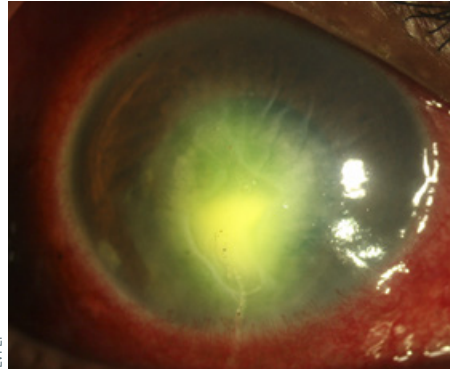
**Figure 3** Geographical ulcer



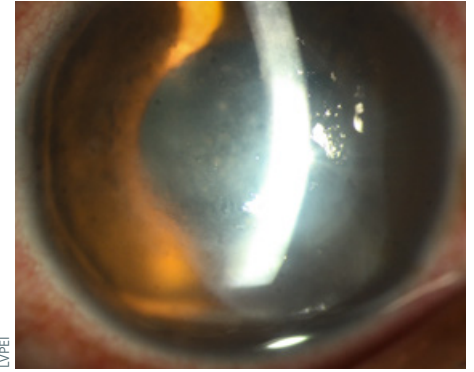
**Figure 4** Immune stromal keratitis



**Figure 5** Necrotising stromal keratitis



**Figure 6** Disciform endothelitis



## 2. Neurotrophic keratopathy

**Clinical features.** There is impaired corneal sensation with a superficial punctate keratitis that can form an epithelial defect with a smooth margin (in contrast to the scalloped margins of a geographical ulcer). A grey-white stromal infiltrate (neurotrophic ulcer) with well-defined, heaped-up epithelial margins may develop; this can lead to progressive stromal thinning, corneal perforation or secondary infection.

**Diagnosis.** Microbiological evaluation with bacterial culture is recommended to rule out secondary infection.

**Treatment.** Intense lubrication and prophylactic antibiotics are recommended. The antibiotics should be kept to a minimum to reduce toxicity to the epithelium. Antivirals are not indicated. Options for non-resolving cases include bandage contact lens or amniotic membrane grafting with tarsorrhaphy if the expertise and resources are available.

## 3. Stromal keratitis

There are two main types of inflammation of the corneal stroma due to herpes simplex virus.

- **Immune stromal keratitis** presents with corneal stromal oedema (Figure 4) and folds in Descemet's membrane. This is associated with fine keratic precipitates (KPs), limbitis and (often) raised intraocular pressure (IOP); there is no epithelial defect.
- **Necrotising stromal keratitis** is due to active viral infection within the cornea. It presents with an epithelial defect (Figure 5) and dense stromal infiltration. If the infection is close to the limbus, then the marginal keratitis shows stromal infiltration and associated vascularisation.

**Diagnosis.** The diagnosis of immune stromal keratitis is made clinically, and no investigations are required.

The diagnosis of necrotising stromal keratitis can also be made clinically. For confirmation, the virus can be detected in a corneal scrape using cell culture, indirect immunofluorescence (IFA) or PCR. It is important to also exclude secondary bacterial infection.

**Treatment.** This depends on the type of inflammation. **Immune stromal keratitis** is managed with topical low-dose corticosteroids 4–6 times/day with gradual tapering for 4–6 weeks, along with either topical aciclovir ointment 5 times/day or topical trifluridine for 2–3 weeks. For recurrent cases, provide prophylactic cover by giving oral aciclovir 200–400 mg 2 times/day.

**Necrotising stromal keratitis** is treated using 400–800 mg oral aciclovir 5 times/day. After complete healing of the epithelial defect, topical corticosteroids may be added to reduce inflammation, but only with regular slit lamp examination to look for any recurrence of infection or corneal thinning, which could lead to corneal perforation.

## 4. Endotheliitis

Endotheliitis is presumed to be immunogenically mediated, but the presence of live HSV has been postulated in some cases.

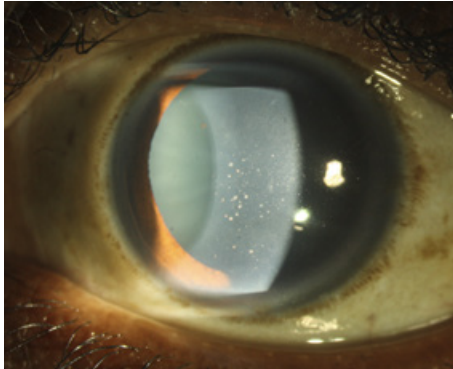
**Clinical features.** Endotheliitis presents with stromal oedema, similar to immune stromal keratitis (Figure 6) with keratic precipitates (KPs) limited to the area of corneal edema. The endotheliitis can be linear (starting from the corneo-scleral junction and spreading centrally), disciform (usually in the centre of the cornea), or diffuse.

**Diagnosis.** The diagnosis is made clinically.

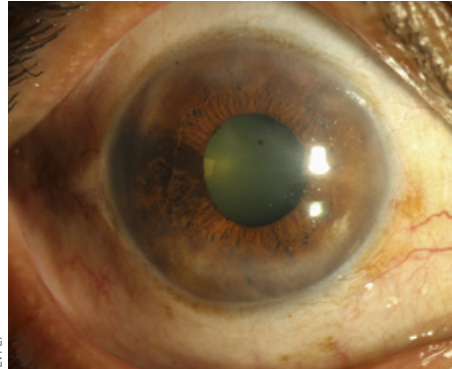
**Treatment.** Low dose topical corticosteroids are recommended with prophylactic topical or oral aciclovir for 2 weeks.

*Continues overleaf* ►

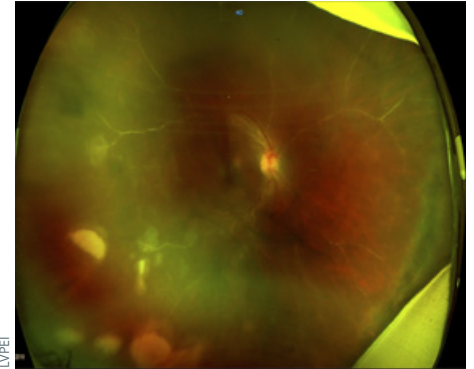
**Figure 7** Large pigmented keratic precipitates



**Figure 8** Patchy iris atrophy seen in chronic herpetic kerato-uveitis



**Figure 9** Acute retinal necrosis due to herpes simplex virus: multiple peripheral retinitis patches, sclerosed arteries, arteriolar sheathing in periphery



## Herpes simplex uveitis

Herpes simplex-associated anterior uveitis accounts for 5–10% of all uveitis cases.<sup>5</sup> It is more common in older age groups, almost always unilateral and is associated with raised intraocular pressure (IOP). Pathogenesis may be due to direct infection by the virus or an immune response.

**Clinical features.** There are five clinical features which, seen together (not in isolation), characterise HSV anterior uveitis<sup>6</sup>:

- Recurrent episodes of unilateral anterior uveitis
- Past history of herpes simplex infection
- Raised IOP
- Diffuse KPs (Figure 7)
- Patchy or sectoral iris atrophy (Figure 8)

**Diagnosis.** Diagnosis can be confirmed by an anterior chamber (AC) tap and PCR for herpes simplex virus, or the Goldmann–Witmer coefficient (GWC) test. The GWC is a test that compares the levels of intraocular antibody production to that of serum, as measured by enzyme-linked immunosorbent assay (ELISA) or radioimmunoassay.

**Treatment.** Management includes oral aciclovir 400–800 mg, 5 times/day combined with topical steroids and topical cycloplegics. Raised IOP is treated using anti-ocular hypertensive therapy. If there is any active keratitis, topical steroids should be used with caution.

## Herpes simplex retinitis

Herpes simplex retinitis is caused when the virus infects the retina. It is seen more commonly in immunocompromised patients. It can occur in neonatal herpes simplex infection in association with herpes encephalitis. Some cases of acute retinal necrosis (ARN) are caused by the virus.

**Clinical features.** There are large, white retinal infiltrates, sheathing of the retinal vessels (Figure 9) and inflammatory cells in the vitreous (vitritis). On healing, there are large areas of scarred (atrophic) retina.

**Diagnosis.** Vitreous or aqueous tap for PCR to confirm presence of viral DNA.

**Treatment.** On diagnosis, promptly start the following treatment regimen in order to limit disease progression: antiviral treatment with intravenous aciclovir (5–10 mg/kg every 8 hours) for 5–10 days; followed by oral aciclovir (800 mg, 5 times/day) for 4–6 days. Retinal detachment following acute retinal necrosis (ARN) can be managed with a pars plana vitrectomy and silicone oil tamponade.<sup>7,8</sup>

## References

- 1 Looker KJ, Magaret AS, May MT, Turner KME, Vickerman P, et al. Global and regional estimates of prevalent and incident herpes simplex virus type 1 infections in 2012. *PLOS ONE* 2015;10(10): e0140765. <https://doi.org/10.1371/journal.pone.0140765>.
- 2 Guess S, Stone DU, Chodosh J. Evidence-based treatment of herpes simplex virus keratitis: a systematic review. *Ocul Surf* 2007;5(3):240-50.
- 3 Holland EJ, Schwartz GS. Classification of herpes simplex virus keratitis. *Cornea* 1999;18(2):144-54.
- 4 Farhatullah S, Kaza S, Athmanathan S, Garg P, Reddy SB, Sharma S. Diagnosis of herpes simplex virus-1 keratitis using Giemsa stain, immunofluorescence assay, and polymerase chain reaction assay on corneal scrapings. *Br J Ophthalmol* 2004;88(1):142-4.
- 5 Rathinam SR, Namperumalsamy P. Global variation and pattern changes in epidemiology of uveitis. *Indian J Ophthalmol* 2007;55(3):173-83.
- 6 Wensing B, Mochizuki M, De Boer JH. Clinical Characteristics of Herpes Simplex Virus Associated Anterior Uveitis. *Ocul Immunol Inflamm* 2018;26(3):333-7.
- 7 Schoenberger SD, Kim SJ, Thorne JE, Mruthyunjaya PM, Yeh S, MD SJB, et al. Diagnosis and Treatment of Acute Retinal Necrosis A Report by the American Academy of Ophthalmology. *Ophthalmology* 2017;124(3):382–92.
- 8 Dave VP, Pappuru RR, Pathengay A, Tyagi M, Narayanan R, Jalali S. Vitrectomy with Silicone Oil Tamponade in Rhegmatogenous Retinal Detachment following Acute Retinal Necrosis: Clinical Outcomes and Prognostic Factors. *Semin Ophthalmol* 2018;29:1-5.



**Stephen Tuft**  
Consultant  
Ophthalmologist  
Moorfields Eye  
Hospital,  
London, UK.

# How to manage herpes zoster ophthalmicus

Herpes zoster ophthalmicus is a severe variant of shingles (herpes zoster), which occurs when the immune system is weakened and the virus responsible for chickenpox reactivates.

**H**erpes zoster (shingles) is an infection caused by re-activation of the varicella zoster virus, which causes chickenpox. Primary infection usually happens in childhood. After the primary infection, the patient is immune to the virus, which then lies inactive in the dorsal root ganglia or cranial ganglia. Eventually, as the patient's natural immunity reduces as a result of ageing or disease, the virus can reactivate and spread to the skin, via the afferent nerves, to cause herpes zoster. By the time they are 40 years of age, the vast majority (99.6%) of individuals worldwide have antibodies to varicella zoster virus and are therefore at risk of herpes zoster.<sup>1</sup>

About one-third of individuals will get herpes zoster in their lifetime. Herpes zoster can appear at any age, although there is a strong tendency for it to develop after 60 years of age due to natural weakening of the immune system. There has been a worldwide increase in the prevalence of herpes zoster. The reason for this is not known; however, with an ageing population, the incidence is likely to increase.

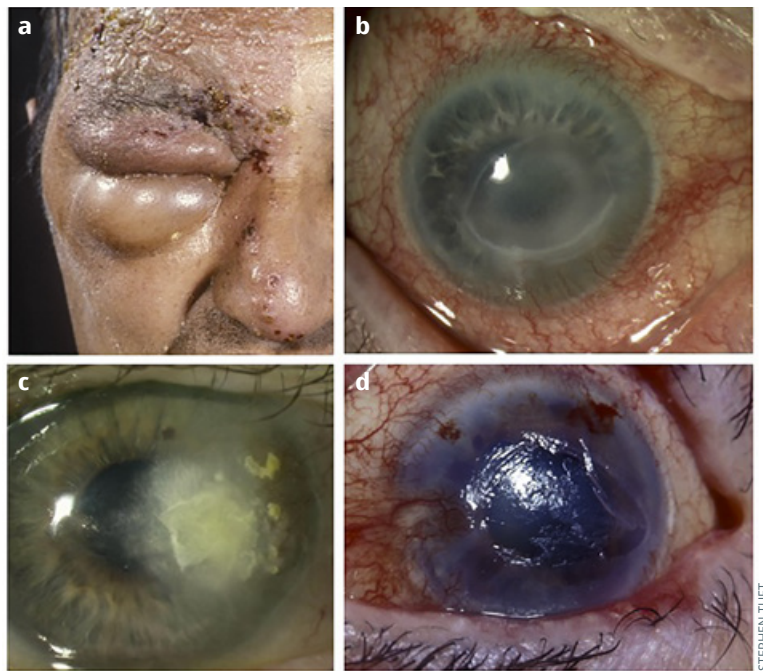
**“About one-third of individuals will get herpes zoster in their lifetime.”**

The majority of individuals who get herpes zoster are otherwise healthy. However, it is more common in immunocompromised individuals (e.g., after chemotherapy, immunotherapy or oral steroids) or with some diseases (e.g., diabetes mellitus or cancer). In some regions, herpes zoster may signal underlying immunosuppression from HIV/AIDS, especially in young adults; these patients are also at risk of severe complications and systemic involvement. Recurrent attacks of herpes zoster are uncommon, but they are a feature of HIV/AIDS.

## Clinical presentation

Herpes zoster most frequently involves the chest, abdomen, face or genitals. The distribution corresponds to the distribution of the nerve (dermatome) that has been affected. The disease does not cross the midline, but two adjacent dermatomes on the same side can be involved. Herpes zoster ophthalmicus (HZO) is a particularly severe variant of herpes zoster and accounts for about 20% of all cases. The eye is not always involved, but there is a particularly high risk (50%) of ocular involvement if the first division of the fifth cranial (trigeminal) nerve is affected, with vesicles extending to the tip of the nose, known as Hutchinson's sign (Figure 1).<sup>1,2</sup>

The clinical signs of HZO are usually preceded by tingling over the affected area, and patients generally feel unwell and have a headache. After 2–3 days, a painful rash develops, consisting of blisters that ooze fluid for 3–5 days.



**Figure 1** Acute herpes zoster ophthalmicus (HZO) with blisters and eyelid swelling (a). Chronic corneal epithelial defect in an anaesthetic cornea (b). Corneal anaesthesia complicated by secondary corneal calcification (c) and vascularisation (d).

The blisters then dry out and form scabs that heal after four weeks. The skin remains painful until the rash has gone.

Post-herpetic neuralgia sometimes develops. It involves pain, itching, and burning over the area of the initial rash that is still present after three months. This develops in about 13% of all cases, and half of individuals over 70 years will still have pain from it after a year. The incidence of post-herpetic neuralgia increases with age of onset of HZO, with eye involvement, and with the severity of the initial attack. It can be debilitating, preventing sleep and daily activities, and severely affect quality of life.

HZO can affect all parts of the eye, with an onset of disease 2–4 weeks after the first appearance of the rash. Anterior segment complications can be severe. They include dendritic keratitis, secondary corneal anaesthesia, persistent epithelial defect, secondary infection, stromal neovascularisation, and corneal opacity (Figure 1).

Patients with HIV/AIDS, in particular, can develop disfiguring scarring and pigmentation of the face and lids. There may also be chronic granulomatous uveitis, iris atrophy, scleritis, and acute retinal necrosis. Vasculitis is less common but can cause ischaemic optic neuropathy, extraocular muscle palsies and a contralateral stroke.

Varicella zoster virus is the most common cause of acute retinal necrosis. However, acute retinal necrosis is not restricted to patients who have had HZO, which suggests that blood, rather than nerves, are responsible for the spread of the virus to the eye.

## Diagnosis

The appearance of HZO is very characteristic, and this gives the diagnosis in almost all cases. However, tingling or pain exacerbated by light touch may develop several days

*Continues overleaf* ➤

before the rash or, rarely, a rash may never develop (zoster sine herpette). In these patients, identifying the cause of the neuralgia can be difficult. Herpes virus DNA can sometimes be detected in the tear film by polymerase chain reaction (PCR), although this is an expensive test and not widely available. As the majority of adults have had chickenpox, they will have antibodies against varicella zoster virus and serology is rarely helpful. It is not necessary to perform extensive investigation for underlying diseases, unless HIV/AIDS is suspected.

## Differential diagnosis

Herpes simplex infection of the lid and cornea can mimic HZO, especially if there is bacterial superinfection of severe atopic dermatitis (eczema herpeticum). Contact dermatitis from plants, or a reaction to locally applied medications, can mimic HZO. Consider herpes simplex if patients have had multiple recurrences of 'shingles'. A bilateral rash is unlikely to be HZO.

## Treatment

Medical staff should wear gloves if touching skin with blisters; however, if they have had chickenpox in the past, they are not at risk of infection. Wash the affected skin with soap and water and pat dry, cover with a loose dressing, and use a dry cold compress if available. Don't use dressings that can stick to the skin. Antibiotics are not necessary unless secondary skin infection is suspected, and don't use topical antivirals on the skin.

There is no agreed consensus for the medical management of HZO. If a patient is seen within 72 hours of the onset of the blisters, they should be given a course of oral aciclovir tablets: 800 mg five times daily for seven days (alternatives are either valaciclovir 1 g or famciclovir 500 mg, three times a day). Provide this treatment at the start of any new ocular involvement. Intravenous aciclovir should be considered for individuals with HIV/AIDS to reduce the risks of disseminating varicella zoster infection. Antiviral treatment reduces the risk of chronic ocular complications by 20% to 30%. It does not prevent post-herpetic neuralgia but reduces the duration of the pain by about 50%.

Dendritic keratitis and uveitis may indicate chronic HZV activity. Keratitis should be treated with topical aciclovir 3% ointment or ganciclovir 0.15%, five times daily for at least 5 days, reducing to twice daily until the dendrites have resolved. Add a topical steroid if there is stromal disease or uveitis. Slow tapering of topical steroid may be required, and some individuals need long-term drops once a day to control inflammation. Long-term prophylactic antiviral treatment (oral aciclovir 400 mg twice a day) is often used to treat these complications and prevent reactivation of the varicella zoster virus in the eye, but this is not yet evidence based.

Patients can develop complete corneal anaesthesia after HZO, known as neurotrophic keratitis. This can lead to sight loss, as the anaesthetic cornea is at risk of developing an epithelial defect, secondary infection, vascularisation and scarring. Frequent lubricating drops are helpful to prevent epithelial breakdown. A chronic epithelial defect may heal with a temporary tarsorrhaphy, bandage contact lens or amniotic membrane graft. Unfortunately, a proportion of patients eventually require a permanent tarsorrhaphy or conjunctival flap to protect the eye. Severe post-herpetic neuralgia may be helped by giving oral analgesics (paracetamol, short-acting narcotics), anticonvulsants (e.g., gabapentin) or tricyclic anti-depressants. Acute retinal necrosis requires specialist management and patients should

be referred to a tertiary centre if possible. Treatment includes intravenous aciclovir 10–15 mg/kg for 2 weeks, followed by oral valaciclovir 1 g three times daily for a further 6 weeks.

## Follow-up

Corneal anaesthesia is a common feature of HZO, and progressive corneal disease may pass unnoticed. Review patients periodically or ask them to monitor their vision themselves and seek help if it deteriorates. Patients receiving topical steroid treatment should be monitored for complications.

## Prevention and vaccination

A vaccine against chickenpox is available in many countries. This uses a live, attenuated virus, and is also used at a higher dose to prevent (not treat) herpes zoster. Because it is a live virus, do not give this vaccine to people who have impaired immunity (e.g., people with HIV/AIDS). A recombinant virus vaccine is also available to treat herpes zoster and, as it does not contain a live virus, it can be used in immunocompromised patients. Both vaccines boost cell-mediated immunity against varicella zoster virus, which then reduces the risk of reactivation. Regional guidelines vary, but vaccination against herpes zoster is usually only recommended for individuals over 60 years of age. Both vaccines are safe to use in patients who have had chickenpox and individuals do not need to be tested for immunity against the virus before they are vaccinated. A large randomised-controlled clinical trial found that, after three years, the live attenuated vaccine had reduced the incidence of herpes zoster amongst adults over 60 years of age by 51% and the burden of illness by 66.5%.<sup>3</sup> A second observational study of the use of the same vaccine in patients over 60 years of age reported that it reduced the risk of eye involvement (HZO) by almost two thirds (hazard ratio 0.37).<sup>4</sup>

Unfortunately, the effect of vaccination only lasts for about eight years, and the vaccine is less effective in patients older than 70 years. The recombinant vaccine is more effective than the live attenuated vaccine, and it reduces the incidence of herpes zoster and post-herpetic neuralgia by 90%; it is now the preferred option in some countries.<sup>5</sup> If these vaccines are available and recommended for use in your country, the current recommendations are to use the live attenuated vaccine to prevent chickenpox and the recombinant vaccine to prevent herpes zoster. Interestingly, vaccination in childhood does not seem to reduce the risk of herpes zoster in later life.

Cost is a consideration in the widespread introduction of vaccination against herpes zoster. Prophylactic low-dose oral aciclovir (400 mg twice daily) is a less effective alternative to vaccination for patients at high risk of herpes zoster.

## Patient counselling

A patient with HZO can spread chickenpox in non-immune individuals, but HZO cannot be transmitted directly to cause HZO in another person. Transmission of the virus typically requires direct contact with oozing skin. The risk of transmission stops when the rash crusts and stops leaking. Patients who are immunocompromised (e.g., those who have HIV/AIDS) are more contagious because they shed more virus particles. A person who has HZO blisters should avoid direct contact with babies less than 1 month of age, pregnant women who have not had chickenpox, and individuals with a suppressed immune system.

## References

- Schmader K. Herpes Zoster. *Ann Intern Med.* 2018;169(3):ITC19-ITC31.
- Cohen EJ, Kessler J. Persistent dilemmas in zoster eye disease. *Br J Ophthalmol.* 2016;100(1):56-61.
- Oxman MN, Levin MJ, Johnson GR, Schmader KE, Straus SE, Gelb LD, et al. A vaccine to prevent herpes zoster and postherpetic neuralgia in older adults. *N Engl J Med.* 2005;352(22):2271-84.
- Tseng HF, Smith N, Harpaz R, Bialek SR, Sy LS, Jacobsen SJ. Herpes zoster vaccine in older adults and the risk of subsequent herpes zoster disease. *JAMA.* 2011;305(2):160-6.
- Cunningham AL, Lal H, Kovac M, Chlibek R, Hwang SJ, Diez-Domingo J, et al. Efficacy of the Herpes Zoster Subunit Vaccine in Adults 70 Years of Age or Older. *N Engl J Med.* 2016;375(11):1019-32.





**Jeremy Hoffman**  
Clinical Research  
Fellow: International  
Centre for Eye Health,  
London School of  
Hygiene & Tropical  
Medicine, UK.

# Adenovirus: ocular manifestations

Adenoviral infections of the ocular surface are a common, highly infectious, cause of ocular morbidity. As no specific antiviral agent exists for adenoviral ocular infections, treatment is supportive and robust hygiene measures need to be implemented to reduce its spread; there is no role for topical antibiotics.

Eye health workers are commonly faced with adenoviral infection of the eye as a cause of bilateral conjunctivitis. Adenoviral infection presents with sudden onset of red eye(s) with a watery discharge often associated with a sore throat. The differential diagnosis includes bacterial (including chlamydial) conjunctivitis, other viral causes of conjunctivitis and, possibly, allergic conjunctivitis. The virus is easily transmitted and there is no specific treatment.

The adenoviruses comprise 51 distinct types of double-stranded DNA viruses that are structurally similar, but antigenically different (serotypes).<sup>1</sup> These highly stable viruses are found throughout the world and cause respiratory tract, genitourinary, gastrointestinal and ocular infections. Adenoviral infection is usually self-limiting but can lead to fatal multiple-organ failure in immunocompromised individuals.

**“These highly stable viruses are found throughout the world.”**

Adenoviral infection, in common with most other causes of viral conjunctivitis, is highly contagious: the risk of inter-familial infection rates have been estimated at between 10% and 50%.<sup>2,3</sup> The virus can be transmitted via contaminated hands, tissues, towels, from swimming pools as well as medical instruments and devices; possibly also via airborne nasal droplets (from sneezing). Anything that the patient touches (or which touches the patient) can act as a potential source.

To prevent transmission of infection in the eye clinic:

- Always practice good hand hygiene between patients
- Clean used ophthalmic instruments and equipment with disinfectant wipes after each patient.

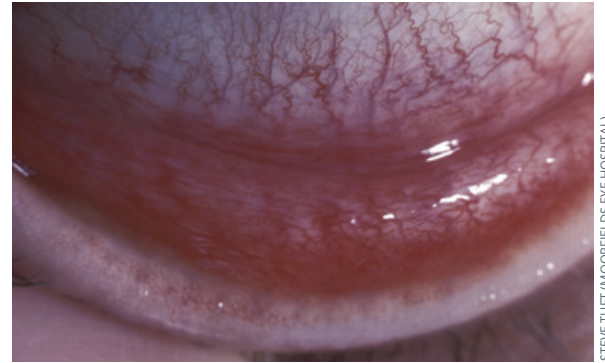
If adenoviral infection is known or suspected

- If possible, put patients with suspected adenovirus in a separate waiting room. Use a separate examination room if one is available.
- Use disposable gloves
- Avoid contact of the eye with instruments
- If an instrument has come into contact with the eye or hands of a patient or health worker, soak the instrument in a sodium hypochlorite solution for at least 10 minutes before using it again.

## Clinical phenotypes

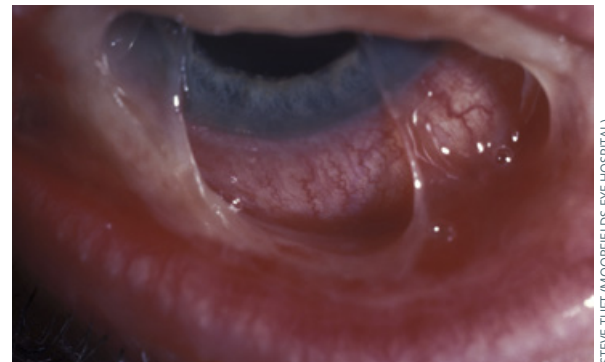
There are four recognised clinical presentations (phenotypes) for adenoviral conjunctivitis:

**Figure 1** Tarsal conjunctival follicles that are typically seen in viral conjunctivitis.



STEVE TUFT (MOORFIELDS EYE HOSPITAL)

**Figure 2** Adenoviral conjunctivitis with conjunctival hyperaemia and significant pseudomembranes. Pseudomembranes can be distinguished from true membranes as they do not bleed when removed. Both forms of membranes must be gently removed by everting the eyelids and using either a cotton-tipped applicator or some sterile forceps to help prevent tarsal scarring and relieve discomfort.



STEVE TUFT (MOORFIELDS EYE HOSPITAL)

- epidemic keratoconjunctivitis
- pharyngoconjunctival fever
- acute non-specific follicular conjunctivitis
- chronic keratoconjunctivitis.

## Epidemic keratoconjunctivitis (EKC)

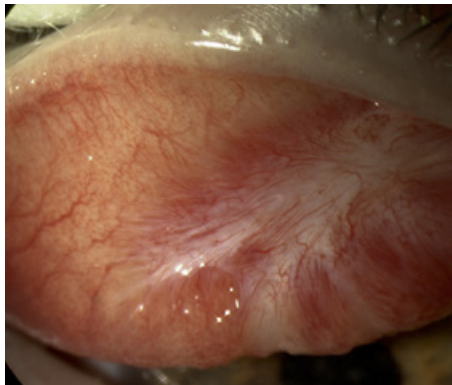
Epidemic keratoconjunctivitis (EKC) is the most serious of the adenoviral infections. It is associated with adenovirus serotypes 8 and 19, although associations with other types have been reported.<sup>4,5</sup>

Transmission occurs amongst individuals in close contact with one another. It typically affects young adults during autumn and winter, is unilateral in two-thirds of cases, with no systemic features. This is in contrast with pharyngoconjunctival fever (PCF), which is usually bilateral and associated with systemic symptoms of sore throat and fever.

After an incubation period of eight days, patients develop significant redness of the conjunctiva, watery discharge from the eye and foreign-body sensation. Signs include tender and swollen lymph nodes in front of the ears (pre-auricular lymphadenopathy, seen in over 50% of cases) together with tarsal conjunctival follicles (Figure 1). The presence of these two signs together is highly suggestive of adenoviral conjunctivitis<sup>6</sup> and should assist in clinical diagnosis.

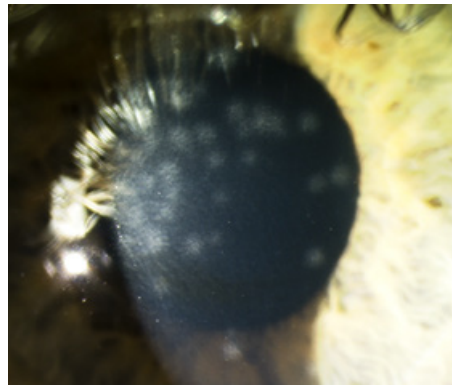
*Continues overleaf* ➤

**Figure 3** Everted upper eyelid showing tarsal scarring in a patient with a history of membranous adenoviral conjunctivitis. This patient did not have the membranes removed during the acute episode.



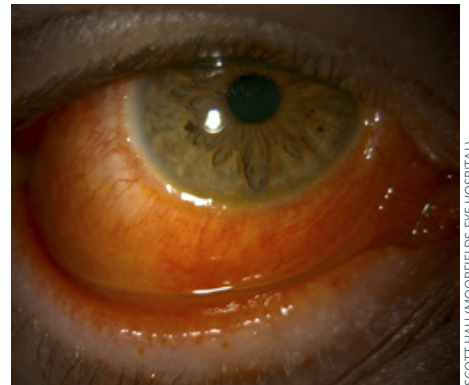
MATTHEW BURTON (LSHTM & MOORFIELDS EYE HOSPITAL)

**Figure 4** Subepithelial opacities seen in adenoviral keratitis. These typically are non-staining and can persist even after the acute episode of conjunctivitis has resolved.



MATTHEW BURTON (LSHTM & MOORFIELDS EYE HOSPITAL)

**Figure 5** The right eye of a patient with bilateral adenoviral pharyngoconjunctival fever. There is significant conjunctival hyperaemia, petechial subconjunctival haemorrhages and conjunctival follicles.



SCOTT HAUJ (MOORFIELDS EYE HOSPITAL)

Other symptoms and signs that may be present include mild photophobia, swelling of the conjunctiva, small subconjunctival haemorrhages, and either pseudo-membranes or true membranes that may bleed when removed (Figure 2). Rarely, symblephara may form and tarsal scarring can occur (Figure 3). If the fellow eye becomes involved, this usually occurs 4–5 days into the disease and the signs are generally less severe than in the first eye, due to partial host immunity.<sup>7</sup>

**Adenoviral keratitis** is divided into four stages (see panel and Figure 4).<sup>4,7-9</sup>

### Adenoviral keratitis

#### Stage 1

Diffuse, fine, superficial epithelial punctate keratitis

#### Stage 2

Staining focal punctate white epithelial lesions

#### Stage 3

Combined epithelial and subepithelial areas

#### Stage 4

Non-staining subepithelial macular lesions

- Stage 1 usually occurs within the first week after development of the adenoviral conjunctivitis, with symptoms of worsening discomfort, photophobia and lacrimation. This is due to diffuse superficial epithelial punctate keratitis caused directly by the live virus.
- Stage 2 is characterised by larger, fluorescein-staining white punctate epithelial lesions, and follows soon after Stage 1.
- Stage 3 occurs after a further 24–48 hours with areas of combined epithelial and subepithelial lesions.
- Stage 4 – the adenoviral conjunctivitis has usually started to resolve, and the patient is left with non-staining subepithelial lesions (Figure 4).

Stages 2–4 are thought to develop due to a delayed-type hypersensitivity reaction to the epithelial viral antigens.<sup>7,8</sup>

The adenoviral conjunctivitis has usually resolved by two to three weeks after onset, whereas Stage 4 keratitis reaches its peak between weeks three and four. At this point, visual acuity may be reduced by one or two lines. These subepithelial lesions may persist

for months and – rarely – years; however, they usually resolve entirely without scarring and visual acuity returns to baseline.

### Pharyngoconjunctival fever

Pharyngoconjunctival fever (PCF) is associated with adenovirus types 3, 4 and 7.<sup>1,7</sup> It is highly contagious and spreads rapidly amongst individuals living or working in close proximity with one another. Unlike EKC, systemic symptoms predominate, with pharyngitis, tender pre-auricular lymphadenopathy, fever and an acute follicular conjunctivitis.

The incubation period is approximately eight days following exposure (range: 5–12 days), when patients develop a high fever with associated muscle pain, malaise and, occasionally, gastrointestinal upset.<sup>1,7</sup> An acute follicular conjunctivitis develops a few days into the symptomatic illness, with initial symptoms of irritation, burning and lacrimation. The conjunctivitis is usually worse in the lower fornix and can lead to a tender, swollen lower eyelid, occasionally with bruising that can mimic orbital trauma. Both eyes are usually involved, although there may be a delay of 1–3 days before the fellow eye becomes symptomatic (Figure 5).

Adenoviral keratitis is less common in pharyngoconjunctival fever than with EKC but, if present, follows the same progressive four stages as outlined above.

### Acute non-specific follicular conjunctivitis

This form of adenoviral conjunctivitis is caused by numerous adenovirus serotypes. However, it is a mild, self-limiting conjunctivitis commonly seen in children and young adults, which resolves within 7–10 days of symptom onset. Adenoviral conjunctivitis is characterised by soreness and lacrimation, with red conjunctiva and tarsal follicles; the cornea is not involved. The differential diagnosis includes chlamydial or herpes simplex acute follicular conjunctivitis.

### Chronic keratoconjunctivitis

Chronic keratoconjunctivitis caused by adenovirus is rare but has been reported.<sup>10–12</sup> Clinically, it presents as a relapsing and remitting prolonged course of intermittent conjunctival redness, lacrimation and photophobia. There will be a history of previous viral conjunctivitis within the last 6–9 months. It can be a challenge to diagnose as unlike the other types of

adenoviral conjunctivitis, conjunctival papillae rather than follicles predominate. Diagnosis can be confirmed through laboratory investigations as discussed below.

## Investigations

Routine investigations are not usually required for adenoviral conjunctivitis as the diagnosis can be made clinically, particularly if there are conjunctival follicles and tender pre-auricular lymphadenopathy in the absence of significant purulent discharge. When performing investigations for viral conjunctivitis, test for bacterial and chlamydial infection, as well as a range of viruses, including adenovirus and herpes simplex virus.

Available investigations include real-time polymerase chain reaction (RT-PCR), rapid antigen testing, viral culture, and serology for virus-specific IgM and a rise in virus-specific antibody titre over time<sup>7</sup>. Of these, RT-PCR has become the laboratory test of choice as it is rapid with high sensitivity and specificity, although it is not universally available.<sup>13</sup>

Rapid antigen testing has reported sensitivity and specificity of 89% and 94% respectively.<sup>14</sup> This point-of-care testing, although relatively costly, can be very useful in a primary care setting by preventing the incorrect diagnosis of bacterial conjunctivitis and unnecessary antibiotic use.

## Treatment

There is no specific licensed treatment for adenoviral conjunctivitis. Current advice is targeted at symptom relief with artificial tears and cold compresses to the eyes.<sup>15</sup> There is no role for antibiotics as they do not protect against secondary infection; unscrupulous use can lead to bacterial resistance and diagnostic confusion as the drops themselves can lead to local toxicity and allergy.<sup>2,6</sup> Beyond these recommendations, treatment is controversial.

The antivirals cidofovir and ganciclovir have been investigated as potential treatments, although the evidence for their routine use is limited.<sup>16-19</sup>

Povidone-iodine (PVP-I) drops is another potential agent for the treatment of adenoviral conjunctivitis<sup>16</sup>. Studies investigating PVP-I in combination with topical steroids (0.1% dexamethasone) have shown a reduction in symptoms and viral titre in both humans and rabbit models.<sup>17,18</sup> A recently published Phase 2 randomised controlled trial suggests some benefit of a combination treatment of PVP-I and dexamethasone in terms of speed of clinical resolution and adenoviral eradication, although this is not yet commercially available and the potential of significant steroid-induced side-effects has not been fully investigated.<sup>19,20</sup>

Other than antivirals, there is also controversy surrounding the use of topical steroids to treat adenoviral infection. Although topical steroids can speed the resolution of the signs and relieve symptoms, it is associated with increased viral shedding and duration of active viral infection beyond the typical 12 days, meaning the patient is infectious for longer.<sup>21,22</sup> This can have public health implications, as the number of viruses circulating in the population and environment (the viral reservoir) is increased.

If there is sub-epithelial adenoviral keratitis, topical steroids can rapidly reduce or eliminate the subepithelial opacities,

resulting in improved visual acuity. However, on cessation of the topical steroids the opacities usually recur; it is only with time that they will fade.<sup>8</sup> The established side-effects of topical steroids – raised intraocular pressure and cataract formation – should be considered. However, it is reasonable to treat patients with significant pseudo-membranes or membranes with topical steroids, to reduce the chance of symblephara formation. In addition, patients with significantly reduced vision due to sub-epithelial opacities in the cornea, especially where it is limiting their daily activities, may benefit from treatment – provided they are counselled regarding the side-effects and the potential return of opacities when treatment is stopped.

## Conclusion

Adenoviral ocular infection is highly contagious and usually presents as a follicular conjunctivitis with pre-auricular lymphadenopathy. Although often self-limiting, certain subtypes are associated with a protracted course and significant morbidity; there is also the considerable economic cost to be considered. At present, there is no licensed treatment for this common condition and the treatment currently recommended is supportive, although clinical trials are currently ongoing.

## References

- 1 Baum S. Adenovirus. In: *Mandell, Douglas, and Bennett's principles and practice of infectious diseases*. Churchill Livingstone; 2010.
- 2 Kaufman HE. Adenovirus advances: new diagnostic and therapeutic options. *Current Opinion in Ophthalmology* 2011;22:290–293.
- 3 Høvdig G. Acute bacterial conjunctivitis. *Acta Ophthalmol* 2008;86:5–17.
- 4 Murrah WF. Epidemic keratoconjunctivitis. *Ann Ophthalmol* 1988;20:36–38.
- 5 O'Day DM, Guyer B, Hierholzer JC. Clinical and laboratory evaluation of epidemic keratoconjunctivitis due to adenovirus types 8 and 19. *AJOPHT* 1976;81:207–215.
- 6 O'Brien TP, Jeng BH, McDonald M, Raizman MB. Acute conjunctivitis: truth and misconceptions. *Curr Med Res Opin* 2009;25:1953–1961.
- 7 Pavan-Langston D. Viral Disease of the Cornea and External Eye. In: *Albert & Jakobiec's Principles and Practice of Ophthalmology*. 2008.
- 8 Laibson PR, Dhiri S, Oconer J, Ortolan G. Corneal infiltrates in epidemic keratoconjunctivitis. Response to double-blind corticosteroid therapy. *Arch Ophthalmol* 1970;84:36–40.
- 9 Dawson CR, Hanna L, Wood TR, Despain R. Adenovirus type 8 keratoconjunctivitis in the United States. 3. Epidemiologic, clinical, and microbiologic features. *AJOPHT* 1970;69:473–480.
- 10 Boniuk M, Phillips CA, Friedman JB. Chronic adenovirus type 2 keratitis in man. *N Engl J Med* 1965;273:924–925.
- 11 Darougar S, Quinlan MP, Gibson JA, Jones BR. Epidemic keratoconjunctivitis and chronic papillary conjunctivitis in London due to adenovirus type 19. *British Journal of Ophthalmology* 1977;61:76–85.
- 12 Pettit TH, Holland GN. Chronic keratoconjunctivitis associated with ocular adenovirus infection. *AJOPHT* 1979;88:748–751.
- 13 Kowalski RP, Thompson PP, Kington PR, Gordon YJ. Evaluation of the SmartCyber II system for real-time detection of viruses and Chlamydia from ocular specimens. *Arch Ophthalmol* 2006;124:1135–1139.
- 14 Sambursky R, Tauber S, Schirra F, et al. The RPS adeno detector for diagnosing adenoviral conjunctivitis. *Ophthalmology* 2006;113:1758–1764.
- 15 Azari AA, Barney NP. Conjunctivitis. *JAMA* 2013;310:1721–9.
- 16 Pihos AM. Epidemic keratoconjunctivitis: A review of current concepts in management. *Journal of Optometry* 2013;6:69–74.
- 17 Pelletier JS, Stewart K, Trattler W, et al. A combination povidone-iodine 0.4%/dexamethasone 0.1% ophthalmic suspension in the treatment of adenoviral conjunctivitis. *Adv Ther* 2009;26:776–783.
- 18 Clement C, Capriotti JA, Kumar M, et al. Clinical and antiviral efficacy of an ophthalmic formulation of dexamethasone povidone-iodine in a rabbit model of adenoviral keratoconjunctivitis. *Invest Ophthalmol Vis Sci* 2011;52:339–344.
- 19 Pepose JS, Ahuja A, Liu W, et al. Randomized, Controlled, Phase 2 Trial of Povidone-Iodine/ Dexamethasone Ophthalmic Suspension for Treatment of Adenoviral Conjunctivitis. *Am J Ophthalmol* 2019;205:197.
- 20 Ramakrishnan S, Vempati J, Baskaran P. Randomized, Controlled, Phase 2 Trial of Povidone-Iodine/ Dexamethasone Ophthalmic Suspension for the Treatment of Adenoviral Conjunctivitis. *Am J Ophthalmol* 2019;204:140.
- 21 Romanowski EG, Roba LA, Wiley L, et al. The effects of corticosteroids of adenoviral replication. *Arch Ophthalmol* 1996;114:581–585.
- 22 Romanowski EG, Yates KA, Gordon YJ. Topical corticosteroids of limited potency promote adenovirus replication in the Ad5/NZW rabbit ocular model. *Cornea* 2002;21:289–291.



**Stephen Gichuhi**  
Consultant  
Ophthalmologist  
& Senior Lecturer:  
Department of  
Ophthalmology,  
University of  
Nairobi, Kenya.

# HIV and the eye

People with poorly managed HIV infection have an increased risk of eye problems, including microbial keratitis, adverse drug reactions and tumours of the eye.



**Simon Arunga**  
Consultant  
Ophthalmologist  
& Lecturer:  
Department of  
Ophthalmology,  
Mbarara University  
of Science and  
Technology, Uganda.

The main ocular effects of HIV are related to immune suppression and impaired immune surveillance of tumours. HIV compromises cell-mediated immunity, thereby increasing the risk of infection with:

- bacteria (e.g., those causing tuberculosis and syphilis)
- fungi (e.g., *Candida spp.* and *Cryptococcus spp.*)
- parasites (e.g., *Toxoplasma gondii*)
- viruses (e.g., herpes zoster virus, human papillomavirus, Kaposi sarcoma-associated herpes virus, cytomegalovirus and Epstein-Barr virus).

Patients with lower CD4 counts are more likely to have ocular manifestations<sup>1</sup>; however, use of antiretroviral therapy (ART) has modified the epidemiology of ocular manifestations and variations in the predominant subtype of HIV may also lead to geographical differences in eye disease.

## Anterior lesions

### Herpes zoster ophthalmicus (HZO)

HZO is caused by reactivation of latent varicella zoster virus in the trigeminal ganglion; this is covered in detail on pp. 71–72. Within the context of HIV infection, it tends to present more severely, with a painful vesiculo-bullous rash that follows the distribution of the ophthalmic branch of the trigeminal nerve on one side of the face, without crossing the midline. In the acute phase, there is usually swelling of the eyelids. Extension of the rash on the side of the nose, due to involvement

of the nasociliary nerve (Hutchinson's sign), is often associated with intraocular inflammation and corneal denervation. This can lead to corneal ulceration and iritis (Figure 1). The rash heals with scarring and may be complicated by post-herpetic neuralgia. Reduced corneal sensation as a sequelae of HZO increases the risk of neurotrophic keratopathy, persistent epithelial defects, microbial keratitis and, ultimately, corneal scarring.

The diagnosis is usually based on clinical signs. See Table 1 (p. 78) for treatment guidelines.

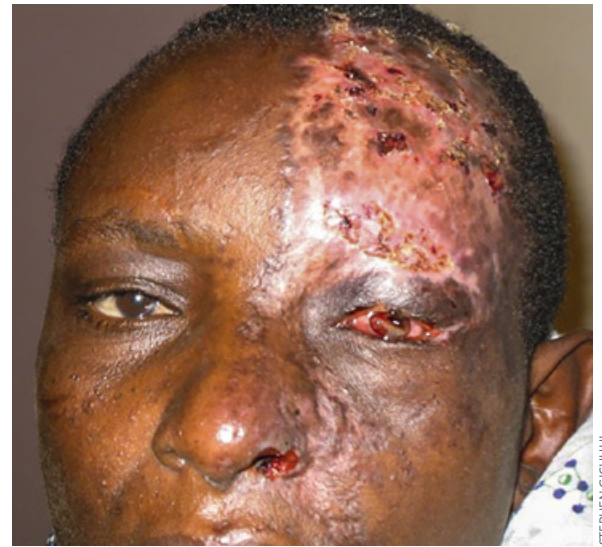### Molluscum contagiosum

Molluscum contagiosum virus belongs to the pox family of viruses. It causes raised umbilicated skin nodules which, in HIV patients, can be widespread. (Figure 2). The diagnosis is clinical, and management involves curettage with or without cryotherapy.

### Keratoconjunctivitis sicca (dry eyes)

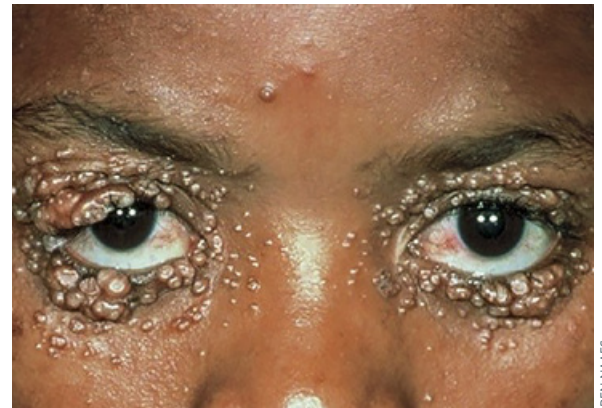Dryness of the ocular surface (not due to Sjögren's syndrome) has a reported prevalence of 11–50% among individuals with HIV/AIDS. Long-term use of ART

**Figure 1** Herpes zoster ophthalmicus with corneal ulcer perforation



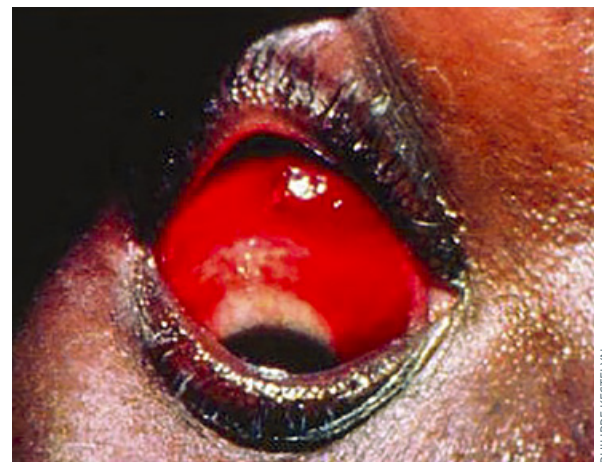STEPHEN GICHUHI

**Figure 2** Molluscum contagiosum



BEN NAKAFI

**Figure 3** Kaposi's sarcoma



PHILIPPE KESTELYN

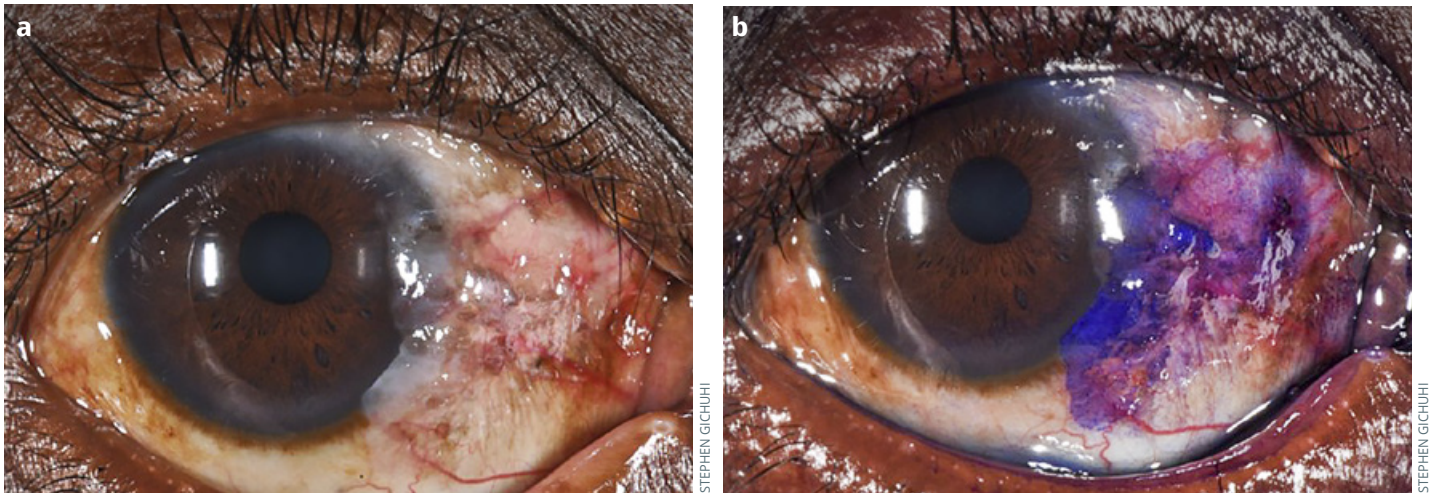
and vitamin A deficiency are believed to be the main contributors.<sup>2</sup> Ocular lubricants are helpful in relieving symptoms.

### Kaposi's sarcoma

Kaposi sarcoma appears as reddish-purple vascular tumours on the conjunctiva or lid margin. (Figure 3). The incidence has reduced with ART use. Various

**“The main ocular effects of HIV are related to immune suppression and impaired immune surveillance of tumours.”**

**Figure 4** Ocular surface squamous neoplasia (OSSN) before (a) and after toluidine blue vital staining (b)



treatments have been advocated, including local excision, focal radiotherapy, intralesional vinblastine, alpha interferon or liposomal daunorubicin.

#### **Ocular surface squamous neoplasia (OSSN)**

OSSN is a spectrum of tumours ranging from intraepithelial neoplasia to invasive squamous cell carcinoma. In Africa and Asia, most patients are young (<40 years). Africa saw a dramatic rise in incidence after the HIV pandemic started. HIV is the main risk factor, particularly in those who do not take ART. Other risk factors include exposure to ultraviolet radiation, human papilloma virus, albinism, xeroderma pigmentosum, allergic conjunctivitis and possibly cigarette smoking. Histopathology provides a definitive diagnosis. Toluidine blue 1% vital staining is a useful tool for marking the extent of tumour, guiding the excision boundaries; and for early detection of recurrences after treatment.<sup>3</sup> (Figures 4a and 4b)

Excision is the mainstay of treatment. Adjuvant therapies include cryotherapy, antimetabolites (5FU<sup>4</sup> and Mitomycin C), and radiation. For orbital spread, external beam radiotherapy and/or exenteration may be considered. Primary therapy with antimetabolites and interferons is gaining popularity but is lacking in robust clinical evidence at present.

#### **Microbial keratitis**

Microbial keratitis, can be caused by bacteria, viruses, protozoa, and fungi. It is characterised by eye pain, conjunctival hyperemia and corneal ulceration with a stromal inflammatory cell infiltrate. HIV-positive patients are at higher risk of developing microbial keratitis, which is usually characterised by rapid progression, slow response to treatment and poor outcomes.<sup>5</sup> Treatment focuses on identifying the causative agent and starting effective antimicrobial therapy. A detailed management approach has been described in previous issues of this journal.<sup>6</sup> For fungal keratitis, natamycin 5% is currently the preferred option for filamentous fungi, whilst amphotericin B is the drug of choice for candida infections. Topical antibiotics remain the best treatment for bacterial keratitis, with good response to fluoroquinolones, aminoglycosides and cephalosporins, depending on the local antimicrobial susceptibility patterns.

#### **Uveitis, including immune reconstitution uveitis**

Uveitis in HIV patients often has an infectious aetiology, with the most common causes being herpes simplex virus and the bacteria responsible for tuberculosis and syphilis. Treatment includes topical, sub-Tenon's or intravitreal steroids, cycloplegia, and antimicrobial therapy for the underlying infection.

Immune reconstitution uveitis (IRU) presents with vitritis, cystoid macula oedema, epiretinal membranes, angiitis, papillitis or neovascularisation. It was first described in AIDS patients with CMV retinitis whose CD4 lymphocyte count rose from  $\geq 50$  cells/ $\mu$ L to  $\geq 100$  cells/ $\mu$ L after starting highly active antiretroviral therapy (HAART). It is not common in non-CMV eyes and may be due to CMV infection breaking the blood-ocular barrier, thereby exposing the CMV antigen to an improved T-lymphocyte response. Treatment of IRU involves intravitreal steroids and anti-CMV therapy.

#### **Cataract**

Cataract occurs earlier in HIV-infected patients, possibly because HIV causes early biological ageing.<sup>7</sup> Cataract surgery in these patients is safe and effective.

#### **Posterior segment lesions**

##### **HIV retinopathy**

This microvasculopathy presents with transient cotton wool spots and does not cause visual loss. No treatment is needed.

##### **Cytomegalovirus (CMV) retinitis**

See article on pp. 79–80 of this edition

##### **Progressive outer retinal necrosis**

This is a very aggressive necrotising disease of the retina caused by varicella zoster virus (VZV), HSV 1 or 2, or CMV. It is associated with extreme immunosuppression (CD4 <50 cells/ml). See Table 1 for treatment.

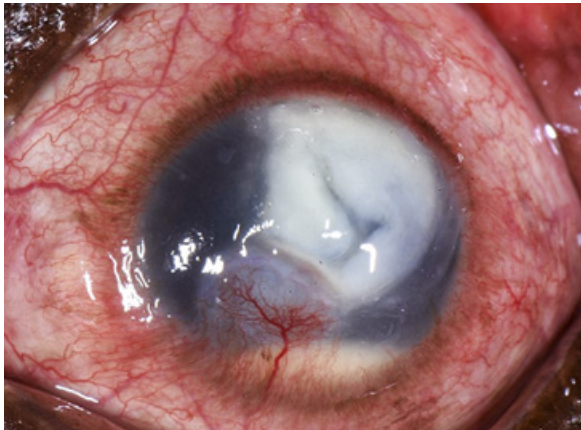
##### **Toxoplasmosis**

Retinochoroiditis caused by *Toxoplasma gondii* has an atypical presentation in HIV positive patients, displaying more fulminant disease with multifocal lesions, more vitritis ('headlight in the fog' appearance), bilateral disease, orbital cellulitis, neuro-retinitis and association with central nervous system disease, especially with

*Continues overleaf* ►

**“Cataract occurs earlier in HIV-infected patients, possibly because HIV causes early biological ageing.”**

**Figure 5** Candida microbial keratitis with hypopyon



central nervous system toxoplasmosis and neurosyphilis. A unique neuro-retinal disorder was described in a US study as manifesting with decreased contrast sensitivity, abnormal perimetry and loss of retinal nerve fibre layer, associated with increased mortality.<sup>8</sup>

### Adverse drug reactions

Stevens-Johnson syndrome and toxic epidermal necrolysis (SJS/TEN) is an acute inflammatory vesiculobullous reaction of the skin and mucous membranes that also presents with marked bilateral conjunctival injection, discharge, chemosis and symblepharon. The patient looks like she or he has burns. The exact pathophysiology is not understood. In Africa, a high percentage of SJS/TEN patients are HIV positive and the majority will develop chronic ocular complications such as symblepharon, trichiasis, subconjunctival fibrosis, corneal scarring and vascularisation. SJS/TEN may be precipitated by drugs (e.g., sulfonamides and other antibiotics, anticonvulsants, isoniazid and – of particular relevance in the context of HIV – antiretroviral drugs).

Treat using topical steroids, with supportive measures such as ocular lubrication and pain control. If indicated and available, intravenous immunoglobulin G with plasma exchange may be considered. Scleral lenses can be used to prevent symblepharon, and mucous membrane grafts may be indicated.

### Conclusion

Although provision of ART and cotrimoxazole prophylaxis are subsidised worldwide, HIV-related ocular diseases remain an important cause of visual

lesions near the optic disc. Treatment for ocular toxoplasmosis should be given in consultation with a physician as part of the management of the systemic HIV infection. The possible treatment regimens are:

- Pyrimethamine (avoid in pregnancy or if breastfeeding) with folinic acid (to minimise bone marrow toxicity of pyrimethamine) in combination with sulfadiazine (or clindamycin)
- Azithromycin is a possible alternative to the above treatment
- Prednisolone may be considered once the infection is under control.

### Neuro-ophthalmic disease

Various neuro-ophthalmological disorders occur in people living with HIV, including ocular motility disorders and palsies, visual field defects and optic neuropathy. Papilloedema also occurs secondary to cryptococcal meningitis, tuberculous meningitis,

### References

- 1 Bekele S, Gelaw Y, Tessema F. Ocular manifestation of HIV/AIDS and correlation with CD4+ cells count among adult HIV/AIDS patients in Jimma town, Ethiopia: a cross sectional study. BMC ophthalmology 2013; 13(1): 20.
- 2 Schaftenaar E, Khosa NS, Baarsma GS, et al. HIV-infected individuals on long-term antiretroviral therapy are at higher risk for ocular disease. Epidemiology and infection 2017; 145(12): 2520-9.
- 3 Gichuhi S, Macharia E, Kabiru J, et al. Toluidine Blue 0.05% Vital Staining for the Diagnosis of Ocular Surface Squamous Neoplasia in Kenya. JAMA ophthalmology 2015; 133(11): 1314-21.
- 4 Gichuhi S, Macharia E, Kabiru J, et al. Topical fluorouracil after surgery for ocular surface squamous neoplasia in Kenya: a randomised, double-blind, placebo-controlled trial. The Lancet Global Health 2016; 4(6): e378-e85.
- 5 Arunga S, Kwaga T, Leck A, Hu VH, Burton MJ. Bilateral Candida keratitis in an HIV patient with asymptomatic genitourinary candidiasis in Uganda. Medical mycology case reports 2018; 22: 14-7.
- 6 Arunga S, Burton M. Emergency management: microbial keratitis. Community eye health 2018; 31(103): 66.
- 7 Pathai S, Lawn SD, Weiss HA, Cook C, Bekker LG, Gilbert CE. Increased ocular lens density in HIV-infected individuals with low nadir CD4 counts in South Africa: evidence of accelerated aging. Journal of acquired immune deficiency syndromes (1999) 2013; What is the basis for your 87 sample size? (3): 307-14.
- 8 Jabs DA, Drye L, Van Natta ML, Thorne JE, Holland GN. Incidence and long-term outcomes of the human immunodeficiency virus neuroretinal disorder in patients with AIDS. Ophthalmology 2015; 122(4): 760-8.

**Table 1** Guidelines for treatment of HIV-related ocular diseases discussed in this article

Condition	Treatment
	Ophthalmic treatment should form part of a multi-disciplinary strategy with infectious disease or HIV specialists, particularly for systemic treatment, including ART
<b>HZO</b>	<ul style="list-style-type: none"> <li>• Antivirals e.g., aciclovir or famciclovir (either intravenously or orally: check renal function and give appropriate dose for weight)</li> <li>• For iritis, use topical steroids and cycloplegics</li> <li>• Treat high IOP (e.g., with Gutt Timolol 0.5% twice a day). (If IOP &gt; 30 mmHg, use oral acetazolamide 250mgs four times a day for 7-10 days)</li> <li>• See article on pp. 71–72.</li> </ul>
<b>CMV retinitis</b>	<ul style="list-style-type: none"> <li>• See article on pp. 79–80</li> </ul>
<b>Progressive outer retinal necrosis</b>	<ul style="list-style-type: none"> <li>• Aciclovir intravenous (IV) initially, then orally for 6 weeks</li> </ul>
<b>Toxoplasmosis</b>	<ul style="list-style-type: none"> <li>• Pyrimethamine (avoid in pregnancy or if breastfeeding)</li> <li>• Folinic acid to minimise bone marrow toxicity of pyrimethamine</li> <li>• Clindamycin with sulfadiazine</li> <li>• Azithromycin monotherapy</li> <li>• Prednisolone orally may be considered</li> </ul>
<b>SJS/TEN</b>	<ul style="list-style-type: none"> <li>• Topical steroids, with supportive measures such as ocular lubrication, scleral lenses to prevent symblepharon, mucous membrane grafts and pain control</li> <li>• Intravenous immunoglobulin G with plasma exchange.</li> </ul>



**Jonel Steffen**  
Vitreoretinal and  
uveitis consultant:  
University of Cape  
Town, Cape Town,  
South Africa.



**James Rice**  
Vitreoretinal  
consultant:  
University of Cape  
Town, Cape Town,  
South Africa.

# Cytomegalovirus: clinical features and management

CMV retinitis is the most common cause of vision loss in patients with acquired immunodeficiency syndrome (AIDS). Early recognition and management by a multidisciplinary team are essential.

Cytomegalovirus (CMV) retinitis is the most common opportunistic infection of the eye, usually occurring in HIV-positive patients with CD4 counts <50 cells/ $\mu$ l.

## Clinical features

Patients with CMV retinitis present with unilateral or bilateral visual loss and/or floaters, without any pain. There is usually minimal or no vitritis and a clear view of the retina.

There are three clinical forms of CMV retinitis:

- 1 Fulminant:** There are dense, white, well-demarcated areas of retinal necrosis with retinal haemorrhages, often described as a “pizza pie” appearance (Figure 1a). It tends to occur along the vascular arcades and over weeks gradually extends along the vessels in a ‘bushfire-like’ pattern. It may also affect the optic nerve head.
- 2 Indolent:** Mild, granular opacification of the retina with very few retinal haemorrhages, which starts in the retinal periphery and progresses slowly.
- 3 Frosted branch angiitis:** The least common form, in which perivascular exudation is the most obvious feature (Figure 1b).

## Diagnosis

The diagnosis is usually made clinically by dilated fundoscopy. The most common differential diagnoses include necrotising herpetic retinitis caused by herpes simplex (HSV) or varicella zoster virus (VZV), as well as toxoplasmosis gondii and syphilis. If the clinical diagnosis is uncertain, then syphilis serology and an aqueous or vitreous sample sent for polymerase chain reaction (PCR) for CMV, HSV, VZV and *Toxoplasma gondii* is helpful. If HIV status is unknown, then perform HIV serology, CD4 count and viral load. CMV retinitis is an AIDS-defining illness in HIV positive patients.

## Treatment

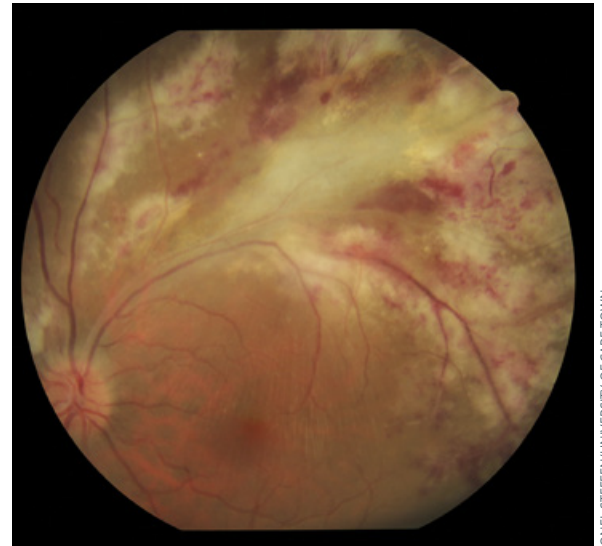
Patients with CMV retinitis should be managed by a multidisciplinary team including an ophthalmologist and a physician or infectious disease specialist. Anti-CMV treatment (intravitreal and/or systemic) is given by the ophthalmologist, whilst the physician or infectious disease specialist should start antiretroviral treatment and help with monitoring and treatment of any side-effects of the medication.

antiretroviral treatment and help with monitoring and treatment of any side-effects of the medication.

## Systemic anti-CMV treatment

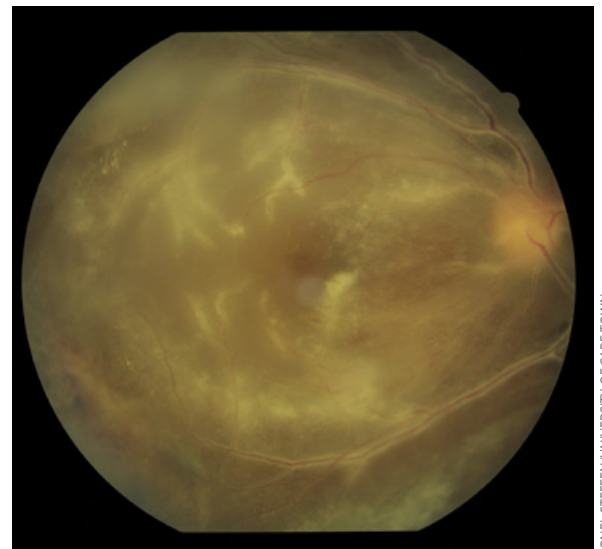
Oral valganciclovir (induction dose 900 mg twice-daily for 14–21 days, followed by maintenance dose of

**Figure 1a** Fulminant CMV retinitis



JONEL STEFFEN/UNIVERSITY OF CAPE TOWN

**Figure 1b** Frosted branch angiitis



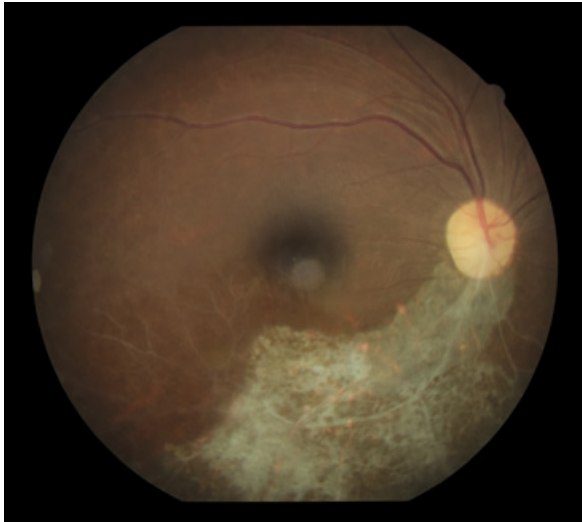
JONEL STEFFEN/UNIVERSITY OF CAPE TOWN

**“Patients with CMV retinitis should be managed by a multidisciplinary team including an ophthalmologist and a physician or infectious disease specialist.”**

900 mg daily) is the CMV treatment of choice because of its ease of administration. The disadvantage is that monitoring for bone marrow suppression and renal toxicity is required routinely to detect these adverse effects. It is also expensive and not available in all centres.

Intravenous ganciclovir (induction dose 5 mg/kg every 12 hours for 14–21 days, followed by maintenance dose of 5 mg/kg/day) can be used as an alternative, but this requires inpatient treatment for the intravenous therapy. All patients who have sight-threatening CMV

*Continues overleaf* ➤

**Figure 2** Inactive CMV retinitis

CMV treatment (intravitreal or systemic) may be stopped when all the following criteria are met<sup>1</sup>:

- 1 CMV retinitis is completely inactive.
- 2 Patient is on ART with CD4 count of > 100 cells/ $\mu$ l or CD4 count that has increased by 50 cells/ $\mu$ l above baseline.
- 3 Patient has received at least three months of CMV treatment.

At our unit, we sometimes stop intravitreal injections before three months if criteria 1 and 2 are met, and we then monitor for any recurrences at one, three and seven weeks before discharging the patient.

#### Reference

- 1 Jacobson MA, Heiden D. Treatment of AIDS-related cytomegalovirus retinitis <https://www.uptodate.com> (accessed 28 Aug 2019).

retinitis (infection within 1 disc diameter of the fovea or optic disc) should also receive weekly intravitreal ganciclovir injections for the first two weeks (see below for details).

#### Intravitreal anti-CMV treatment

Weekly injections of intravitreal ganciclovir (2.5 mg in 0.1 ml) into the affected eye/s is the treatment of choice in many resource-limited units. It is inexpensive and can be given as an outpatient treatment. The disadvantages are that it does not protect the fellow eye or treat systemic CMV infection, requires trained and experienced clinicians, and carries the low – but potentially sight-threatening – risks associated with intravitreal injections, such as endophthalmitis.

#### Antiretroviral treatment (ART)

Ideally, ART should be started two weeks after starting CMV treatment to reduce the risk of immune recovery uveitis, but it may be more appropriate to start both at the same time in resource-limited settings.

A complete discussion of all the treatment options is beyond the scope of this article and can be found at UpToDate.<sup>1</sup>

#### Follow-up and complications

We advise the use of fundus photographs to monitor treatment response. Initially, patients should be assessed weekly. Inactive CMV lesions will stay the same size, become less opacified and retinal haemorrhages will resolve (Figure 2).

CMV scars have areas of thin, necrotic retina which may form holes and lead to rhegmatogenous retinal detachments; these require pars plana vitrectomy and silicone oil tamponade.

15 October  
**2020**  
Singapore

IAPB

# INAUGURAL WORLD OPHTHALMIC NURSING FORUM

This event is supported by ophthalmic nursing associations and networks around the world

It will offer **nurses the first opportunity to meet** on the global stage, and network with a wide range of colleagues across global eye care

**The Forum is free** to nurses who register to attend the IAPB Global Assembly scheduled for the **12-14 October 2020**

**Registrations and abstract submissions will open in early 2020**

Find out more: [communications@iapb.org](mailto:communications@iapb.org)

**IAPB.ORG/GA2020**

GA2020  
Global Assembly  
Singapore

Photo by Frano Loois • IAPB Registered Charity No: 110559. Company Limited by Guarantee No: 4620869 • Registered in England and Wales





**Gerry Clare**  
Ophthalmologist  
with Médecins sans  
Frontières in Liberia  
during the 2014  
Ebola outbreak.

# Ebola and the eye

Survivors of Ebola virus infection may present late with a spectrum of ocular manifestations, ranging from mild retinal scarring to complete bilateral blindness resulting from tractional retinal detachment, cataract and glaucoma secondary to intraocular inflammation.

An infectious disease specialist's brush with death during the 2014 Ebola crisis in West Africa proved instructive to ophthalmologists.<sup>1</sup> On becoming severely ill with signs of having contracted Ebola virus disease (EVD), the doctor was evacuated to an isolation facility in the United States for supportive care, where he eventually recovered. A few weeks later, he noticed blurring of vision, pain and redness in one eye, and was diagnosed with uveitis. An aqueous sample from the affected eye was sent for analysis, and polymerase chain reaction (PCR) assay demonstrated the presence of replicating Ebola virus.

## **Ebolavirus and other viruses causing uveitis**

Of the six species in the *Ebolavirus* (EBOV) genus, four infect humans, causing an acute haemorrhagic fever that is associated with very high case fatality. The finding of replicating Ebola virus in aqueous is not surprising; Marburg virus, a member of the same *Filoviridae* family (enveloped, filamentous virions with a negative sense RNA genome), had been isolated from the intraocular fluid of infected persons several years before.<sup>2</sup> Moreover, in previous outbreaks, Ebola virus infection had been noted to precipitate uveitis in a minority of survivors.<sup>3</sup> In addition, *Flaviviridae* such as Zika, Dengue and West Nile viruses, and *Togaviridae* such as Chikungunya also cause intraocular inflammation.<sup>4</sup>

## **Ocular complications of Ebola virus disease**

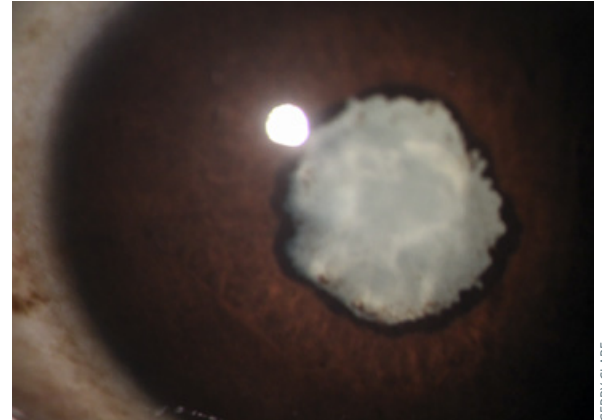
Ocular complications form part of post-Ebola virus disease syndrome, which also includes symptoms of joint and muscle pain and sometimes neurological problems.

A longitudinal study in Liberia established that EVD survivors have a significantly higher incidence of uveitis

than a control group of close contacts.<sup>4</sup> Uveitis is the most common ocular complication of EVD, affecting nearly one third of people recovering from EVD.

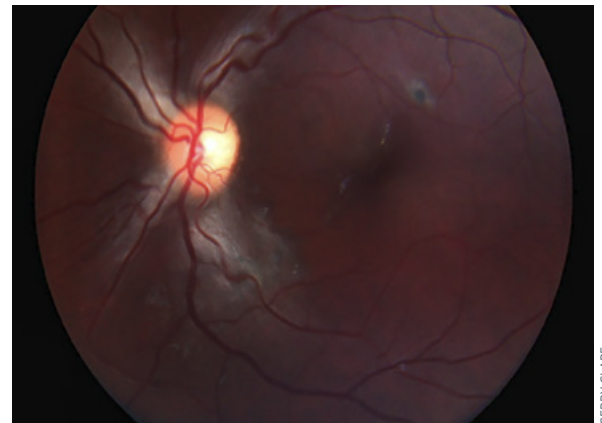
A range of signs are possible, including non-granulomatous anterior uveitis, posterior synechiae, iris atrophy, vitreous inflammation, chorioretinal scarring, panuveitis and optic neuropathy. These findings reflect direct viral invasion of the normally immune-privileged intraocular space. Inflammation can range from mild to severe, causing raised intraocular pressure, cataract (Figure 1), tractional

**Figure 1** A dense white cataract masking a tractional retinal detachment in a young Liberian female Ebola survivor. Note the irregular pupil margin, indicating posterior synechiae. She was blind in both eyes.



GERRY CLARE

**Figure 2** A small pigmented scar with a hypopigmented halo is all that remains to indicate past ocular inflammation in this young Ebola survivor.



GERRY CLARE

retinal detachment and phthisis, and may affect both eyes, causing visual impairment or complete blindness.<sup>5</sup>

A variety of chorioretinal lesions may be found in survivors, such as pigmented retinal scars with a hypopigmented halo (Figure 2).<sup>6</sup> In a study of 50 survivors, no evidence of viral persistence in the eye was found at a median of 19 months after diagnosis, indicating that cataract surgery could be undertaken safely.<sup>7,8</sup>

## **Management of uveitis resulting from Ebola**

Treatment options include topical or systemic ocular antihypertensives, cycloplegic and mydriatic agents for analgesia and to prevent synechiae, and topical corticosteroids.

The role of antiviral drugs in eliminating intraocular infection with Ebola virus is currently being evaluated.

## **Implications**

In those recovering from Ebola infection, the finding of treatable eye disease which can lead to visual impairment has two implications for organisations providing health care to Ebola survivors.

*Continues overleaf* ►

**“Ocular complications form part of post-Ebola virus disease syndrome, which also includes symptoms of joint and muscle pain and sometimes neurological problems.”**

## 1. Offer follow-up eye examinations to all Ebola survivors

Health care workers should be prepared to assess the eye, which should include:

- Assessing vision
- Examining the fundus
- Measuring intraocular pressure.

Health workers can use a smartphone app to measure visual acuity, with the addition of a camera adaptor clip to visualise the fundus.<sup>9</sup> With training, intraocular pressure can be measured using portable instruments.

## 2. Develop treatment and referral pathways

Adequate treatment and referral pathways should be

developed, potentially using retinal images for remote consultation with an ophthalmologist.

Happily, the infectious disease specialist who developed Ebola uveitis partially recovered his vision, but others are not so lucky.

Recent Ebola outbreaks have had the unexpected effect of exposing the striking shortage of ophthalmic services available in affected communities, as well as the lack of preparedness to deal with its ophthalmic consequences. For instance, some clinicians have been reluctant to treat survivors with cataract due to unfounded fears over persisting infection. This adds to the already overwhelming burden on health services in countries struggling with the aftermath of an Ebola epidemic.

### References

- 1 Varkey JB, Shantha JG, Crozier I, et al. Persistence of Ebola virus in ocular fluid during convalescence. *N Engl J Med*. 2015;372(25):2423-2427.
- 2 Gear JS, Cassel GA, Gear AJ, et al. Outbreak of Marburg virus disease in Johannesburg. *Br Med J*. 1975;4:489-493.
- 3 Kibadi K, Mupapa K, Kuvula K, et al. Late Ophthalmologic Manifestations in Survivors of the 1995 Ebola Virus Epidemic in Kikwit, Democratic Republic of the Congo. *J Infect Dis*. 1999;179:513-514
- 4 Merle H, Donnio A, Jean-Charles A, et al. Ocular manifestations of emerging arboviruses: Dengue fever, Chikungunya, Zika virus, West Nile virus, and yellow fever. *J. Fr. Ophthalmol*. 2018;41: e235-e243.
- 5 Preval III Study Group. A longitudinal study of Ebola sequelae in Liberia. *N Engl J Med*. 2019;380(10):924-34.
- 6 Yeh S, Shantha JG, Hayek B, et al. Clinical Manifestations and Pathogenesis of Uveitis in Ebola Virus Disease Survivors. *Ocul Immunol Inflamm*. 2018;26:1128-1134.
- 7 Steptoe PJ, Scott JT, Baxter JM, et al. Novel Retinal Lesion in Ebola Survivors, Sierra Leone, 2016. *Emerg Infect Dis*. 2017;23(7):1102-1109.
- 8 Shantha JG, Mattia JG, Goba A, et al. Ebola Virus Persistence in Ocular Tissues and Fluids (EVICT) Study: Reverse Transcription-Polymerase Chain Reaction and Cataract Surgery Outcomes of Ebola Survivors in Sierra Leone. *EBioMedicine*. 2018;30:217-224.
- 9 Bastawrous A, Rono HK, Livingstone IAT, et al. Development and Validation of a Smartphone-Based Visual Acuity Test (Peek Acuity) for Clinical Practice and Community-Based Fieldwork. *JAMA Ophthalmol*. 2015;133(8):930-937.





  
**12 – 14**  
**October**  
**2020**  
Singapore

# ACT NOW

## EYE HEALTH FOR ALL

Join IAPB's **Global Assembly 2020** – where public health meets eye health. This 2020, come to **Singapore** and forge a new future for eye care.

**IAPB.ORG/GA2020**

Local organising partner  



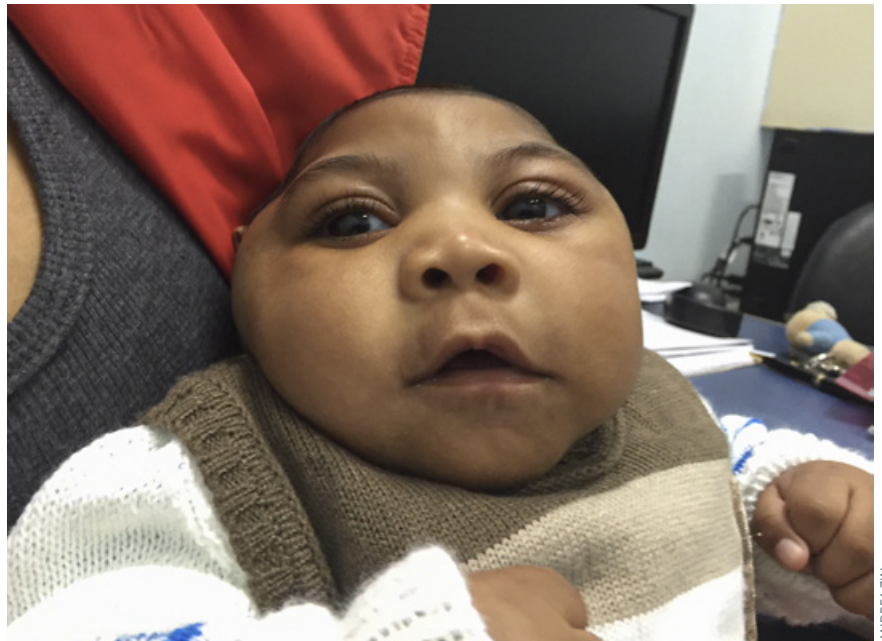**Olivia A Zin**  
Universidade  
Federal de São  
Paulo-UNIFESP  
São Paulo, Brazil.



**Andrea Zin**  
Instituto Fernandes  
Figueira-FIOCRUZ  
Rio de Janeiro, Brazil.

# Zika infection and the eye

If a woman becomes infected with the Zika virus while pregnant, the virus can cross the placenta and infect the baby, causing abnormalities of the eyes and the rest of the body. A detailed eye examination is essential.



**Figure 1** Child with congenital Zika syndrome and microcephaly

**“Reports of Zika virus have increased recently, with cases being reported in new countries outside of Africa.”**

## Natural history and transmission

Zika virus (ZIKV) is a flavivirus (genus *Flavivirus*), first isolated in 1947 from a monkey in the Zika forest of Uganda. The virus is endemic in areas of Africa and Asia.

The virus can be spread by *Aedes* mosquitoes (which are active in the daytime) or via sexual contact, infected blood and trans-placental transmission in utero.<sup>1</sup>

People carrying the virus can introduce Zika virus into new countries; however, *Aedes* mosquitoes are required to continue local transmission.

Reports of Zika virus have increased recently, with cases being reported in new countries outside of Africa. In early 2015, Zika infection was confirmed in Brazil, causing a large outbreak due to the lack of immunity in the population and the abundance of *Aedes aegypti* mosquitos.<sup>2</sup>

## Clinical features of acute infection

Most people infected with Zika virus are asymptomatic. Those who have symptoms may complain of mild fever, rash, painful joints and muscles, headache and conjunctivitis. Rarely, patients may develop acute uveitis and/or a maculopathy which is characterised by macular retinal pigment epithelium (RPE) changes with a grey annulus around the fovea on posterior segment examination and disruption of outer retinal and RPE integrity, as evidenced by an optical coherence tomography OCT scan.<sup>3-5</sup>

The Zika virus may be found in tears, therefore good hand hygiene to prevent person-to-person contamination is important.

## Congenital Zika syndrome

If a woman becomes infected with the Zika virus while pregnant, then the virus can cross the placenta and infect the unborn foetus. This results in congenital Zika syndrome (CZS), which consists of a spectrum of clinical manifestations observed in babies who have been exposed to Zika virus while in utero.

The main features are severe microcephaly with partially collapsed skull (Figure 1) and brain abnormalities (thin cerebral cortex and subcortical calcification). In the skeleton, there may be congenital contractures, arthrogryposis or clubfoot, with increased tone in the muscles. Hearing loss may also be present.

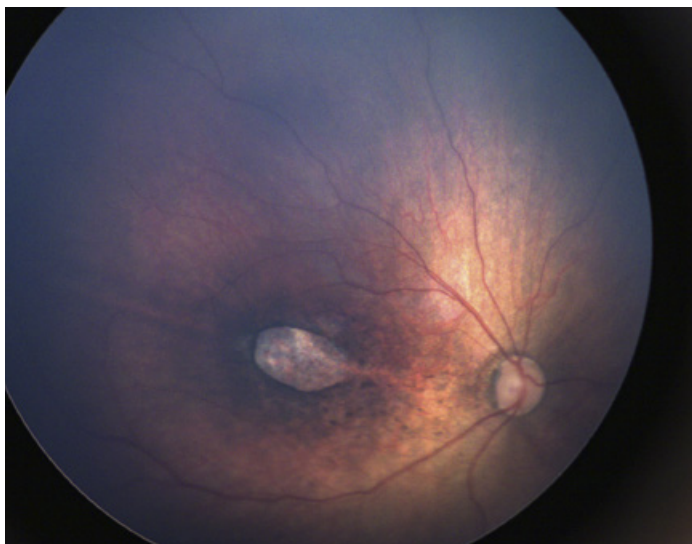
The eye abnormalities seen in CZS include retinal pigment mottling, chorioretinal atrophy, optic atrophy/hypoplasia and coloboma (Figures 2a and 2b). Other documented ocular abnormalities are microphthalmia, iris coloboma, lens subluxation, cataract, intraocular calcifications, and congenital glaucoma.<sup>6-9</sup> Children with CZS are at an increased risk of blindness because of these serious, and often untreatable, ocular and neurological abnormalities (Figure 3).<sup>10</sup>

Exposure to the virus during the first three months of pregnancy appears to be associated with more severe manifestations, although CZS may occur after maternal exposure to the virus at any point during her pregnancy.

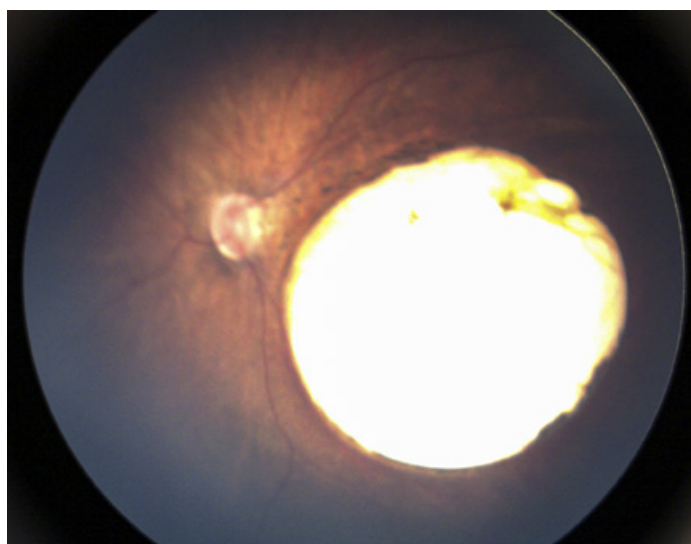## Assessment for congenital Zika syndrome

All babies born to women who may have been exposed to Zika virus during pregnancy should undergo a full clinical evaluation by a paediatrician and examination of the eye (including dilated funduscopy) by an ophthalmologist to determine if there is any evidence of CZS which will require management and follow-up.

**Figure 2a** Chorioretinal atrophy and pigment mottling



**Figure 2b** Optic nerve hypoplasia and macular coloboma



### Diagnostic tests to confirm clinical diagnosis

When the infection is acquired, most cases are asymptomatic and the symptoms, if present, are non-specific. If the patient is pregnant and concerned that she may have contracted Zika, then laboratory tests are required to confirm the infection.

Real-time polymerase chain reaction (RT-PCR) can identify the virus in blood samples 4 to 7 days after clinical onset. It is also possible to identify viral ribonucleic acid (RNA) in the urine up to 15 days after symptoms, even if the virus is no longer present in the bloodstream. Immunoglobulin (IgM) is increased between the 2nd and 12th week after clinical presentation; however, there may be cross-reactivity with other flaviviruses.

### Prevention and treatment

Zika virus infection can be prevented by avoiding mosquito bites (using mosquito repellent and mosquito nets; wearing long-sleeved shirts and trousers), particularly between sunrise and sunset, when *Aedes* mosquitoes are most active.

The risk of sexual transmission of Zika virus is reduced by using condoms when staying in an endemic area and for 8 weeks after returning from this area. If symptoms of Zika infection have been noted, then condom use is recommended for 6 months after the infection.

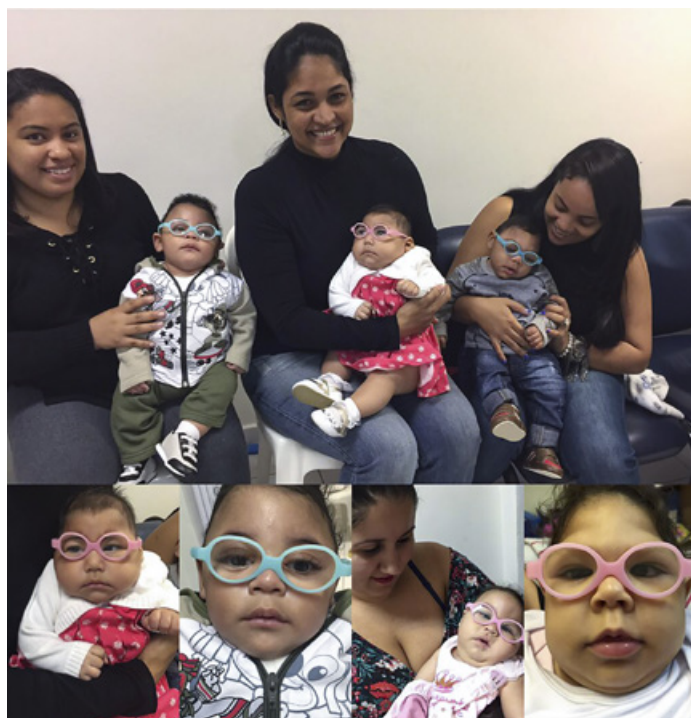Travellers returning from Zika-endemic areas should wait 28 days from their date of return before they can donate blood.

Currently, there is no specific antiviral treatment and no effective vaccine to prevent the infection.

### References

- 1 Petersen LR, Jamieson DJ, Powers AM, Honein MA. Zika Virus. *The New England Journal of Medicine* 2016; 374(16):1552-1563.
- 2 Campos GS, Bandeira A, Sardi S. Zika virus outbreak, Bahia, Brazil. *Emerg Infect Dis* 2015;21(10):1885-1886.
- 3 Furtado JM, Espósito DL, Klein TM, Teixeira-Pinto T, da Fonseca BA. Uveitis associated with Zika virus infection. *N Engl J Med* 2016; 375:394-396.
- 4 Parke DW, Almeida DR, Albin TA, Ventura CV, Berrocal AM et al. Serologically confirmed Zika-related unilateral acute maculopathy in an adult. *Ophthalmology* 2016;123: 2432-2433.
- 5 Kodati S, Palmore TN, Spellman FA, Cunningham D, Weistrop B, Sen HN. Bilateral posterior uveitis associated with Zika virus infection. *Lancet* 2017 Jan 7;389(10064):125-126.

**Figure 3** Children with congenital Zika syndrome wear magnifying glasses



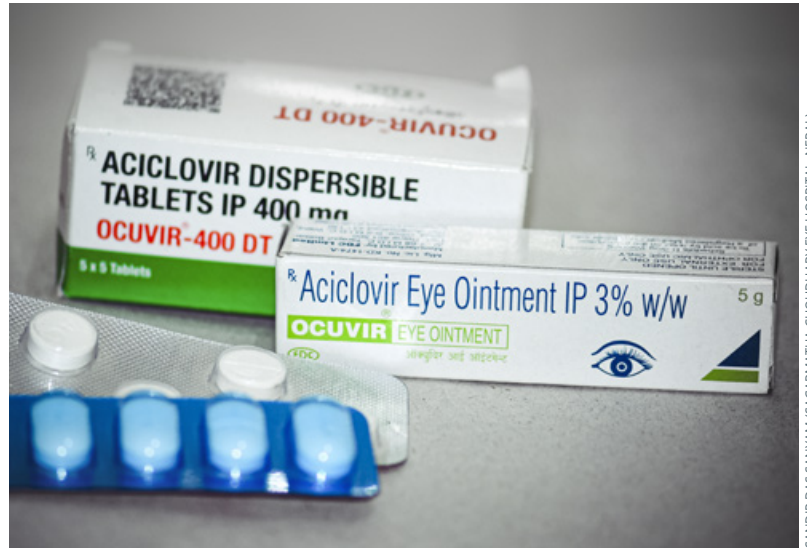- 6 Zin AA, Tsui I, Rossetto J, Vasconcelos Z, Adachi K, Valderramos S, Halai UA, Pone MVDS, Pone SM, Silveira Filho JCB, Aibe MS, da Costa ACC, Zin OA, Belfort R Jr, Brasil P, Nielsen-Saines K, Moreira MEL. Screening Criteria for Ophthalmic Manifestations of Congenital Zika Virus Infection. *JAMA Pediatr* 2017;171(9):847-854.
- 7 Brasil P, Pereira JP Jr, Moreira ME, et al. Zika virus infection in pregnant women in Rio de Janeiro. *N Engl J Med* 2016;375(24):2321-2334.
- 8 Ventura CV, Maia M, Bravo-Filho V, Góis AL, Belfort R Jr. Zika virus in Brazil and macular atrophy in a child with microcephaly. *Lancet* 2016; 387(10015):228.
- 9 de Paula Freitas B, de Oliveira Dias JR, Prazeres J, Sacramento GA, Ko AI, Maia M, et al. Ocular findings in infants with microcephaly associated with presumed Zika virus congenital infection in Salvador, Brazil. *JAMA Ophthalmol* 2016; 134:529-535.
- 10 Zin AA, Tsui I, Rossetto JD, Gaw SL, Neves LM, Zin OA, et al. J AAPOS. Visual function in infants with antenatal Zika virus exposure *J AAPOS* 2018;22(6):452-456.e1.



**Jeremy Hoffman**  
Clinical Research  
Fellow: International  
Centre for Eye Health,  
London School of  
Hygiene & Tropical  
Medicine, UK.

# Overview of antiviral medications used in ophthalmology

As eye health professionals, we are fortunate to have a number of antiviral medications available in our armoury to treat a range of ophthalmic viral infections. This article provides an overview of what antiviral agents are available for these conditions, detailing their regimen and evidence that supports their use.



Aciclovir – either as topical eye ointment or systemic tablets – is still the first-line antiviral in the treatment of many viral eye diseases around the world, including here in Nepal.

Ophthalmic viral infections, particularly herpes simplex keratitis, have been at the forefront of the development of antiviral medications.

The discovery of the first targeted antiviral agent, in common with penicillin (the first antibiotic), owes much to serendipity. In 1959, William Prusoff developed idoxuridine (IDU) as a potential systemic anti-cancer agent. Idoxuridine

proved to be too toxic as a systemic agent; however, its mechanism of action – selectively blocking DNA synthesis – proved to be a successful strategy in the topical treatment of herpes simplex virus (HSV), a DNA virus.<sup>1</sup>

By 1962, Herbert Kaufman had introduced idoxuridine (IDU) to the world as the first antiviral drug to successfully treat a

human viral infection: herpes simplex keratitis.<sup>2</sup>

For the next decade, idoxuridine was the treatment of choice for epithelial herpes simplex keratitis. However, this was not perfect as it was frequently

associated with toxicity, including superficial punctate keratopathy, chemical conjunctivitis, punctal occlusion and occasional serious hypersensitivity reactions. Idoxuridine was also unable to penetrate the corneal epithelium to treat stromal or endothelial keratitis.

With the advent of aciclovir in 1982, most herpetic ophthalmic infections became treatable, including those caused by herpes zoster.<sup>3</sup> Since then, a number of newer antivirals with similar mechanisms of action have been developed, including ganciclovir, famciclovir, valaciclovir and valganciclovir, which work in a variety of ways to inhibit the synthesis of viral DNA and thereby stop viral replication. The addition of foscarnet, which acts as DNA polymerase inhibitor, has enabled ophthalmologists to add cytomegalovirus (CMV) retinitis to the list of treatable ophthalmic viral infections. However, despite a number of attempts and potential agents, there has been limited progress in developing antiviral treatment for adenovirus.

This article provides a summary of the current ophthalmic antiviral agents that are available to treat anterior and posterior segment viral infections.

**“By 1962, Herbert Kaufman had introduced idoxuridine (IDU) to the world as the first antiviral drug to successfully treat a human viral infection: herpes simplex keratitis.”**

## Antivirals acting on anterior segment viral infections

### Herpes simplex epithelial keratitis

Herpes simplex epithelial keratitis can be treated effectively with either topical aciclovir, ganciclovir or trifluridine, as detailed below (Table 1).

The choice of agent will depend on local availability, cost and patient factors.

Oral treatment may be preferable in patients who have

ocular surface disease or a poor tear film.

Avoid systemic treatment in patients known to have poor renal function.

Vidarabine 3% ointment has been withdrawn from UK and US markets, but it may still be an option in some low- and middle-income countries. It can be used 5 times a day until the epithelium has healed.

**Table 1** Antiviral treatment for herpes simplex epithelial keratitis

Drug	Dose / regimen	Comment
<b>Topical aciclovir (ACV)</b>	Aciclovir 3% ointment, five times a day for seven days, then three times a day for seven days <sup>4</sup>	Specific for viral-infected cells only; not available in USA and some supply issues elsewhere Resistance may be increasing in immunocompromised patients (10%) <sup>5</sup>
<b>Systemic aciclovir (ACV)</b>	Aciclovir 400 mg orally, five times a day for 7–10 days <sup>4</sup>	As effective as topical aciclovir <sup>6</sup> ; toxicity is rare but requires normal renal function
<b>Topical ganciclovir (GCV)</b>	Ganciclovir 0.15%, 5 times daily until the ulcer has healed, then three times a day for seven days <sup>4,7</sup>	Increasing usage in UK and Europe due to aciclovir supply issues; as good as topical aciclovir for herpes simplex epithelial keratitis
<b>Topical trifluridine (TFT)</b>	Trifluridine 1% solution, 4–8 times a day <sup>4,8</sup>	First-line therapy in the USA; as effective as topical aciclovir
<b>Topical idoxuridine (IDU)</b>	Idoxuridine 0.5% ointment or IDU 1% solution, five times a day <sup>1,4</sup>	First topical antiviral; usage superseded by aciclovir, ganciclovir and trifluridine

### Herpes simplex stromal keratitis

Topical steroids in combination with either topical trifluridine **OR** topical aciclovir **OR** systemic aciclovir is better than treatment with antivirals alone (Table 2).

There may be some benefit of adding oral aciclovir to a course of topical steroids and topical anti-viral (trifluridine or aciclovir) for HSV-1 iritis.

At present there is little evidence for the use of ganciclovir 0.15% in the treatment of herpes simplex keratitis in combination with topical corticosteroids, and there are no randomised controlled trials comparing its efficacy to aciclovir or trifluridine. Despite this, it is likely to be of clinical value if alternatives are not available or tolerated.

**Table 2** Antiviral treatment options for herpes simplex stromal keratitis. Note that these are all in addition to topical corticosteroids

Drug	Dose / regimen	Comment
<b>Topical aciclovir</b>	Aciclovir 3% ointment, five times a day whilst using topical corticosteroids	Useful as topical antiviral cover when using topical steroid. As effective as systemic aciclovir in conjunction with topical steroids for herpes simplex keratitis <sup>6</sup>
<b>Systemic aciclovir</b>	Aciclovir 400 mg orally, five times a day for ten weeks <sup>9,10</sup>	No additional benefit when added to topical trifluridine and topical corticosteroids for herpes simplex keratitis. <sup>9,10</sup> There may be some benefit of adding oral aciclovir to topical trifluridine and topical corticosteroids in cases of HSV-1 iritis, although the study did not complete enrolment <sup>11</sup> As effective as topical aciclovir in conjunction with topical steroids for herpes simplex keratitis <sup>6</sup>
<b>Topical trifluridine</b>	Trifluridine 1% 4–8 times a day for 3 weeks <sup>9,10</sup>	Useful as topical antiviral cover when treating herpes simplex keratitis with topical corticosteroids

### Prophylaxis / prevention strategies against recurrent HSV ocular infections

There is strong evidence from the Herpes Eye Disease II (HEDS II) study<sup>12</sup> that prophylactic aciclovir 400 mg twice daily reduces the recurrence of potentially blinding herpes simplex stromal keratitis with a

relative risk reduction of 50% (Table 3).

It is important to measure renal function on an annual basis for patients who are on prophylactic aciclovir.

**Table 3** Antiviral prophylaxis for the prevention of re-activation of HSV ocular infections

Drug	Dose / regimen	Comment
<b>Systemic aciclovir</b>	Aciclovir 400 mg orally twice a day	There is strong evidence <sup>12</sup> that the use of prophylactic systemic aciclovir reduces the recurrence of: Any form of ocular HSV infection (19% aciclovir vs. 32% control; $p < 0.001$ ) Herpes simplex keratitis specifically (14% aciclovir vs. 28% control; $p < 0.005$ )

Continues overleaf ►

## Herpes zoster ophthalmicus (varicella zoster virus)

Oral aciclovir 800 mg five times a day for seven days remains the most widely used, affordable and available treatment for herpes zoster. It is important to start this as soon as possible; there is limited evidence of its efficacy if started more than 72 hours after the rash develops for non-ocular involvement (Table 4).

Topical antivirals (aciclovir or ganciclovir) may have

a supplementary role in the presence of dendritic or pseudo-dendritic keratitis but should not be used on their own.

Topical corticosteroids should be used in the presence of stromal keratitis or iritis, and can be started in the presence of pseudo-dendrites.

Newer oral antivirals such as valaciclovir or famciclovir have better bioavailability and dosing regimes, but availability and cost remain barriers to their use globally.

**Table 4** Antiviral treatment options for herpes zoster ophthalmicus (caused by varicella zoster virus)

Drug	Dose / regimen	Comments and evidence for use
<b>Systemic aciclovir</b>	Aciclovir 800 mg orally five times a day for seven days	For non-ocular involvement at onset, treatment must start within 72 hours of onset of blisters in order to alter disease course <sup>13</sup> For ocular disease, start as soon as possible Antiviral treatment reduces the risk of chronic ocular complications from 30% to 20% <sup>14</sup> Reduces duration of pain due to post-herpetic neuralgia (PHN) by 50% although no reduction in risk of developing PHN <sup>14</sup> Consider using intravenous aciclovir in HIV infected patients due to the risk of disseminated varicella zoster virus infection
<b>Topical aciclovir</b>	Aciclovir 3% ointment, five times a day for seven days, then twice a day until dendrites have resolved	Use in the presence of dendritic keratitis but only in addition to systemic antiviral treatment. Add a topical steroid if there is stromal disease or keratitis <sup>15</sup>
<b>Topical ganciclovir</b>	Ganciclovir 0.15%, five times a day until the ulcer has healed	Use in the presence of dendritic keratitis only in addition to systemic antiviral treatment. Add a topical steroid if there is stromal disease or keratitis
<b>Systemic valaciclovir</b>	1 g orally three times a day for seven days	Alternative to aciclovir. Higher serum concentrations following oral administration, due to better bioavailability, means more convenient dosing (3 times a day vs 5 times a day) Potentially better than aciclovir in reducing acute pain <sup>16</sup>
<b>Systemic famciclovir</b>	500 mg orally three times a day for seven days	Alternative treatment options to aciclovir. Higher serum concentrations following oral administration, due to better bioavailability, means more convenient dosing (3 times a day vs 5 times a day) Potentially better than aciclovir in reducing acute pain <sup>17</sup>

## Adenovirus ocular infections

There is currently no licensed antiviral agent for the treatment of adenoviral infections. However, a recent phase 2 randomised-controlled trial suggests benefit in using a combination of povidone-iodine 0.6% and dexamethasone 0.1% (four times a day to both eyes for five days).<sup>18</sup> The follow-up period for this study was short (only 12 days). The combination treatment is

not currently available, nor licenced. The effect of the topical steroid treatment on intraocular pressure also has to be considered.<sup>19</sup>

Povidone-iodine alone may be effective; however, further studies are required to assess this.

Other agents under investigation include ganciclovir 0.15% gel.

## Antivirals acting on posterior segment viral infections

### CMV retinitis

#### Systemic treatments

All systemic treatment must be administered in partnership with an HIV or infectious disease physician.

Oral valganciclovir is effective and easily administered.<sup>20</sup> However, it is expensive and not always available. Care must be taken to monitor renal function and full blood counts.

Alternative systemic treatments include systemic intravenous ganciclovir (Table 5).

Foscarnet<sup>21</sup> is very rarely used now because of the advent of highly active antiretroviral therapy (HAART) and the need for daily two-hour infusions via indwelling catheter.

#### Intravitreal treatment

Intravitreal ganciclovir injection is a very useful option as it can be done as an outpatient and gives high levels of concentration of the drug where it is needed. However, it does not protect the other eye or protect against systemic CMV. It should be given as adjuvant therapy if there is infection within 1 disc diameter of the fovea or optic disc.

**Table 5** Antiviral treatment options for CMV retinitis

Drug	Dose / regimen	Comments and evidence for use
<b>Systemic oral valganciclovir</b>	Induction dose: 900 mg orally twice a day for 14–21 days, followed by maintenance dose of 900 mg orally once a day until CD4 count normalises	Need to monitor full blood count and renal function due to potential bone marrow suppression and renal toxicity; expensive As effective as intravenous ganciclovir for induction and long-term therapy for CMV retinitis in HIV patients <sup>20</sup>
<b>Systemic intravenous ganciclovir</b>	Induction dose: 5 mg/kg/dose every twelve hours for 1–21 days, followed by a maintenance dose of 5 mg/kg once a day until CD4 count normalises	Need to monitor full blood count and renal function due to potential bone marrow suppression and renal toxicity. Requires hospital attendance/admission for intravenous administration. First generation antiviral; effective <sup>22</sup>
<b>Intravitreal ganciclovir</b>	2.5 mg in 0.1 ml once a week	An alternative if systemic valganciclovir or ganciclovir is not available or too expensive <sup>23</sup> All patients who have infection within 1-disc diameter of the fovea or optic disc should receive intravitreal injections Inexpensive, can be given as an outpatient Risk of endophthalmitis following intravitreal injection

### Acute retinal necrosis, progressive outer retinal necrosis

Although acute retinal necrosis (ARN) and progressive outer retinal necrosis (PORN) are different clinical entities (ARN affecting immunocompetent individuals and PORN affecting immunocompromised individuals). Both are caused by varicella zoster virus and, to a lesser extent, by HSV-1 and HSV-2.

The antivirals used to treat ARN and PORN are similar. The treatment options are:

- Initially, intravenous aciclovir (10 mg/kg three times a day) for 5–10 days, then oral aciclovir (800 mg five times a day) for 4–6 weeks
- Valaciclovir 2 g four times a day for 7–10 days, then oral valaciclovir 1 g three times a day for six weeks; this option can be given as an outpatient.

Either of these options can be combined with intravitreal foscarnet 2.4 mg (if available) which has been shown to reduce the risk of retinal detachment and hastens viral inactivity.<sup>24</sup>

### References

- Prusoff WH. Synthesis and biological activities of iododeoxyuridine, an analog of thymidine. *Biochim Biophys Acta*. 1959 Mar;32(1):295–6.
- Kaufman H, Martola EL, Dohlman C. Use of 5-iodo-2'-deoxyuridine (IDU) in treatment of herpes simplex keratitis. *Arch Ophthalmol*. 1962 Aug;68(2):235–9.
- Jones BR, Coster DJ, Fison PN, Thompson GM, Cobo LM, Falcon MG. Efficacy of acycloguanosine (Wellcome 248U) against herpes-simplex corneal ulcers. *Lancet*. 1979 Feb 3;1(8110):243–4.
- Wilhelmus KR. Antiviral treatment and other therapeutic interventions for herpes simplex virus epithelial keratitis. *Cochrane Database Syst Rev*. 2015 Jan 9;1:CD002898.
- Piret J, Boivin G. Antiviral resistance in herpes simplex virus and varicella-zoster virus infections: diagnosis and management. *Curr Opin Infect Dis*. 2016 Dec;29(6):654–62.
- Collum LM, McGettrick P, Akhtar J, Lavin J, Rees PJ. Oral acyclovir (Zovirax) in herpes simplex dendritic corneal ulceration. *Br J Ophthalmol*. 1986 Jun;70(6):435–8.
- Hoh HB, Hurlley C, Claoue C, Viswalingham M, Easty DL, Goldschmidt P, et al. Randomised trial of ganciclovir and acyclovir in the treatment of herpes simplex dendritic keratitis: a multicentre study. *Br J Ophthalmol*. 1996 Feb;80(2):140–3.
- Høvdig G. A comparison between acyclovir and trifluorothymidine ophthalmic ointment in the treatment of epithelial dendritic keratitis. A double blind, randomized parallel group trial. *Acta Ophthalmol*. 1989 Feb;67(1):51–4.
- Wilhelmus KR, Gee L, Hauck WW, Kurinij N, Dawson CR, Jones DB, et al. Herpetic Eye Disease Study. A controlled trial of topical corticosteroids for herpes simplex stromal keratitis. *Ophthalmology*. 1994 Dec;101(12):1883–95–discussion1895–6.
- Barron BA, Gee L, Hauck WW, Kurinij N, Dawson CR, Jones DB, et al. Herpetic Eye Disease Study. A controlled trial of oral acyclovir for herpes simplex stromal keratitis. *Ophthalmology*. 1994 Dec;101(12):1871–82.
- A controlled trial of oral acyclovir for iridocyclitis caused by herpes simplex virus. The Herpetic Eye Disease Study Group. *Arch Ophthalmol*. 1996 Sep;114(9):1065–72.
- Wilhelmus KR, Beck RW, Moke PS, Dawson CR, Barron BA, Jones DB, et al. Acyclovir for the prevention of recurrent herpes simplex virus eye disease. Herpetic Eye Disease Study Group. *N Engl J Med*. 1998 Jul 30;339(5):300–6.
- Kim SR, Khan F, Ramirez-Fort MK, Downing C, Tyring SK. Varicella zoster: an update on current treatment options and future perspectives. *Expert Opin Pharmacother*. 2014 Jan;15(1):61–71.
- Cobo LM, Foulks GN, Liesegang T, Lass J, Sutphin JE, Wilhelmus K, et al. Oral acyclovir in the treatment of acute herpes zoster ophthalmicus. *Ophthalmology*. 1986 Jun;93(6):763–70.
- Neoh C, Harding SP, Saunders D, Wallis S, Tullo AB, Nylander A, et al. Comparison of topical and oral acyclovir in early herpes zoster ophthalmicus. *Eye*. 1994;8 ( Pt 6):688–91.
- Beutner KR, Friedman DJ, Forszpaniak C, Andersen PL, Wood MJ. Valaciclovir compared with acyclovir for improved therapy for herpes zoster in immunocompetent adults. *Antimicrob Agents Chemother*. 1995 Jul;39(7):1546–53.
- Tyring S, Barbarash RA, Nahlik JE, Cunningham A, Marley J, Heng M, et al. Famciclovir for the treatment of acute herpes zoster: effects on acute disease and postherpetic neuralgia. A randomized, double-blind, placebo-controlled trial. Collaborative Famciclovir Herpes Zoster Study Group. *Ann Intern Med*. 1995 Jul 15;123(2):89–96.
- Pepose JS, Ahuja A, Liu W, Narvekar A, Haque R. Randomized, Controlled, Phase 2 Trial of Povidone-Iodine/Dexamethasone Ophthalmic Suspension for Treatment of Adenoviral Conjunctivitis. *Am J Ophthalmol*. 2019 Sep;205:197.
- Ramakrishnan S, Vempati J, Baskaran P. Randomized, Controlled, Phase 2 Trial of Povidone-Iodine/Dexamethasone Ophthalmic Suspension for the Treatment of Adenoviral Conjunctivitis. *Am J Ophthalmol*. 2019 Aug;204:140.
- Martin DF, Sierra-Madero J, Walmsley S, Wolitz RA, Macey K, Georgiou P, et al. A controlled trial of valganciclovir as induction therapy for cytomegalovirus retinitis. *N Engl J Med*. 2002 Apr 11;346(15):1119–26.
- Studies of Ocular Complications of AIDS Research Group, AIDS Clinical Trials Group. Mortality in patients with the acquired immunodeficiency syndrome treated with either foscarnet or ganciclovir for cytomegalovirus retinitis. *N Engl J Med*. 1992 Jan 23;326(4):213–20.
- Spector SA, Weingeist T, Pollard RB, Dieterich DT, Samo T, Benson CA, et al. A randomized, controlled study of intravenous ganciclovir therapy for cytomegalovirus peripheral retinitis in patients with AIDS. AIDS Clinical Trials Group and Cytomegalovirus Cooperative Study Group. *J Infect Dis*. 1993 Sep;168(3):557–63.
- Miao H, Tao Y, Jiang Y-R, Li X-X. Multiple intravitreal injections of ganciclovir for cytomegalovirus retinitis after stem-cell transplantation. *Graefes Arch Clin Exp Ophthalmol*. 2013 Jul;251(7):1829–33.
- Schoenberger SD, Kim SJ, Thorne JE, Mruthyunjaya PM, Yeh S, MD SJB, et al. Diagnosis and Treatment of Acute Retinal Necrosis A Report by the American Academy of Ophthalmology. *Ophthalmology*. 2017 Mar 1;124(3):382–92.





**KH Martin Kollmann**  
Senior Advisor for Neglected Tropical Diseases: CBM, Nairobi, Kenya.



**Sofia Abrahamsson**  
Policy Advisor – Health: Sightsavers, Haywards Health, UK.



**Tim Jesudason**  
Special Projects and Campaign Partnerships: International Coalition for Trachoma Control, London, UK.

# Why disability inclusion is essential for trachoma elimination

People who have experienced discrimination associated with disease and disability have a unique voice that takes programmes closer to the communities they are designed to benefit.

Trachoma, the world's leading infectious cause of blindness, is a cause and consequence of poverty and marginalisation. Communities affected by trachoma often have limited access to good, comprehensive health services and therefore experience high levels of avoidable or correctable complications that result in visual impairment and blindness.

In 2019, the World Health Organization (WHO) released the **World Report on Vision**.<sup>1</sup> The report states that vast inequities exist in the access to eye health services and that many people with disabilities, including people with vision impairment, are underserved.<sup>1</sup> To overcome the significant challenges and address access to eye care, the report promotes a people-centred approach, calling for affected people and communities to be central in the design, planning, delivery and evaluation of services.

People with disabilities face a variety of physical and psychosocial barriers to accessing adequate services. In many trachoma-endemic areas, people with disabilities have insufficient access to clean water, toilets and hygiene education,<sup>2</sup> all of which are needed to reduce the risk of infection with, and transmission of, trachoma. People with disabilities may experience challenges to take part in mass drug administration (MDA) or surgical outreach campaigns without effective support.

The systematic inclusion of people with disabilities and other marginalised groups into trachoma and general eye health programmes is critical to overcome these barriers; however, it will require new thinking and approaches. Programmes must collect data that can be disaggregated by disability during baseline and impact surveys in order to identify the magnitude and pattern of disabilities, inform approaches and identify appropriate partnerships. All of these are needed in order to plan, implement and monitor tailored interventions.

Working in partnership with community-based organisations such as disabled people's organisations (DPOs) will be an important component of this process. By working with DPOs, programmes can develop effective strategies, such as sensitising case-finders ahead of door-to-door screening to identify and treat everyone that needs surgery. For people who are irreversibly blind or visually impaired, programmes must develop effective and comprehensive referral pathways to medical and psychosocial rehabilitation services – including those that support people with livelihood, mental wellbeing and the management of stigma.

The ongoing development of universal health coverage packages at national level provides an opportunity to advocate for the inclusion of people with disabilities in



A woman who is blind from trachoma received eyelid surgery to relieve pain from trichiasis. ETHIOPIA

the planning, implementation and monitoring of eye health services. A systematic approach, with specific indicators disaggregated by disability on MDA and surgical services coverage, as well as the accessibility of water, sanitation and hygiene infrastructure, will enhance awareness and assist in ensuring that programmes become fully inclusive. Together, the trachoma, eye health and neglected tropical disease (NTD) communities can support inclusive approaches in health services by collaborating and engaging at national, regional and global levels.

To achieve the 2030 Sustainable Development Goals (SDGs), including Goal 3 on “healthy lives and well-being for all”, we should focus on target 3.3 on communicable diseases including NTDs and 3.8 on universal health coverage. It is essential to fiercely advocate for the participation and inclusion of people with disabilities in addition to other marginalised groups, including women, older people, refugees and indigenous and nomadic communities. There is an increasing body of evidence that participation of communities that are themselves affected makes NTD programmes more effective and increases community ownership and programme sustainability. This can help to secure the great progress already made so far and support the crucial last mile towards achieving elimination of trachoma as a public health problem. Working together with one voice, trachoma, NTD and eye health communities have an opportunity to support and accelerate government efforts to achieve vision for all and truly leave no one behind.

## Recommendations

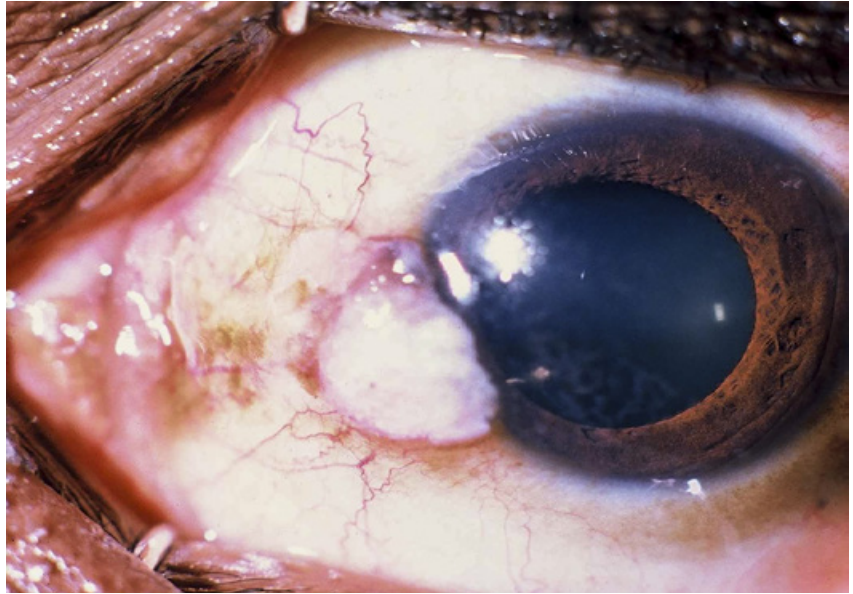
- Investigate the impact of disability on the accessibility and acceptability of all trachoma interventions and adapt programmes accordingly
- Address the impact of trachoma on disability-related stigma and mental wellbeing
- Collect, analyse and use disability-disaggregated data and conduct implementation research on inclusive preferred practices
- Promote intersectoral working that promotes the formation and inclusion of disabled people's organisations (DPOs)
- Promote human rights-based participatory and people-centred approaches.

## References

- 1 WHO, 2019. World Report on Vision. <http://bit.ly/world-report-on-vision>
- 2 Water Aid, 2011. What the Global Disability Report means for the WASH sector. <http://bit.ly/wash-gdr>

# Test your knowledge and understanding

This page is designed to help you to test your own understanding of the concepts covered in this issue, and to reflect on what you have learnt.



ALLEN FOSTER

Human immunodeficiency virus (HIV) is a risk factor for squamous cell carcinoma of the conjunctiva.

We hope that you will also discuss the questions with your colleagues and other members of the eye care team, perhaps in a journal club. To complete the activities online – and get instant feedback – please visit [www.cehjournal.org](http://www.cehjournal.org)

**Tick ALL that are TRUE**

## Question 1

Which of the following ocular viral diseases can be effectively treated using antiviral medications?

- a. Zika virus infection
- b. Cytomegalovirus retinitis
- c. Herpes simplex epithelial keratitis
- d. Adenoviral follicular conjunctivitis
- e. Ebola uveitis

## Question 2

Which of the following viral conditions can be prevented by immunisation?:

- a. Adenovirus
- b. Measles
- c. Rubella
- d. Cytomegalovirus
- e. HIV

## Question 3

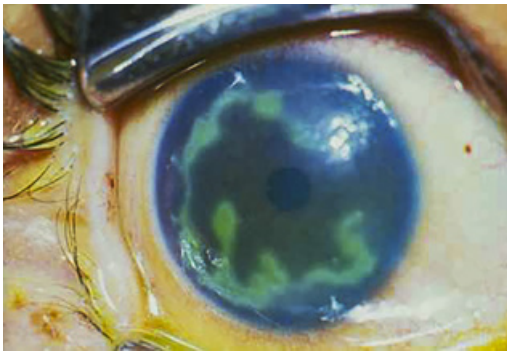
Which of the following virus infections can cause retinitis?

- a. Herpes simplex
- b. Herpes zoster
- c. Cytomegalovirus
- d. HIV
- e. Adenovirus

## ANSWERS

1. b and c. Currently there are no proven effective antiviral medications for Zika, adenovirus or Ebola uveitis.
2. b and c. Measles and rubella both have effective immunisation programmes.
3. a, b, c and d may all cause retinitis.

## Picture quiz



ICEH

A young person presented with a history of a sore left eye for 1 week following a febrile illness. The visual acuity was 6/18 in the left eye. The right eye was normal.

### Question 1

What is the diagnosis?

- Suppurative fungal keratitis
- Neurotrophic keratitis due to herpes zoster
- Episcleritis
- Herpes simplex epithelial keratitis
- Adenoviral punctate keratitis

### Question 2

Which of the following are known risk factors for this condition?

- Fever
- Stress
- Malaria
- Iritis
- Immune deficiency

### Question 3

Which of the following can be used to treat this condition?

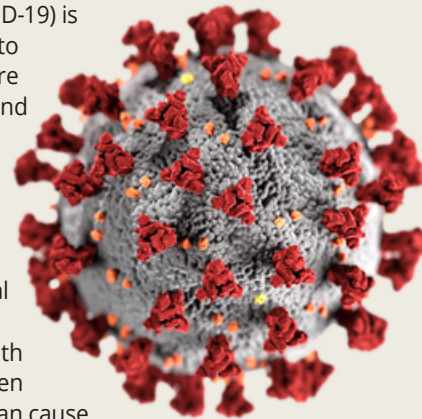
- Aciclovir 3% eye ointment
- Prednisolone 0.5% eye drops
- Trifluorothymidine 1% drops
- Timolol 0.5% eye drops
- Ganciclovir 0.15% eye gel

## ANSWERS

- d. This is a large dendritic ulcer probably due to herpes simplex virus.
- a, b, c and e may all act as triggers for recurrence of herpes simplex infection.
- a, c, and e are anti-viral medications which are effective against herpes simplex virus. Prednisolone should not be used. Timolol is used in glaucoma to lower intraocular pressure.

## Novel coronavirus (COVID-19)

The novel coronavirus (COVID-19) is emerging as a global threat to public health. It causes severe acute respiratory infection and is highly contagious. The **American Academy of Ophthalmology (AAO)** has published specific guidance for ophthalmologists, as they may be the first medical professionals to evaluate patients possibly infected with COVID-19. It has recently been established that COVID-19 can cause conjunctivitis in a minority of patients.



CENTRES FOR DISEASE CONTROL

Be aware that patients with both conjunctivitis and respiratory symptoms may be infected with COVID-19, particularly if they have recently returned from an area of the world where COVID 19 is known to occur or been in contact with people who have done so.

Please follow recommended infection control guidelines.

For more comprehensive and detailed information, including links to other useful websites, visit [www.aao.org/headline/alert-important-coronavirus-context](http://www.aao.org/headline/alert-important-coronavirus-context)

## Courses

### MSc Public Health for Eye Care, London School of Hygiene & Tropical Medicine, London, UK

Fully funded scholarships are available for Commonwealth country nationals. For more information visit [www.lshtm.ac.uk/study/masters/mscphec.html](http://www.lshtm.ac.uk/study/masters/mscphec.html) or email [romulo.fabunan@lshtm.ac.uk](mailto:romulo.fabunan@lshtm.ac.uk)

### Small Incision Cataract Surgery Training at Lions Medical Training Centre in Nairobi, Kenya

Courses begin every six weeks and cost US \$1,000 for training and approximately US \$1,000 for accommodation. Email [training@lionsloresho.org](mailto:training@lionsloresho.org) or call/message +254 728 970 601 or +254 733 619 191.

### Free online courses

The **ICEH Open Education for eye care programme** offers a series of online courses in key topics in public health eye care. All the courses are free to access. More free courses coming! Certification also available. For more information visit <http://iceh.lshtm.ac.uk/oer/>

## Subscriptions

Contact Anita Shah [admin@cehjournal.org](mailto:admin@cehjournal.org)

Subscribe to our mailing list

[web@cehjournal.org](mailto:web@cehjournal.org)

or visit [www.cehjournal.org/subscribe](http://www.cehjournal.org/subscribe)

Visit us online

[www.cehjournal.org](http://www.cehjournal.org)

[www.facebook.com/CEHJournal](https://www.facebook.com/CEHJournal)

<https://twitter.com/CEHJournal>

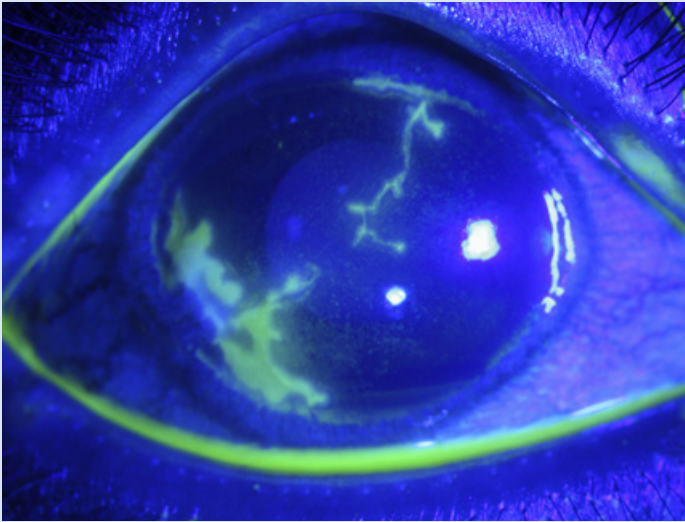
## Next issue



FRANCO LOOTIS

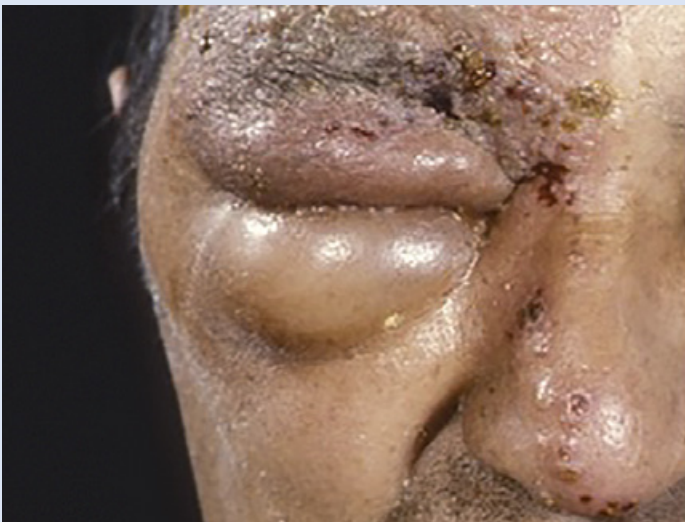The next issue is on the theme  
**Ophthalmic Nursing**

# Key community eye health messages: Viral infections of the eye



LYPEI

Herpes simplex keratitis is common. It can present in different forms. Antiviral treatment is recommended. Do **not** use steroids in dendritic or geographic ulcers.



STEPHEN TUFT

Herpes zoster ophthalmicus can cause corneal damage and iritis, especially when the nasociliary nerve is affected as shown by a rash on the tip of the nose.




LYPEI

Zika infection in pregnancy can cause congenital Zika syndrome in a newborn baby. All babies suspected of having been exposed to Zika virus in utero should have a full eye examination.



**Victor H Hu**  
Clinical Assistant Professor,  
International Centre for  
Eye Health, LSHTM<sup>i</sup> &  
Consultant Ophthalmologist:  
Mid Cheshire Hospitals



**Elanor Watts**  
Junior doctor & MSc Public  
Health for Eye Care student,  
LSHTM<sup>i</sup>



**Matthew Burton**  
Professor of International  
Eye Health and Director,  
International Centre for  
Eye Health, LSHTM<sup>i</sup>



**Fatima Kyari**  
Associate Professor:  
International Centre for  
Eye Health, LSHTM<sup>i</sup>  
& Consultant Ophthalmologist:  
University of Abuja<sup>ii</sup>



**Ciku Mathenge**  
Consultant Ophthalmologist  
& Director of Training and  
Research, Rwanda International  
Institute of Ophthalmology<sup>iii</sup>



**Fatemeh Heidary**  
Head of Ophthalmology  
Division, Ahvaz Jundishapur  
University of Medical Sciences<sup>iv</sup>



**Jeremy Hoffman**  
Clinical Research Fellow:  
International Centre for  
Eye Health, LSHTM<sup>i</sup>



**Elmien Wolvaardt**  
Editor: *Community Eye Health  
Journal*, International Institute  
for Eye Health, LSHTM<sup>i</sup>

<sup>i</sup>International Centre for Eye Health, London School of Hygiene & Tropical Medicine, London, UK.

<sup>ii</sup>College of Health Sciences, University of Abuja, Abuja, Nigeria.

<sup>iii</sup>Rwanda International Institute of Ophthalmology, Kigali, Rwanda.

<sup>iv</sup>Taleghani Hospital, Padad Shahr, Ahvaz Jundishapur University of Medical Sciences, Ahvaz, Iran.

# Protecting yourself and your patients from COVID-19 in eye care

The COVID-19 pandemic is having profound repercussions around the world.<sup>1,2</sup> Eye health care providers, along with other health services, are having to work out how care should now be delivered.

An ophthalmologist working in Wuhan, China, was among the first to recognise the possible emergence of a new respiratory disease outbreak.<sup>3</sup> Sadly, he and a number of his colleagues subsequently died from the infection. It is now understood that severe acute respiratory syndrome coronavirus 2 (SARS-CoV-2), the virus that causes Coronavirus Disease 2019 (COVID-19), is transmitted by droplets, aerosol particles, human-to-human contact or via fomites (particles of skin cells, hair, clothing and bedding). Infection can occur when viral particles enter the mouth, nose or eyes.<sup>4</sup>

To help stop the spread of infection, some measures have been implemented in many countries. These include:

- Self-isolating measures, i.e., staying at home.<sup>5</sup> This is particularly important for people considered to be vulnerable, i.e. more at risk of severe COVID-19 complications. They include older people, those with underlying medical problems (e.g., diabetes and chronic respiratory, heart, kidney, neurological and liver diseases), people who are immunosuppressed, and people with marked obesity (body mass index [BMI] > 40).<sup>6</sup> Many countries are currently asking their whole population to stay at home, with the exception of key workers and essential activities, to limit the spread of the virus and the number of people likely to need intensive care.
- Social distancing. If people do have to go outside of the home, they are advised to keep a distance of at least 2 metres from others.<sup>7</sup>
- People who might have had a travel history or possible contact with an infected person are asked to self-isolate or are quarantined.<sup>8</sup>

Health care workers, especially in a hospital setting, are on the front line in the efforts against this pandemic.<sup>9-11</sup> There is considerable concern in the ophthalmic community about the risk of infection as there is increasing information that the initial infectious dose (amount of virus transmitted) and resulting high viral load may increase the risk of severe COVID-19 disease.<sup>12,13</sup>

**Coronavirus - Covid-19 - Simple Guide**  
**SAVE LIVES - How to try and stay well and avoid spreading the virus**

**1) Wash hands**  
frequently with soap and water for 20 seconds

**2) Cover mouth**  
with elbow when coughing or sneezing

**3) Avoid touching**  
your eyes, nose and mouth with unwashed hands

**4) 2 metres apart**  
keep two metres distance from each other

**5) Stay Home**  
Where possible stay home

**6) Avoid meetings**  
and being together with other people

**Symptoms:**  
Fever - Headache - Dry cough and shortness of breath - Muscle pain  
If you think you have the Virus keep away from other people for two weeks  
Most people will only have mild symptoms  
Older people, and people with pre-existing medical conditions (such as asthma, diabetes, heart disease) are more likely to become severely ill

www.rippleafrica.org

**Educating the public about COVID-19 is an essential component of interventions to stop the spread of the novel coronavirus. MALAWI**

There are a number of guidelines on how to adapt services and adjust practice to limit the spread of infection in a clinical setting; however, the evidence is still limited. This uncertainty, the many differences between countries and individual clinical settings, and ongoing practical challenges such as shortages in personal protective equipment (PPE) means that things will be changing all the time and eye health workers will have to adapt and make the best of what is available to them at the time.

Guidelines are also changing constantly to reflect new research as it comes in. We encourage you to visit the websites given in the panel to receive further updates. The Centers for Disease Control (CDC) provides guidance for dealing with PPE shortages at <https://bit.ly/PPEguide>.

## Guidelines and useful websites

- World Health Organization (WHO). **Country & Technical Guidance – Coronavirus disease (COVID-19)**<sup>14</sup>
- World Health Organization (WHO). **Rational use of personal protective equipment for coronavirus disease (COVID-19)**<sup>15</sup>
- International Agency for the Prevention of Blindness. **COVID-19 Resources: Here is what we know**<sup>16</sup>
- International Council for Ophthalmology. **Coronavirus Information for Ophthalmologists**<sup>17</sup>
- Royal College of Ophthalmologists **COVID-19 Clinical Guidelines**<sup>18</sup>
- American Academy of Ophthalmologists. **Coronavirus and Eye Care**<sup>19</sup>
- World Council of Optometry. **Statement concerning COVID-19**<sup>20</sup>
- Centers for Disease Control (US) **Strategies to Optimise the Supply of PPE**<sup>21</sup>

The particular context of an eye health service will influence how the guidelines can be put into practice, such as the availability of personal protective equipment (PPE), access to emergency care for known COVID-19 patients, and the available means of communication.

The current guidelines can be summarised as follows:

- 1 Cease providing any routine eye services other than urgent or emergency care
- 2 Protect health care workers
- 3 Reduce transmission to other patients, and between patients and health care workers

### 1. Cease providing any routine eye services other than urgent or emergency care

Postpone or defer any non-urgent eye appointments. Patients coming to an eye clinic or eye unit are at risk of exposure to COVID-19 infection, and many patients attending for eye care are elderly or suffer from underlying chronic medical conditions such as diabetes; they are at increased risk of severe COVID-19 and social distancing is therefore particularly important for them.

Also, reducing eye care services can release health workers to be deployed to other areas of health care where they may be able to play an important role during the pandemic.

Where there is an appointment system in place, defer pre-existing appointments by text message/phone message, letter or other means, as available. Conducting a telephone consultation may be helpful to give advice or, if necessary, decide whether a face-to-face review is essential. When issuing a prescription, follow local guidelines. Ideally, send patients written information

about any appointment deferrals, the advice given and how new appointments will be made once the situation allows. If possible, set up pathways for urgent/emergency care together with measures to reduce transmission, as discussed in this article. Tell patients how they can gain access to such care.

### Patients needing urgent or emergency care

There will be patients who need to be seen and treated urgently. Services should continue to be provided, where possible, to patients at high risk of visual loss without treatment. This may include people with the conditions such as these<sup>18,22</sup>:

- Exudative age-related macular degeneration
- Severe diabetic retinopathy
- Acute retinal detachment
- Advanced or rapidly progressive glaucoma
- Severe, active uveitis
- Serious ocular oncology conditions
- Retinopathy of prematurity (screening and treatment)
- Globe rupture or other significant trauma
- Serious ocular infections (microbial keratitis, endophthalmitis)

Whether it is appropriate for patients to be seen for urgent/emergency eye care will depend on the individual patient, the risk of significant harm if treatment is delayed and the situation of the eye care provider. Having only one seeing eye would be a strong factor in favour of a patient being seen, for example. If possible, patients should stay away from eye health care settings if they are older than 70 years, have serious pre-existing health problems, or are immunosuppressed.

Table 1 gives some guidance on triaging patients and the appropriate precautions to take.

**Table 1** AAO interim guidance on ophthalmology patient triage and precautions<sup>19</sup>

Clinical situation	Patient management / precautions
1. Routine ophthalmic issues and previously scheduled appointments	<ul style="list-style-type: none"> <li>• Routine problems should be deferred, and previously scheduled appointments should be cancelled</li> <li>• Appointments should be rescheduled only upon clearance from public health authorities</li> <li>• Refill all necessary medications</li> </ul>
2. Urgent ophthalmology appointment for a patient with no respiratory illness symptoms, no fever, and no COVID-19 risk factors	<ul style="list-style-type: none"> <li>• Standard precautions*</li> <li>• Added precaution of not speaking during slit-lamp biomicroscopic examinations is appropriate</li> <li>• In the setting of adequate PPE supplies, use of surgical mask and eye protection** for the clinician as well as surgical mask for the patient may reduce asymptomatic and pre-symptomatic transmission</li> </ul>
3. Urgent ophthalmic problem in a patient with respiratory illness symptoms, but no fever or other COVID-19 risk factor	<ul style="list-style-type: none"> <li>• The patient can be seen in the eye clinic</li> <li>• The patient should be placed in an examination lane immediately with the door closed and placed in a surgical mask. The treating ophthalmologist and health care personnel require surgical masks at minimum</li> <li>• Gown, gloves, surgical mask and eye protection are recommended for the clinician.† An N-95 mask should be worn if a procedure is planned that will result in aerosolized virus</li> <li>• The examining room must be disinfected after examination</li> </ul>
4. Urgent ophthalmic problem in a patient who is at high risk for COVID-19	<ul style="list-style-type: none"> <li>• The patient is best sent to the ER (emergency room) or other hospital-based facility equipped to evaluate for, and manage, COVID-19</li> <li>• If the patient has an urgent eye problem based on screening questions, the facility should be one that is equipped to provide eye care in the hospital setting</li> <li>• If SARS-CoV-2 infection is confirmed, CDC (or hospital) guidelines for care of suspected COVID-19 patients should be followed for <b>health care facility preparation</b> and <b>infection control</b></li> <li>• Eye care is best provided in the hospital setting. Transmission precautions‡ for treating ophthalmologists include wearing a surgical mask, gown, gloves and eye protection (face shield or goggles, if available)</li> </ul>
5. Urgent ophthalmic problem in a patient with documented COVID-19 (or person under investigation [PUI])	<ul style="list-style-type: none"> <li>• The patient should remain in the hospital setting if possible</li> <li>• Determine whether the eye problem is urgent based on screening questions, and if so, evaluation and management should be in the hospital setting</li> <li>• If the patient is not hospitalized at the time of referral, the patient is best referred to the ER or other hospital-based facility equipped to manage both COVID-19 and eye care.</li> <li>• CDC or hospital guidelines should be followed for care of COVID-19 patients.</li> <li>• Transmission precautions‡ for treating ophthalmologists include wearing an N-95 mask, gown, gloves and eye protection (face shield or goggles, as above).</li> <li>• [Read the American College of Surgeon's guidelines for operating on COVID-19 patients]</li> </ul>

[Read the **American College of Surgeons' guidelines** for operating on COVID-19 patients]

\* **Standard (Universal) Precautions:** Minimum infection prevention precautions that apply to all patient care, regardless of suspected or confirmed infection status of patient, in any health care setting (e.g., hand hygiene, cough etiquette, use of PPE, cleaning and disinfecting environmental surfaces). See CDC: **Standard Precautions**.

\*\* Supply permitting, tight-fitting goggles may be preferable to face shields for eye protection.

† Currently, there are national and international shortages of PPE, which also warrant consideration. Excessive use of PPE may deplete the supply of critical equipment required in the future for patients with COVID-19 as the epidemic expands. Use of PPE should be considered on an institutional and case-by-case basis; universal usage for all patient encounters is not appropriate.

‡ **Transmission Precautions:** Second tier of basic infection control, used in addition to Standard Precautions when patients have diseases that can spread through contact, droplet or airborne routes, requiring specific precautions based on the circumstances of a case. Transmission precautions are required for cases of suspected COVID-19. See CDC: **Transmission-Based Precautions**.

## 2. Protect health care workers

### Symptoms & when to self-isolate

Symptoms of cough, fever, shortness of breath or flu-like symptoms are typical in COVID-19, but others are also common, including loss of taste and smell.<sup>23</sup> It is vital to inform patients and health care workers with symptoms of COVID-19 that they should not come to the hospital or clinic, but should self-isolate (i.e., stay at home and avoid contact with other members of the household) for seven days. The United Kingdom's National Health Service (NHS) guidelines state that people who still have a high temperature after 7 days of self-isolation must remain at home until their temperature returns to normal.<sup>24</sup>

The incubation period for COVID-19 is thought to range from 1 to 14 days, with symptom onset typically around 5 days; these estimates will be updated as more data becomes available.<sup>4</sup> **Patients may be infectious before showing any symptoms, and some may show no symptoms at all.** A person who has been in contact with someone known to have COVID-19 should self-isolate for 14 days, until such time as WHO guidance is updated.<sup>4</sup> It is important to follow national guidelines. Communicate this information to patients as early as possible, so that patients who need to self-isolate do not travel to the unit in the first place.



**Figure 1** Hospitals and clinics should have clear information for patients to return home and self-isolate if they have symptoms. UK

If they do arrive at the unit, there should be very clear information to prevent infection spread; e.g., telling patients to return home and self-isolate (Figure 1).

Table 2 provides more detailed guidance on the type of PPE to be worn. It is important to take note of national guidelines. PPE is likely to include disposable gloves, disposable gown, face respirator mask (when appropriate, e.g., FFP3 or N95) and eye protection. Follow strict PPE wearing and removing procedures (see panel). Dispose of PPE appropriately and carry out thorough room cleaning and air exchange after each patient.

**Table 2** Royal College of Ophthalmologists guidelines on protective equipment<sup>18</sup>

	Disposable gloves	Disposable plastic apron	Disposable fluid resistant gown	Fluid resistant surgical mask	Filtering face piece respirator	Eye/face protection	Slit lamp breath guard
Performing an aerosol-generating procedures (AGPs)	✓ Single use	✗	✓ Single use	✗	✓ Single use	✓ Single use	✗
High risk acute areas, e.g. theatres where AGPs performed, intensive care unit (ITU), high dependency unit (e.g. ophthalmology review of patient in ITU)	✓ Single use	✓ Single use	✓ Sessional use	✗	✓ Sessional use	✓ Sessional use	✗
Theatres where AGPs not done	✓ Single use	✓ Single use	✓ Risk-assess single use, i.e. use instead of apron if splashes are likely	✓ Single or sessional use	✗	✓ Single or sessional use	✗
Working in inpatient area within two metres eg ophthalmology review of ward patients	✓ Single use	✓ Single use	✗	✓ Sessional use	✗	✓ Sessional use	✓ If using fixed slit lamp
Emergency and acute hospital eye clinics	✓ Single use	✓ Single use	✗	✓ Sessional use	✗	✓ Sessional use	✓
Non-emergency /acute eye outpatients	✓ Single use	✓ Single use	✗	✓ Sessional use	✗	✓ Sessional use	✓

**Single use** = disposal or decontamination of device between each patient/procedure, dispose at end of session

**Sessional use** = dispose at end of session, e.g. at the end of morning clinic or when leaving the care setting

Aerosol-generating procedures (AGPs). Aspects relevant to ophthalmology are in **bold**:

- **Intubation, extubation** and related procedures, such as manual ventilation and open suctioning of the respiratory tract
- Tracheotomy/tracheostomy procedures (insertion/open suctioning/removal)
- Bronchoscopy and **upper ENT airway procedures** that involve suctioning  
Upper gastro-intestinal endoscopy where there is open suctioning of the upper respiratory tract
- **Surgery procedures involving high-speed devices**  
Some dental procedures (e.g. high-speed drilling)  
**Non-invasive ventilation** (e.g., CPAP and laryngeal masks)
- High-frequency oscillatory ventilation (HFOV)
- Induction of sputum
- High-flow nasal oxygen

Defer surgical procedures where possible. If surgery cannot be avoided, this should be done under local anaesthesia if possible, taking full precautions. General anaesthesia is an 'aerosol-generating procedure' (AGP) which creates a high-risk environment for virus transmission. However, even surgery under local anaesthesia will involve significant exposure between medical personnel and patient and should be considered high risk. If surgery must be undertaken, then full PPE should be used for all patients.

### Self-care and personal protection

- **Wash hands regularly and thoroughly; normal soap is adequate.** Use alcohol-based (>60% ethanol or >70% isopropyl alcohol) hand sanitiser or hand gel if hands are visibly clean and water is not available.
- Staff members and patients/visitors must wash their hands using soap and water or alcohol-based hand sanitiser or hand gel on entering the unit.
- Avoid touching your eyes, nose and mouth.
- If available, use appropriate PPE. Guidelines are constantly being updated; however, there is an increasing recognition of the role of eye protection (Table 2). This is something that may be dictated by health management at a higher (regional/national) level.
- Clinical staff not in uniform who are in close contact with patients should wear surgical scrubs. These should be laundered daily in accordance with the unit's policy on the safe laundering of clinical garments.
- The same surgical mask may be worn for multiple patients to be seen at the slit lamp. However, scrupulous care must be taken not to transmit the virus on the front of the mask via hands or clothes. If using the same mask, do not take on and off between patients and do not allow it to dangle on the chest. Never touch the front of the mask.
- Put on and remove PPE in an order that minimises the potential for self-contamination (see panel).
- The use of a cloth face covering does not replace a surgical mask or respirator, however, they may be better than no covering at all.<sup>29, 30</sup>

### How to put on and remove personal protective equipment (PPE)

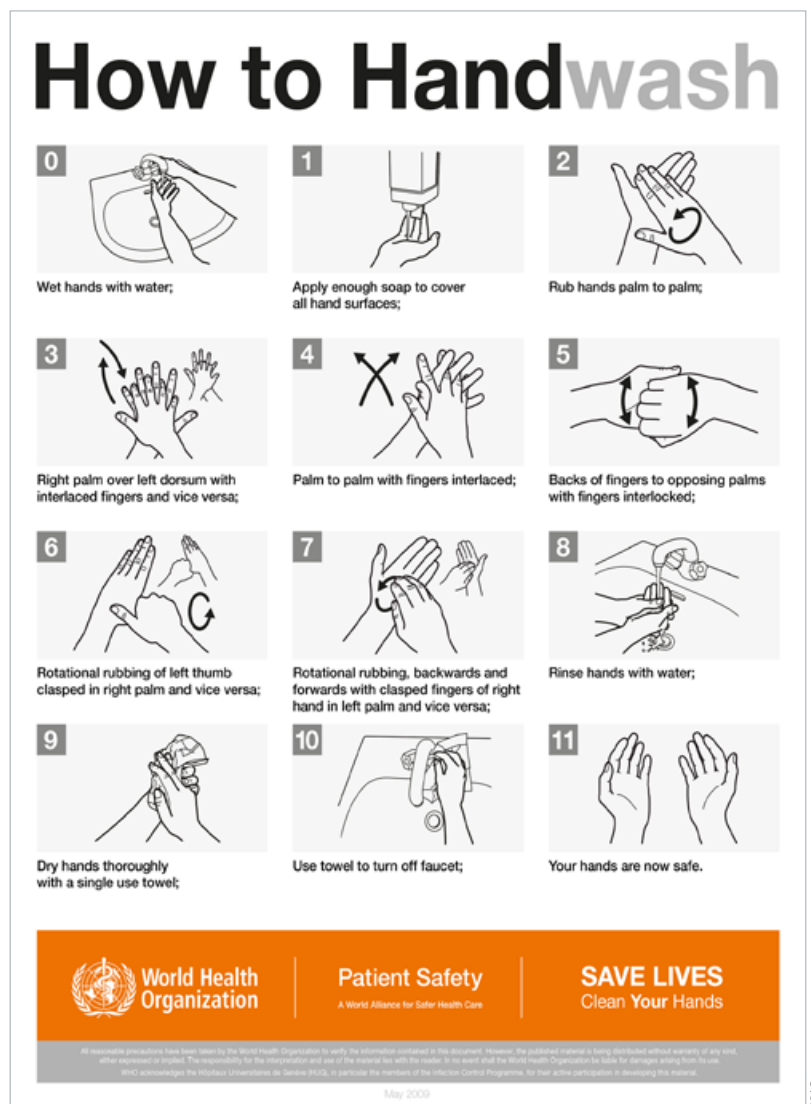#### Correct order for putting on PPE

- 1 Gown/apron
- 2 Mask/respirator
- 3 Goggles/face shield
- 4 Gloves

#### Correct order for removing PPE

- 1 Gloves
- 2 Goggles/face shield
- 3 Gown/apron
- 4 Mask/respirator
- 5 Wash hands<sup>25</sup>

Figure 2 World Health Organization hand washing poster



### 3. Reduce transmission to other patients, and between patients and health care workers

#### A. Patient triage

- Patients should already have been notified not to travel to the health care unit if they have symptoms of COVID-19.
- Prominent information posters at the entrance to the unit should alert anyone who arrives to return directly home if they have symptoms and to stay at least 2 metres away from others. If urgent/emergency care is required, they should be directed to an isolation area where they can be examined by health care personnel wearing protective equipment.
- A health care worker should ask patients about possible symptoms on arrival at the booking-in or reception area and direct them appropriately.

#### B. Instructions for patients

- Patients and visitors must wash their hands using soap and water alcohol-based (>60% ethanol or >70% isopropyl alcohol) hand sanitiser or hand gel on entering the unit.
- Some countries advise that patients wear masks to limit transmission to medical personnel or other patients.<sup>25-28</sup>
- The use of a cloth face covering does not replace a surgical mask or respirator, however, they may be better than no covering at all.<sup>29, 30</sup>



**C. While examining the patient**

- Minimise patient contact time by reviewing the notes beforehand. One suggestion is for the patient to be placed in one room and the clinician in another and for them to talk via a phone or a tablet computer. The clinician then enters the patient room, conducts the examination as swiftly as possible (without talking) and exits the room.
- Avoid shaking hands, or any other patient contact, as much as possible.
- Use slit lamp barriers (breath guards or breath shields), Figure 3. These may be available commercially or they can be made from materials such as acetate sheets (used for overhead projectors), clear plastic or Perspex. Cut holes for the slit lamp eyepieces; it may help to use a cardboard template.
- Minimise investigations. For example, perform visual fields and OCT scans only if absolutely necessary. Avoid tonometry if possible.
- Clean surfaces and instruments between patients. Use disposable gloves and a solution of household bleach (1.5 tablespoons per litre of water) or alcohol solutions with at least 70% alcohol.
- Remember to clean patient seats, clinic door handles and phones, if used.
- Remember to clean the breath guard, on/off switch and any controls or buttons when cleaning the slit lamp.

**D. The work environment**

- Keep waiting rooms as empty as possible, with preferably at least 2 metres between individuals.
- Prevent overcrowding in the examination room by restricting entry by accompanying persons where possible.
- Routine daily cleaning of the clinic environment with appropriate disinfectants is vital.

**Figure 3** Slit lamp breath guards



COPHTH<sup>18</sup>

**Conjunctivitis**

COVID-19 can cause conjunctivitis and virus particles may be found in ocular secretions.<sup>31</sup>

There is debate as to whether conjunctivitis is a high-risk feature for COVID-19. Although a follicular conjunctivitis can be caused by the virus, this seems to be a relatively uncommon and a non-specific sign that presents later in the clinical course. However, a health care worker who was part of an expert task force to visit Wuhan developed conjunctivitis as the first symptom of COVID-19 despite being fully gowned with protective suit and N95 respirator.<sup>32</sup> Health care workers have subsequently been urged to wear eye protection when in close contact with patients; this is also reflected in recently updated guidance.<sup>15,33</sup> Many cases of conjunctivitis do not actually require review and it is important that patients with possible symptoms of COVID-19 are instructed to self-isolate unless they require hospital in-patient care. If a patient does present with any conjunctivitis, it would seem sensible to wear full PPE until more is known.

**Reusing eye protection**

The CDC acknowledges that eye protection is often reusable, not disposable, and provides the following guidelines on re-use.<sup>34</sup>

When manufacturer instructions for cleaning and disinfection are unavailable, consider these steps:

- 1 While wearing gloves, carefully wipe the *inside*, followed by the *outside* of the face shield or goggles using a cleaning wipe or a clean cloth saturated with pH-neutral detergent solution.
- 2 Use a wipe or clean cloth saturated with a registered hospital disinfectant solution to wipe the outside of the face shield or goggles carefully.
- 3 Wipe the outside of face shield or goggles with clean water or 70% alcohol to remove residue.
- 4 Fully dry (air dry or use clean absorbent towels).
- 5 Remove gloves and perform hand hygiene.

## References

- 1 Li LQ, Huang T, Wang YQ, et al. COVID-19 patients' clinical characteristics, discharge rate, and fatality rate of meta-analysis. *J Med Virol* 2020.
- 2 Lake MA. What we know so far: COVID-19 current clinical knowledge and research. *Clin Med (Lond)* 2020;20:124-127.
- 3 Green A, Li Wenliang. Obituary. *Lancet* 2020;395:682.
- 4 WHO. Newsroom Q&A Coronaviruses. [www.who.int/news-room/q-a-detail/q-a-coronaviruses](http://www.who.int/news-room/q-a-detail/q-a-coronaviruses)
- 5 COVID-19 advice in the UK, April 2020. [www.nhs.uk/conditions/coronavirus-covid-19/](http://www.nhs.uk/conditions/coronavirus-covid-19/)
- 6 Zhou F, Yu T, Du R, et al. Clinical course and risk factors for mortality of adult inpatients with COVID-19 in Wuhan, China: a retrospective cohort study. *Lancet* 2020;395:1054-1062.
- 7 Wilder-Smith A, Freedman DO. Isolation, quarantine, social distancing and community containment: pivotal role for old-style public health measures in the novel coronavirus (2019-nCoV) outbreak. *J Travel Med.* 2020;27(2). pii: taaa020.
- 8 Wilson ME, Chen LH. Travellers give wings to novel coronavirus (2019-nCoV). *J Travel Med.* 2020;27(2). pii: taaa015.
- 9 Wang J, Zhou M, Liu F. Reasons for healthcare workers becoming infected with novel coronavirus disease 2019 (COVID-19) in China. *J Hosp Infect* 2020.
- 10 International Council of Nurses. April 2020. [www.icn.ch/news/high-proportion-healthcare-workers-covid-19-italy-stark-warning-world-protecting-nurses-and](http://www.icn.ch/news/high-proportion-healthcare-workers-covid-19-italy-stark-warning-world-protecting-nurses-and)
- 11 Chang, Xu H, Rebaza A, Sharma L, Dela Cruz CS. Protecting health-care workers from subclinical coronavirus infection. *Lancet Respir Med* 2020;8:e13.
- 12 Liu Y, Yan LM, Wan L, et al. Viral dynamics in mild and severe cases of COVID-19. *Lancet Infect Dis* 2020.
- 13 Heneghan C, Brassey J, Jefferson T. SARS-CoV-2 viral load and the severity of COVID-19. Centre for Evidence-Based Medicine 2020.
- 14 WHO. Country & Technical Guidance - COVID-19. [www.who.int/emergencies/diseases/novel-coronavirus-2019/technical-guidance](http://www.who.int/emergencies/diseases/novel-coronavirus-2019/technical-guidance)
- 15 WHO. Rational use of personal protective equipment for coronavirus disease (COVID-19). [https://apps.who.int/iris/bitstream/handle/10665/331498/WHO-2019-nCoV-IPCPE\\_use-2020.2-eng.pdf](https://apps.who.int/iris/bitstream/handle/10665/331498/WHO-2019-nCoV-IPCPE_use-2020.2-eng.pdf)
- 16 The International Agency for the Prevention of Blindness (IAPB). COVID-19 Resources: Here is what we know. [www.iapb.org/news/covid-19-resources-here-is-what-we-know/](http://www.iapb.org/news/covid-19-resources-here-is-what-we-know/)
- 17 International Council of Ophthalmology (ICO). Coronavirus Information for Ophthalmologists. April 2020. [www.icoph.org/news/news\\_detail/598/Coronavirus-Information-for-Ophthalmologists.html](http://www.icoph.org/news/news_detail/598/Coronavirus-Information-for-Ophthalmologists.html)
- 18 Royal College of Ophthalmologists COVID-19 Clinical Guidelines. [www.rcophth.ac.uk/2020/03/covid-19-update-and-resources-for-ophthalmologists/](http://www.rcophth.ac.uk/2020/03/covid-19-update-and-resources-for-ophthalmologists/)
- 19 American Academy of Ophthalmologists (AAO). Coronavirus and Eye Care. <https://www.aao.org/headline/alert-important-coronavirus-context>
- 20 World Council of Optometry. Statement regarding COVID-19. <https://worldcouncilofoptometry.info/wco-statement-concerning-covid-19/>
- 21 Centers for Disease Control (US) Strategies to Optimise the Supply of PPE. <https://www.cdc.gov/coronavirus/2019-ncov/hcp/ppe-strategy/index.html>
- 22 American Academy of Ophthalmologists (AAO). List of urgent and emergent ophthalmic procedures. [www.aao.org/headline/list-of-urgent-emergent-ophthalmic-procedures](http://www.aao.org/headline/list-of-urgent-emergent-ophthalmic-procedures)
- 23 King's College London Covid Tracker App. April 2020. [www.kcl.ac.uk/news/loss-of-smell-and-taste-a-key-symptom-for-covid-19-cases](http://www.kcl.ac.uk/news/loss-of-smell-and-taste-a-key-symptom-for-covid-19-cases)
- 24 NHS Self-isolation if you or someone you live with has symptoms – COVID-19. [www.nhs.uk/conditions/coronavirus-covid-19/self-isolation-advice](http://www.nhs.uk/conditions/coronavirus-covid-19/self-isolation-advice) (last reviewed 6 April 2020).
- 25 Centers for Disease Control and Prevention (CDC). Healthcare-associated Infections. [www.cdc.gov/hai/pdfs/ppe/ppe-sequence.pdf](http://www.cdc.gov/hai/pdfs/ppe/ppe-sequence.pdf)
- 26 Lai THT, Tang EWH, Chau SKY, Fung KSC, Li KKW. Stepping up infection control measures in ophthalmology during the novel coronavirus outbreak: an experience from Hong Kong. *Graefes Arch Clin Exp Ophthalmol* 2020.
- 27 Italian Ophthalmological Society, 2020. Directions for the Protection of Patients, Ophthalmologists, Health and Administrative Personnel. [https://amedeolucente.it/public/CORONAVIRUS\\_%20INDICAZIONI%20DELLA%20SOI\(1\).pdf](https://amedeolucente.it/public/CORONAVIRUS_%20INDICAZIONI%20DELLA%20SOI(1).pdf)
- 28 Public Health England. COVID-19 personal protective equipment: Patient use of PPE. [www.gov.uk/government/publications/wuhan-novel-coronavirus-infection-prevention-and-control/covid-19-personal-protective-equipment-ppe#patient-use-of-ppe](http://www.gov.uk/government/publications/wuhan-novel-coronavirus-infection-prevention-and-control/covid-19-personal-protective-equipment-ppe#patient-use-of-ppe). Updated 6 April 2020.
- 29 Centers for Disease Control and Prevention. Use of Cloth Face Coverings to Help Slow the Spread of COVID-19. [www.cdc.gov/coronavirus/2019-ncov/prevent-getting-sick/diy-cloth-face-coverings.html](http://www.cdc.gov/coronavirus/2019-ncov/prevent-getting-sick/diy-cloth-face-coverings.html)
- 30 Davies A, Thompson KA, Giri K, Kafatos G, Walker J, Bennett A. Testing the efficacy of homemade masks: would they protect in an influenza pandemic? *Disaster medicine and public health preparedness* 2013;7:413-418.
- 31 Liang L, Wu P. There may be virus in conjunctival secretion of patients with COVID-19. *Acta Ophthalmol* 2020.
- 32 Li JO, Lam DSC, Chen Y, Ting DSW. Novel Coronavirus disease 2019 (COVID-19): The importance of recognising possible early ocular manifestation and using protective eyewear. *Br J Ophthalmol* 2020;104:297-298.
- 33 Public Health England. COVID-19: infection, prevention and control <https://www.gov.uk/government/publications/wuhan-novel-coronavirus-infection-prevention-and-control>
- 34 Centres for Disease Control (CDC) Coronavirus Disease 2019 (COVID-19) National Center for Immunization and Respiratory Diseases (NCIRD), Division of Viral Diseases. Strategies for Optimizing the Supply of Eye Protection [www.cdc.gov/coronavirus/2019-ncov/hcp/ppe-strategy/eye-protection.html](http://www.cdc.gov/coronavirus/2019-ncov/hcp/ppe-strategy/eye-protection.html)