

Review Article

Labia Minora Reduction Techniques:
A Comprehensive Literature Review

Carlo Maria Oranges, MD; Andrea Sisti, MD; and Giovanni Sisti, MD

Aesthetic Surgery Journal
2015, Vol 35(4) 419–431
© 2015 The American Society for
Aesthetic Plastic Surgery, Inc.
Reprints and permission:
journals.permissions@oup.com
DOI: 10.1093/asj/sjv023
www.aestheticsurgeryjournal.com
OXFORD
UNIVERSITY PRESS

Abstract

Background: Many studies of techniques to reduce the labia minora have been published in recent decades, including case reports and retrospective case series. However, to date, there has been no study of the overall complications or satisfaction rates associated with the broad spectrum of techniques.

Objectives: The authors performed a comprehensive literature review to determine outcomes and complications of labiaplasty techniques, including patient satisfaction.

Methods: A search on PubMed/Medline was performed with the keywords *labiaplasty*, *labioplasty*, *labial hypertrophy*, and *techniques plus labia minora reduction*. The inclusion criterion was clinical studies in which techniques of labia minora reduction were described. Excluded from the study were publications not dealing with surgical procedures and review articles.

Results: Thirty-eight studies, published from 1971 through 2014, were included; this represented 1981 treated patients. Eight labiaplasty techniques were identified from these studies: edge resection, wedge resection, deepithelialization, W-plasty, laser labiaplasty, custom flask, fenestration, and composite reduction. Satisfactory results, judged from clinical examination, were observed with all 8 techniques. Few postoperative complications occurred. In a small number of cases, complications required surgical revision or secondary resection.

Conclusions: All 8 labiaplasty techniques resulted in good outcomes, including high patient satisfaction and low morbidity.

Level of Evidence: 4

Accepted for publication January 29, 2015.

Although the etiology of labia minora hypertrophy (LH) is not known, several hypotheses have been proposed. It has been postulated that LH is a hormonally related lesion, similar to fibroepithelial stromal polyps,¹ or a manifestation of chronic lymphedema, rather than an anatomic variant.² Initial hypotheses suggesting that LH was associated with masturbation or multiple pregnancies have been discarded over the years. The simultaneous presence of labia majora hypertrophy is rarely described in the literature.^{3,4}

The most recent classification of LH takes into consideration the protrusion of the labia minora beyond the fourchette and the labia majora; it includes 4 classes based on size and location.⁵

The primary indications for labiaplasty are (1) hypertrophy of labia minora with aesthetic or functional impairment and (2) labial asymmetry.⁶

Functional problems related to LH include pain while wearing tight clothing or during athletic activities; psychological

distress can result from the undesirable aesthetic appearance.⁷ The most common reason for seeking labiaplasty is dissatisfaction with labial appearance.⁸ Other common concerns are discomfort or pain during sexual activity, general irritation, and issues related to hygiene or infection.

Dr Oranges is a Resident in the Plastic, Reconstructive and Aesthetic Surgery School, Marche Polytechnic University, Ancona, Italy. Dr A. Sisti is a Resident in the General and Specialist Surgery Department, Plastic Surgery Division, University of Siena, Siena, Italy. Dr G. Sisti is a Resident in the Department of Science for Woman and Child Health, University of Florence, Florence, Italy.

Corresponding Author:

Dr Andrea Sisti, General and Specialist Surgery Department, Plastic Surgery Division, University of Siena, Siena, Italy.
Email: asisti6@gmail.com

The primary goal of the operation is to attain minimal or no protrusion of the labia minora beyond the labia majora when the patient is standing.⁹ (Many patients inquire about insurance coverage for this surgery; the ICD-9 code 56,620 can be utilized [simple partial vulvectomy].)

Although the real need for this surgery is controversial,¹⁰ the high degree of patient satisfaction is incentive to perpetuate this practice.^{11,12} However, the anatomy of many women who desire this surgery is considered normal, which raises doubts about the main indication for the procedure.¹³⁻¹⁵ Body dysmorphic disorder should always be excluded before surgery to avoid operating on women who have an altered perception of their body which may originate from social popular models or relevant personal experiences.¹⁶⁻¹⁹ Some authors emphasize the cosmetic nature of this surgery, whereas others view it as a reconstructive technique.²⁰⁻²² In recent decades, many techniques for labia minora reduction have been described. The most common are edge resection,^{23,24} wedge resection,²⁵ Z-plasty,²⁶ deepithelialization,²⁷ W-plasty,²⁸ and laser labiaplasty.²⁹ The aim of the present article is to review outcomes of the various labiaplasty techniques, including associated complications.

METHODS

To determine the efficacy and complications of techniques to reduce the labia minora, we performed a literature review of studies on the surgical treatment of LH. From August 2014 to October 2014, a systematic review of the PubMed database was performed with the following search algorithm: [(labiaplasty) OR (labioplasty) OR (labial hypertrophy) OR (techniques) OR (labia minora reduction)]. There were no restrictions on time or language of publication. Additional articles were considered after reviewing references of the publications identified initially.

Articles were required to be of the following types: case study, case report, case series, clinical trial, open-label prospective study, or retrospective study. Also necessary for inclusion was the utilization of labiaplasty as surgical therapy. Excluded from the analysis were literature reviews, articles in which labiaplasty was not viewed from a surgical perspective, and publications in which it was impossible to determine the specific technique of labiaplasty.

All publications were screened manually. Three investigators independently reviewed and extracted data from the papers, according to the predetermined criteria.

The following information was documented and tabulated for each article: author name(s), year of publication, number of patients, age of patients, relevant medical history of patients, surgical technique, outcomes, and complications. All types of labiaplasty were considered, including edge resection, wedge resection, Z-plasty, deepithelialization, W-plasty, laser labiaplasty, and personal techniques. Quality assessment of the studies included representativeness of the study

samples, randomization, baseline comparability of groups, credibility of data collection tools, attrition rate, and reliability.

RESULTS

We initially identified 62 full-text articles, 24 of which did not meet the inclusion criteria. Therefore, our analysis comprised 38 studies, which were published from 1971 through 2014 (Table 1). Nine were case reports, and 29 were retrospective studies. Overall, 1981 treated patients were represented (age range, 10-67 years). Eight techniques (Figures 1-11) of labia minora reduction were identified: composite reduction labiaplasty (n = 812), wedge resection (n = 702), deepithelialization (n = 173), edge resection (n = 161), laser labiaplasty (n = 55), custom flask labiaplasty (n = 50), W-shaped resection (n = 25) as described by Maas and Hage,²⁸ and fenestration labiaplasty with inferior flap transposition (n = 3) according to Ostrzenski.³⁰ Nearly all labiaplasties were bilateral.

The only relevant associated conditions were congenital neurologic abnormalities: spina bifida,^{31,32} lipomeningocele,³¹ and myelomeningocele.³³ The association between LH and multiparity was not significant. It appeared that young age was not considered a contraindication for labia minora reduction. Some patients were adolescents or younger (age 10) at the time of surgery.^{32,34} In one case, labiaplasty was performed on a 30-year old who, during childhood, experienced LH and precocious development of pubic hair after treatment with an androgenic medication at 2 to 3 years of age.³⁵

In most studies, outcomes were evaluated from satisfaction questionnaires completed by the patients. Satisfaction rates always exceeded 90%. Complications reportedly occurred in 134 (6.76%) of the 1981 patients. The most common complications were wound dehiscence, hematoma, postoperative bleeding, and urinary retention. Hematoma was most commonly associated with the Z-plasty described by Giraldo et al²⁶ (6 of 15 patients; 40%). Inferior wedge resection with superior pedicle flap reconstruction, as described by Munhoz et al,³⁶ resulted in the highest percentage of wound dehiscence (2 of 21 patients; 9.5%). No complications were serious, and all resolved easily. Revision surgery was needed in a small number of patients (n = 82 of 1981 patients; 4.1%) due to wound healing complications or postoperative bleeding. Secondary resection was performed in 34 patients because the desired labial length had not been achieved after the first operation. The highest percentage of reoperations (7%; 11 of 163 patients) was reported by Rouzier et al.³⁷

DISCUSSION

Labiaplasty is becoming increasingly popular and consequently, has drawn greater scrutiny. Many gynecologic surgeons are reluctant to perform this operation, emphasizing potential complications (such as paresthesia) and patient dissatisfaction.

Table 1. Summary of Studies on Labiaplasty (Listed by Year of Publication)

| Author (First Listed), Year | Study Design | No. of Patients | Geographic Location | Age of Patients (y) (Relevant Medical History, if Noted) | Labiaplasty Technique | General Outcome | Complications |
|-------------------------------------|---------------------------|-----------------|---------------------|----------------------------------------------------------------------------------------------------------------------------------------------------------------|-----------------------------------------------------------------------|------------------------------------------------------------------------------------------------------------------------------------------------------------------------------------------------------------------------------------------------------------------------------------------------------------------------------------------------------------------------|--------------------------------------------------------------------------------------------------------------------------|
| Martincik, 1971 ⁴⁸ | Retrospective case series | 12 | Czech Republic | Not specified | Posterior wedge resection | Favorable in 11 of 12 patients | Hemorrhage (n = 1) |
| Radman, 1976 ⁵⁶ | Retrospective case series | 2 | United States | 17 and 14 | Edge resection (direct excision) | Normal female genitalia observed during follow-up | None reported |
| Honore, 1978 ⁵⁷ | Retrospective case series | 2 | Canada | 19 (thyroidectomy for thyrotoxicosis) 26 (benign hydatiform mole 7 y earlier; a more recent spontaneous abortion [at 10 wk]; 3 cesarean section deliveries) | Edge resection (direct excision) | Favorable | None reported |
| Bernal Bastidas, 1981 ⁵⁸ | Case report | 1 | Mexico | 13 | Edge resection (direct excision) | Favorable | None reported |
| Hodgkinson, 1984 ⁴³ | Retrospective case series | 3 | United States | 30 (n = 2) and 36 | Edge resection (direct excision) | Protrusion of the labia minora past the majora was aesthetically and functionally unsatisfactory | None reported |
| Kato, 1988 ³¹ | Retrospective case series | 3 | Japan | 22 (myelodysplastic syndrome with spina bifida occulta) 16 (myelodysplastic syndrome) 33 (lipomeningocele in lumbosacral region) | Edge resection (direct excision) | Satisfactory at follow-up | Hematoma (n = 1) |
| Gowen, 1988 ⁵⁹ | Case report | 1 | United States | 49 (white nulligravid woman who contracted poliomyelitis in infancy; has an iron lung for respiratory support) | Edge resection (direct excision) | Favorable | None reported |
| Chavis, 1989 ³⁵ | Case report | 1 | United States | 30 (nulliparous; treated with androgenic medication at age 2-3 y, resulting in labial hypertrophy and precocious development of pubic hair) | Edge resection (direct excision) | Patient was extremely pleased with resulting size and configuration of the labia | None reported |
| Fliegner, 1997 ⁶⁰ | Case report | 1 | Australia | 30 (multipara) | Edge resection (direct excision) | Favorable | None reported |
| Alter, 1998 ²⁵ | Retrospective case series | 4 | United States | 24 (n = 2), 26, and 32 | Wedge resection | All patients were satisfied | None reported |
| Rouzier, 2000 ³⁷ | Retrospective case series | 163 | France | Age range, 12-67; median, 26 | Inferior wedge resection | Anatomic results were satisfactory for 151 patients (93%). 98 questionnaires were completed: 81 patients (83%) stated that results after surgery were satisfactory; 87 patients (89%) were satisfied with aesthetic result; 91 patients (93%) approved of functional outcome; 4 patients (4%) would not undergo the same procedure again. | 11 patients (7%) required a second procedure because minimal wound dehiscence resulted in an imperfect aesthetic outcome |
| Maas, 2000 ²⁸ | Retrospective case series | 13 | Netherlands | Age range, 19-42; mean, 30 | W-shaped resection with interdigitated suturing of protuberant labium | Postoperative period was uneventful for 11 patients. All patients had minimal postoperative discomfort, and, by 2 wk after surgery, reported no pain. Swelling subsided within 4 wk; by that time, all patients were pleased with appearance of genitalia and resolution of original problems; no patient reported any remaining discomfort during sexual intercourse. | Hematoma (n = 1), wound dehiscence (n = 1) |

(Continued)

Table 1. (Continued)

| Author (First Listed), Year | Study Design | No. of Patients | Geographic Location | Age of Patients (y) (Relevant Medical History, if Noted) | Labiaplasty Technique | General Outcome | Complications |
|---------------------------------------|---------------------------|-----------------|---------------------|--------------------------------------------------------------------------------|-------------------------------------------------------------------------------------------------------------------------------------------------|--------------------------------------------------------------------------------------------------------------------------------------------------------------------------------------------------------------------------------------------------------------------------------------------|--------------------------------------------------------------------------------------|
| Choi, 2000 ²⁷ | Retrospective case series | 6 | Korea | Age range, 13-40; mean, 26.5 | Deepithelialization | All patients were satisfied | None reported |
| Giraldo, 2004 ²⁶ | Retrospective case series | 15 | Spain | Age range, 22-45; mean, 34 | Central wedge resection of labia minora with a 90° Z-plasty | All patients were fully satisfied with appearance of external genitalia (no bumps between labia minora and majora) and with genital cosmetic rejuvenation resulting from smaller and finer labia minora | Wound dehiscence (n = 2), hematoma (n = 6) |
| Sakamoto, 2004 ⁶² | Case report | 1 | Japan | 19 (nulliparous Japanese woman) | Edge resection (direct excision) | At 12-wk follow-up, appearance of vulva was normal and patient reported satisfactory resumption of sexual activity | None reported |
| Krizko, 2005 ⁶³ | Retrospective case series | 26 | Czech Republic | Mean age, 23.5 | Wedge resection | High satisfaction (98% after 2 mo) | None reported |
| Munhoz, 2006 ³⁶ | Retrospective case series | 21 | Brazil | Age range, 31-49; mean, 38 | Inferior wedge resection and superior pedicle flap reconstruction | Mean follow-up period, 46 mo; cosmetic result was considered good or very good by 85.7% of patients; 95.2% were very satisfied with procedure itself | 5 complications among the 21 patients (23.8%) |
| Pardo, 2006 ²⁹ | Retrospective case series | 55 | Chile | Age range, 10-55; 11% were <20 | Laser | Aesthetic satisfaction: 50 (91%) were very satisfied; 5 (9%) were satisfied; functional satisfaction: all 55 (100%) were very satisfied | Wound dehiscence (n = 1) |
| Alter, 2008 ⁴⁵ | Retrospective case series | 407 | United States | Age range, 13-63; mean, 32.4 (all but 14 [3%] underwent bilateral labiaplasty) | Extended central wedge resection (nearly all patients had excision[s] in the lateral clitoral hood, with extension via the hockey-stick design) | Patients who responded to questionnaire (166/407) were pleased with surgery; mean satisfaction score was score was 9.2/10 (10 = most pleased); improvement in self-esteem (93%), sex life (71%), and discomfort (95%) was reported; 163 respondents (98%) would undergo the surgery again. | Low rate of significant complications (4%); 12 patients (2.9%) underwent reoperation |
| Lynch, 2008 ³² | Retrospective case series | 2 | New Zealand | 10 and 12 (the older patient has spina bifida and neurogenic bladder) | Edge resection (direct excision) | Results were satisfactory, with no further enlargement of labia minora | None reported |
| Sanjuan Rodriguez, 2009 ⁶¹ | Retrospective case series | 2 | Spain | 12 and 13 1 unilateral, 1 bilateral | Edge resection (direct excision) | High satisfaction and excellent aesthetic results | None reported |
| Jothilakshmi, 2009 ³⁴ | Retrospective case series | 6 | United Kingdom | Age range, 11-16 | Edge resection (direct excision) | All patients were satisfied | None reported |
| Hong, 2009 ⁴⁶ | Retrospective case series | 11 | China | Age range, 20-37 | Central wedge resection and asymmetric Z-plasty for labia minora reduction ^a | Good results | None reported |
| Kruk-Jeromin, 2010 ⁶⁴ | Retrospective case series | 21 | Poland | Age range, 18-35 (hypertrophy was bilateral in all cases, and asymmetric in 5) | Edge resection (direct excision) | Good aesthetic and functional results; all patients were fully satisfied with outcome | None reported |
| Solanki, 2010 ⁴⁹ | Retrospective case series | 12 | United Kingdom | Age range, 15-52; mean, 32 | Maas/Hage technique (running interdigitating W-shaped excision) | At final follow-up, all patients were very satisfied with appearance of external genitalia and reported no recurrence of previous symptoms | Hematomas, bilateral (n = 1), urinary retention (n = 1), minor oozing (n = 1) |

(Continued)

Table 1. (Continued)

| Author (First Listed), Year | Study Design | No. of Patients | Geographic Location | Age of Patients (y) (Relevant Medical History, if Noted) | Labiaplasty Technique | General Outcome | Complications |
|-------------------------------|---------------------------|-----------------|---------------------|---------------------------------------------------------------------------------------------------------------------------------------------------|-----------------------------------------------------------------------------------------------------------------------------------------------------------------------------------------------------------------------------------------------------------------------------------------------|-------------------------------------------------------------------------------------------------------------------------------------------------------------------------------------------------------------------------------------------------------------------------------------------------------------------------------|---------------------------------------------------------------------------------------------------------------------------------------------------|
| Ellsworth, 2010 ⁵¹ | Retrospective case series | 12 | United States | Not specified | Edge excision (n = 4) Deepithelialization technique, modified from that introduced by Choi/Kim ²⁷ (n = 5) Wedge resection with pedicled flap closure, as described by Alter ²⁵ and modified by Rouzier ³⁷ et al and Munhoz et al ³⁶ (n = 3) | Follow-up period, 6 wk-2 y (mean, 7.5 mo) 92% of patients were very satisfied with results and indicated that they would undergo the procedure again. One patient, who underwent edge excision, was not satisfied; she felt that her labia minora had been overly reduced. | Complications were minimal; 3 patients had minor wound-healing difficulties, all of which resolved spontaneously (1 from each technique category) |
| Trichot, 2011 ⁶⁵ | Retrospective case series | 21 | France | Age range, 15-52; mean, 29; 5 (24%) were <18 | Inferior wedge resection | All patients reported overall satisfaction with outcome. All but 1 patient considered the aesthetic outcome satisfactory. The dissatisfied patient felt that aesthetic outcome was not in line with her expectations; however, overall she was satisfied with the operation and reported improvement in original symptoms. | None reported |
| Miklos, 2011 ³ | Case report | 1 | United States | 36 (white; gravida 1, para 1) | Edge resection (direct excision) | At 6-wk follow-up visit, patient stated that she was pleased with cosmetic outcome | None reported |
| Cao, 2012 ⁵⁰ | Retrospective case series | 167 | China | Age range, 20-43 | Deepithelialized reduction of central and posterior labia minora | Aesthetic appearance was judged satisfactory by all patients. Previous functional symptoms resolved in all patients. Only 2 patients felt that desired reduction was not fully achieved (ie, that labia minora were still slightly redundant); revisional resection of labial edges was performed. | Wound dehiscence (n = 1) |
| Cayrac, 2012 ⁶⁶ | Retrospective case series | 26 | France | Age range, 14-64 (4 minors); mean, 25 (7 patients were virgins before surgery; 4 patients were multiparous [15%]; the others were nulliparous) | Edge resection (direct excision) | All patients were satisfied with aesthetic result | None reported |
| Triana, 2012 ⁶⁷ | Retrospective case series | 74 | Colombia | Age range, 23-47 | Edge resection (direct excision) | All patients had improvement in sexual life and reported no discomfort with coitus. Clitoral sensibility was preserved in all patients. Satisfaction rate was high (92%), and all patients stated they would undergo the procedure again. | 2 patients had local wound infection, which resolved with antibiotics; 1 patient had adverse reaction to the Vicryl suture |
| Kelishadi, 2013 ⁴⁷ | Retrospective case series | 22 | United States | Age range, 19-57; mean, 35; median, 33 | Posterior wedge resection | Follow-up period, 2 wk-1.5 y (mean, 3 mo); at follow-up, no patient reported any paresthesia or pain/problems with penetrating vaginal intercourse | Wound dehiscence (n = 1), hematoma (n = 1) |

(Continued)

Table 1. (Continued)

| Author (First Listed), Year | Study Design | No. of Patients | Geographic Location | Age of Patients (y) (Relevant Medical History, if Noted) | Labiaplasty Technique | General Outcome | Complications |
|------------------------------------|---------------------------|-----------------|---------------------|---------------------------------------------------------------------------------------------------------------------------------------------------------------------------------------------------------------------------------------------------------------------|------------------------------------------------------------------------------------|-------------------------------------------------------------------------------------------------------------------------------------------------------------------------------------------------------------------------------------------------------------------------------------------------------------------------------------------------------------------------------------------------------------------------------------------------------------------------------------------------------------------------------|---------------------------------------------------------------------------------------------------------------------------------------------------------------------------------------------------------------------------------------------------------------------------------------------------------------------------------|
| Gress, 2013 ⁵³ | Retrospective case series | 812 | Germany | Not specified | Composite reduction | Follow-up period, 6 mo: very high level of overall satisfaction with outcome of procedure and aesthetic result; average satisfaction score was 9.4/10. Functional problems resolved completely in 92.3% of patients, and psychological distress was relieved completely for 89.7%. No improvement of functional problems was reported by 2.2% of patients, and 1.3% rated their psychological distress as unchanged. In approximately 35%, sexual excitability increased after the procedure. | Wound-healing complications required surgical revision in 6.4% of patients. Postoperative bleeding required surgical treatment in 7 patients. Asymmetric outcomes necessitated surgical correction in 2.3% of cases. Secondary resection was performed in 4.2% of patients because desired labial length had not been achieved. |
| Gonzalez, 2013 ⁵⁴ | Retrospective case series | 50 | United States | Age range, 17-60; mean, 37.7 | Custom flask | Of the 50 patients, 27 provided responses after surgery. Of the 27 respondents, 25 (93%) were satisfied or very satisfied. Of the dissatisfied patients, 1 felt too much tissue had been removed; 1 felt not enough tissue had been removed. | Wound dehiscence (n = 1) |
| Wagner, 2013 ⁶⁸ | Case report | 1 | United States | 23 (heterotopic breast tissue in vulva) | Incision made along the "earmuff" line | Postoperative period was uneventful. Significant labial reduction was achieved, along with reestablishment of normal anatomic relationships and space between clitoral hood and labia minora. | None reported |
| Wu, 2013 ³³ | Case report | 1 | United States | 13 (myelomeningocele and frequent urinary tract infections, associated with greater difficulty performing intermittent catheterization) | Edge resection (direct excision) | Patient and her mother were very happy with cosmetic and functional outcomes | None reported |
| Ostrzenski, 2014 ³⁰ | Retrospective case series | 3 | United States | 22, unmarried Caucasian college student (gravida 0, para 0) who had been sexually active; 27, married Caucasian woman (gravida 3, 3-0-0-3), high school teacher, sexually active 22 unmarried Caucasian woman (gravida 0, para 0); professional ballet dancer | Ostrzenski's fenestration technique with inferior flap transposition ³⁰ | Outcomes attained included reduction of labial height and length (which achieved symmetry); preservation of natural color and contour of labium minus; and restoration or creation of a natural appearance of labium frenulum (posterior edge of fossa navicularis). Postoperatively, medical and emotional symptoms and signs resolved; pleasing surgical outcomes exceeded patients' aesthetic expectations. Body image, social openness, and self-confidence improved in all patients, and intimate interaction increased. | None reported |
| Yurteri-Kaplan, 2014 ⁶⁹ | Case report | 1 | United States | Not specified (width of right labia minora, 5 cm; width of left labia minora, 8 cm) | Edge resection (direct excision) | Favorable | None reported |

³The incision was designed, and redundant tissue was resected quantitatively. The Z-plasty was modified to a rectangle flap with deviated incision. The incisions at the 2 surfaces of the labia minora were positioned in the opposite direction. The 2 rectangle flaps were inserted to form the free edge of the labia minora. This technique is based on Giraldo's procedure.²⁶

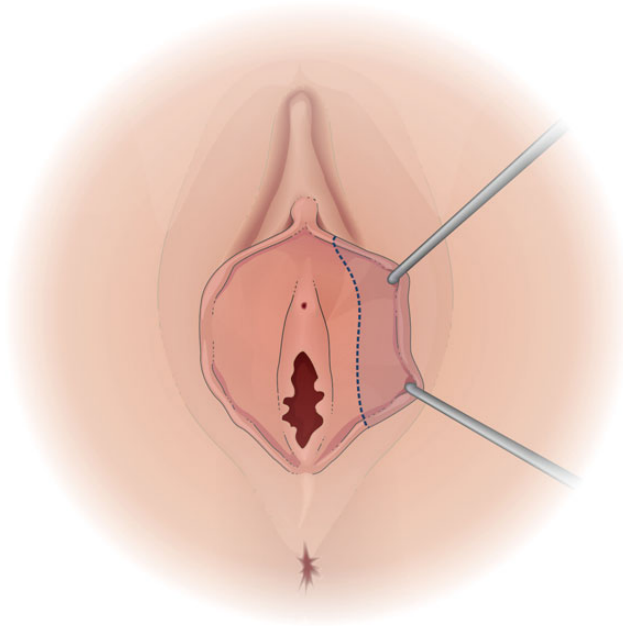


Figure 1. The edge resection technique.

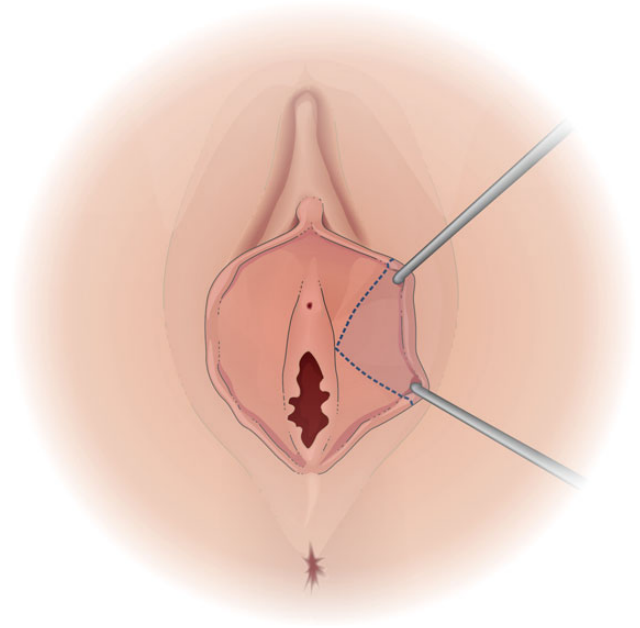


Figure 2. The wedge resection technique, as described by Alter²⁵ in 1998.

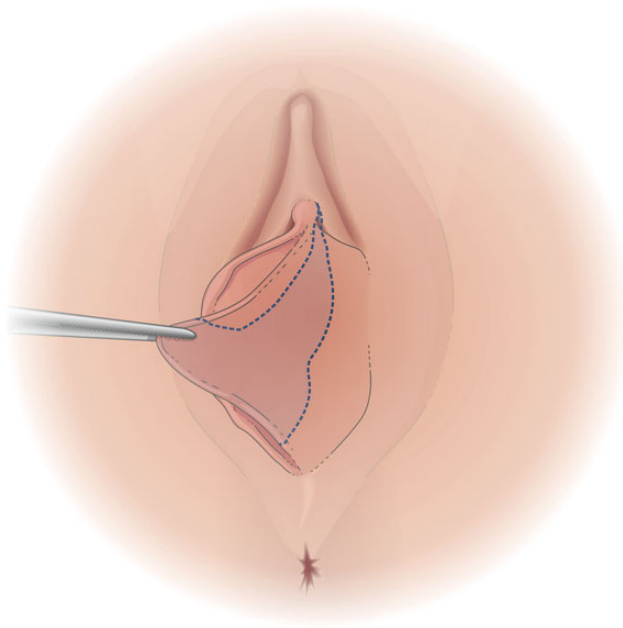


Figure 3. The extended central wedge resection technique, as described by Alter⁴⁵ in 2008.

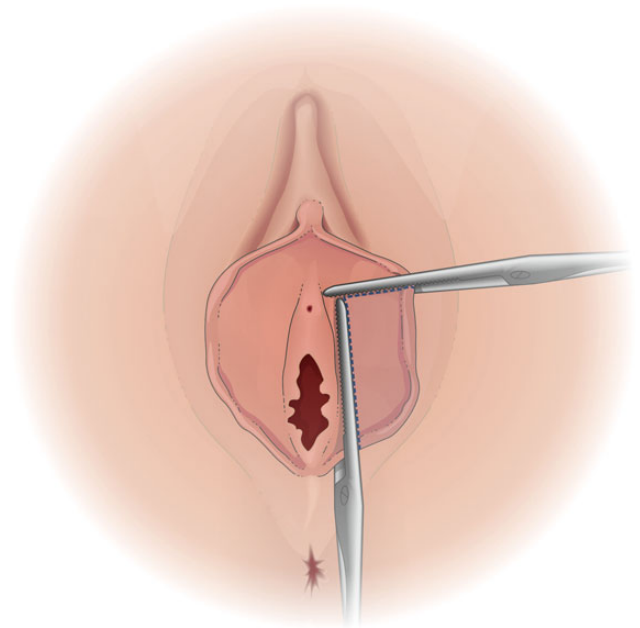


Figure 4. The inferior wedge resection technique.

Although recent reviews have been published,³⁸⁻⁴¹ a comprehensive literature review has not.

Motakef et al⁴² selected 19 articles, representing 1949 patients treated with vaginal labiaplasty and focused primarily on classification and standardized practice guidelines. With our inclusion criteria, a greater number of patients were represented ($n = 1981$). We considered all English and non-English

literature, and determined overall complication and satisfaction rates across the spectrum of labiaplasty techniques.

A limitation of our analysis is the high heterogeneity of the study populations. Selection bias and lack of standardized outcome measures prevented a proper meta-analysis. Although this review does not constitute a meta-analysis, we assessed the literature critically and aimed to

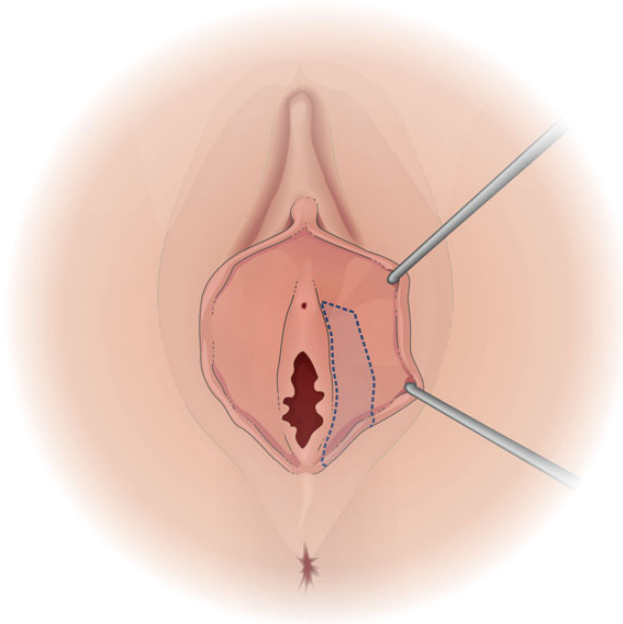


Figure 5. The posterior wedge resection technique, as described by Kelishadi et al⁴⁷ in 2013.

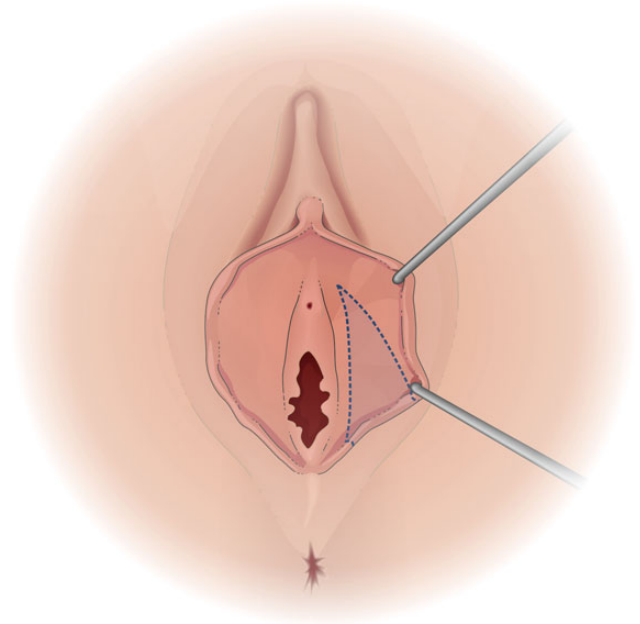


Figure 6. The posterior wedge resection technique, as described by Martincik and Malinovsky⁴⁸ in 1971.

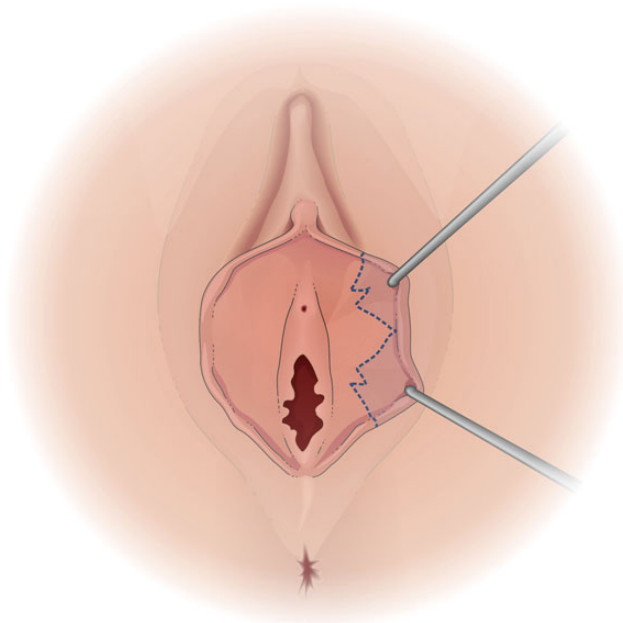


Figure 7. The W-shaped resection, as described by Mass and Hage²⁸ in 2000.

identify high-quality studies. Many technique-related studies demonstrating favorable results may be biased by authors who wish to promote their preferred techniques.

Edge Resection

Edge resection (direct excision) was the first labiaplasty technique described in literature,²³ and it is still performed often

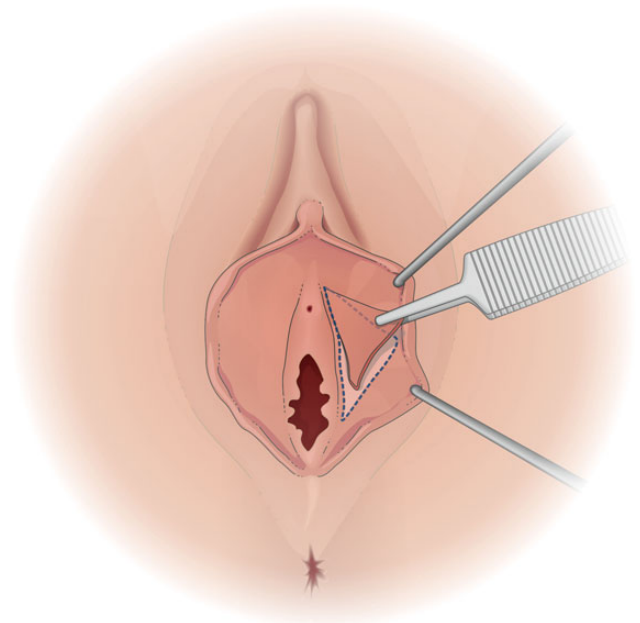


Figure 8. The deepithelialization technique, as described by Choi and Kim²⁷ in 2000.

(Figure 1). In 16 of the 17 articles published between 1976 and 2014, favorable outcomes in terms of patient satisfaction and low morbidity were noted. Only Hodgkinson and Hait⁴³ reported aesthetically and functionally unsatisfactory protrusion of the labia minora. Complications are usually related to excess tissue resection, which can result in complete amputation of the labia minora or centrally foreshortened labia minora with “dog ears” superiorly and inferiorly. It is difficult to treat these deformities

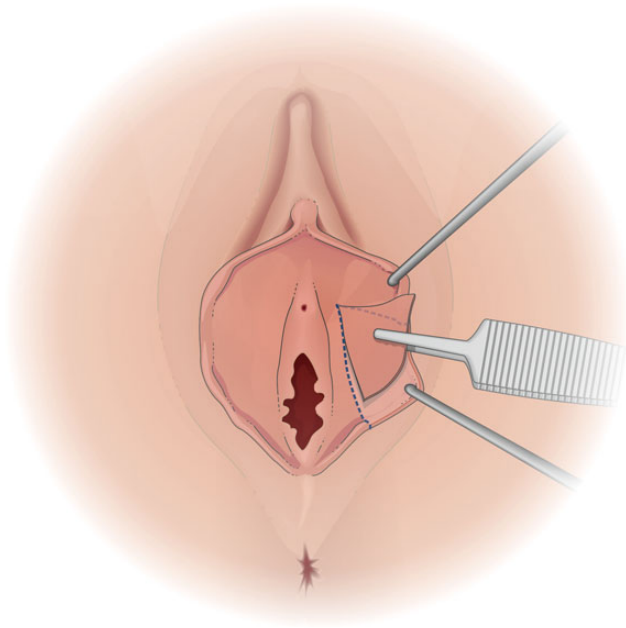


Figure 9. The deepithelialization technique, as described by Cao et al⁵⁰ in 2012.

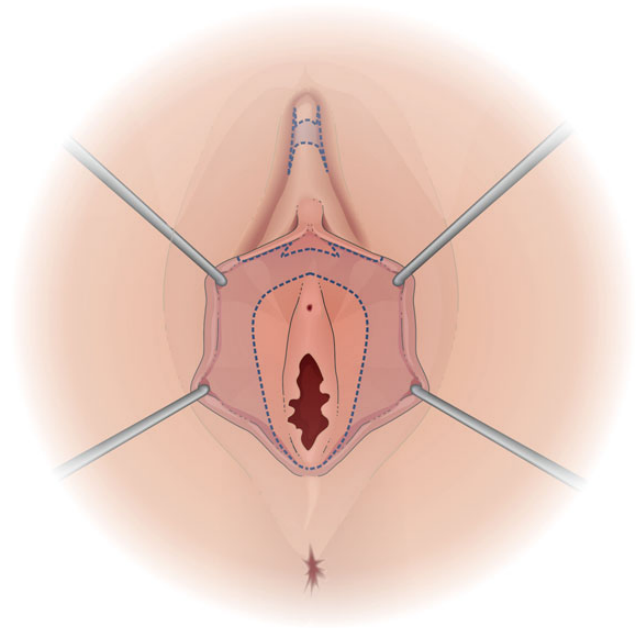


Figure 10. Composite reduction labiaplasty, as described by Gress⁵³ in 2013.

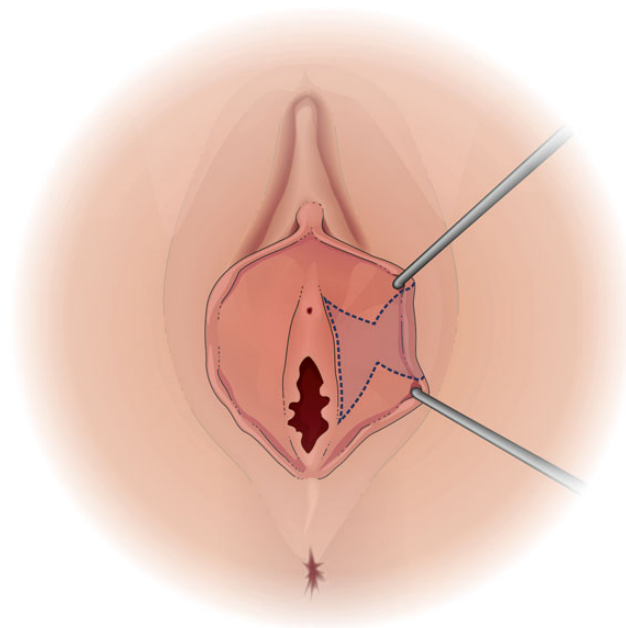


Figure 11. Custom flask labiaplasty, as described by Gonzalez et al⁵⁴ in 2013.

because of the deficit of central labial tissue. For patients whose clitoral hood is prominent preoperatively, persistent protrusion and bulk of the clitoral hood may be a complication.⁴⁴

Wedge Resection

In 1998, Alter²⁵ introduced the wedge resection technique (Figure 2). Its main indication is protrusion of the labia minora extending at least 2 cm beyond the fourchette.⁵ A

V-shaped wedge is excised from the most protuberant part of the labia minora. The incised edges are then approximated, leaving a free border of the reduced labia without an exposed scar. This technique enables considerable reduction of the labia while maintaining a natural edge. A modified technique involving wider resection of the labia minora was described by Alter⁴⁵ in 2008 (Figure 3). In that study of 407 patients, the mean patient satisfaction score was high (9.2/10), there were few

significant complications (4%), and the reoperation rate was low (2.9%).

In 2000, Rouzier et al³⁷ described a modified version of the original Alter original technique: inferior wedge resection (Figure 4). Anatomic results were satisfactory for 93% of patients; the other 7% underwent secondary labiaplasty because of minimal wound dehiscence that resulted in an imperfect aesthetic outcome.

In 2006, Munhoz et al³⁶ described a reconstruction technique that involved creation of a superior flap. With this technique, the angle and extent of the wedge resection vary depending on the quantity of tissue excess and the degree of cutaneous/mucosal laxity. The superior wedge-shaped flap is designed on the remaining upper part of the labia minora. The mean follow-up period in their study was 46 months. The cosmetic result was considered good or very good by the surgeon in 85.7% of cases, and 95.2% of patients were very satisfied with their outcome. Twenty-one patients (23.8%) experienced a complication.

Central wedge resection of the labia minora, with a 90-degree Z-plasty, was introduced by Giraldo et al²⁶ in 2004. In their study, all patients were fully satisfied with the appearance and cosmetic rejuvenation of the external genitalia (there were no bumps between the labia minora and majora). In 2009, Hong et al⁴⁶ applied the same technique and reported high patient satisfaction and a very low complication rate; however, their case series was relatively small (n = 11).

Posterior wedge resection was introduced by Kelishadi et al⁴⁷ in 2013 (Figure 5). Posterior wedge boundaries resection is initially outlined with intraoperative marking, first along the lateral border of the labia minora to preserve the natural pigment and tissue. The marking continues infero-superiorly and proceeds medially down to the base of the labia minora, approximately 1 cm up to the frenulum. The marking then continues posteriorly, to the posterior fourchette and is stopped prior to reaching the midline. Parallel markings are made on the mucosal side. The mean follow-up period in their study was 3 months (range, 2 weeks to 1.5 years). Throughout follow-up, there were no reports of paresthesia or of pain/problems with vaginal intercourse. Only 2 complications of significance were observed: dehiscence (n = 1) and hematoma (n = 1).

Our literature search revealed that a very similar technique, called *resectio cuneiformis labii minoris*, had been described earlier (in 1971) by Martincik and Malinovsky⁴⁸ (Figure 6); it consists of removal of a posterior wedge of hypertrophic labium minoris. Satisfactory outcomes were achieved for 11 of their 12 patients. Postoperative hemorrhage occurred in 1 patient.

W-Shaped Resection

In 2000, Maas and Hage²⁸ introduced W-shaped resection with interdigitated suturing of the protuberant labia minora

(Figure 7), which they performed in 13 patients. Later, in 2010, Solanki et al⁴⁹ applied the same technique to 12 patients. The closure of the opposing W-shaped incisions results in a tensionless zigzag suture line running obliquely across the edge of the labium. Both groups of authors^{28,49} believe that the running W-shaped resection technique avoids many potential problems that can occur with other techniques. Wound contraction (both longitudinally and transversely), reduction of the risk of wound dehiscence, and advancement of the posterior fourchette are considered advantages of this technique. Both groups^{28,49} reported that all patients were very satisfied with the resulting appearance of their external genitalia, and there was no recurrence of preoperative symptoms at the time of final follow-up. Among the collective 25 patients, 5 complications were observed (2 hematomas, 1 urinary retention, 1 minor oozing, and 1 wound dehiscence). This technique leaves intact the anterior and posterior commissure and the tissue around the base of the labia minora. It does not affect the branches of the superficial perineal nerve entry, thus preserving sexual function and sensation.²⁸

Deepithelialization

Choi and Kim²⁷ introduced the deepithelialization technique in 2000 (Figure 8). They performed labia minora reduction in 6 patients by deepithelialization of the central portion and reapproximation. Cao et al,⁵⁰ in 2012, described a modified version of this technique in which the deepithelialization is widened to the posterior aspect of the labium minoris (Figure 9). Their study included a large number of patients (n = 167) and demonstrated excellent results during follow-up. Aesthetic appearance was deemed satisfactory by all patients. The functional symptoms present preoperatively had resolved in all patients. Only 2 patients felt that the labia minora were still slightly redundant.

In 2010, Ellsworth et al⁵¹ reported on 5 patients treated with deepithelialization. Similar to the original description by Choi and Kim,²⁷ a vertical oval area on the central and lateral labial minora was identified and marked for deepithelialization. In 2013, Mayer⁵² criticized the deepithelialization technique because it may thicken the labial base. He hypothesized that this phenomenon is due to the vertical “telescoping” of the subcutaneous tissue. However, in all studies of the deepithelialization technique, complications were few: wound dehiscence (n = 1)⁵¹ and minor wound-healing difficulties (n = 1).⁵⁰

Laser Labiaplasty

A retrospective series of 55 patients treated with laser labiaplasty was presented in 2006 by Pardo et al.²⁹ A contact laser (CLMD 60 Contact Laser Nd YAG laser and sapphire scalpels ER2; Surgical Laser Technologies Inc, Montgomeryville,

PA), at an average power of 10 W, was utilized to remove excess tissue of the labia minora. Although blood loss was minimal, some small arteries occasionally required electrocautery. At the 60-day follow-up visit, all patients completed a satisfaction/acceptance questionnaire that included general and specific questions. All were very satisfied (91%) or satisfied (9%) with their aesthetic result. Functional satisfaction was 100%, and only 1 complication occurred (wound dehiscence). The authors surmised that laser labiaplasty may be easier to perform than conventional cautery or knife excision. However, a larger-scale study, designed to compare the techniques, is needed to verify this.

Composite Reduction

Composite reduction labiaplasty was described by Gress⁵³ (Figure 10) in a 2013 publication. The study included 812 patients and thus, is the largest to date. As opposed to other procedures that are fundamentally based on a reduction of the labia minora in the part below the clitoris, the composite procedure entails labial tissue reduction as well as removal of tissue located cranial or caudal to the clitoris. This creates separate segments positioned in a way that enables uniform reduction of the labia across their entire length, especially in the clitoral hood area, and permits additional correction of a protruding glans of the clitoris (clitoral protrusion) when indicated. Six months postoperatively, overall patient satisfaction was very high. The average aesthetic satisfaction score was 9.4 on a scale of 1 (lowest) to 10 (highest). An improvement of sexual excitability was observed in approximately 35% of the cases, especially among the patients who underwent correction of clitoral protrusion. This can be explained by the fact that with the clitoris positioned closer to the vaginal introitus, it is exposed to more direct stimulation.

Fenestration

In 2014, Ostrzenski³⁰ described a fenestration labiaplasty technique with inferior flap transposition, which obtains reductions in both height and length of the labia minora. Three patients underwent the procedure, which is performed in the shape of a “bicycle helmet.” By doing so, the labium is divided into 2 sections: the superior strip (which is partially detached from the rest of the labium) and the inferior part at the base of the labium minus. Symmetry was established, the natural color and contour of the labium minus were preserved, and a natural appearance of the labium frenulum (posterior edge of the fossa navicularis) was restored or created. The preoperative medical and emotional symptoms and signs resolved postoperatively. Surgical outcomes exceeded the patients’ aesthetic expectations. Moreover, all patients experienced meaningful improvement

in body image and self-confidence. Social openness also improved, and intimate interaction increased.

Flask Labiaplasty

In 2013, Gonzalez et al⁵⁴ reported the results of custom flask labiaplasty performed in 50 patients. The surgery was performed on an outpatient basis, and the patients received general anesthesia. The technique permits precise reduction of the labia minora in the necessary regions, in a customized manner, to achieve symmetry and a natural appearance of skin and to maintain the neurovascular pedicles (Figure 11). Of the 50 patients, 27 provided postoperative follow-up information for the study. Of the 27 respondents, 25 (93%) were satisfied with the results from surgery. Of the 2 patients who were not satisfied, 1 patient felt that too much tissue had been removed, and another felt that not enough tissue had been excised. Only 1 (2%) patient experienced a minor postoperative complication (wound dehiscence). Although the response rate was low (54%), the satisfaction rate was similar to that of other larger studies. Gonzalez et al⁵⁴ emphasized that the main advantages of this technique are preservation of the neurovascular supply of the labia, predictability and reproducibility of results, and a low rate of complications. The high level of patient satisfaction reflected the natural and aesthetically pleasing result.

General Considerations

Many factors should be considered before determining the type of labiaplasty to perform for LH. These include the experience of the surgeon, the extent of the hypertrophy, and specific characteristics of the patient. Exhaustive preoperative assessment and proper understanding of the patient’s expectations should be mandatory for this surgery, which is commonly performed to address aesthetic concerns.⁵⁵

CONCLUSIONS

High patient satisfaction and low complication rates were consistent for all labiaplasty techniques. From our review, no technique proved to be superior to the others. Observance of the considerations mentioned herein is essential for achieving successful outcomes.

Disclosures

The authors declared no potential conflicts of interest with respect to the research, authorship, and publication of this article.

Funding

The authors received no financial support for the research, authorship, and publication of this article.

REFERENCES

1. Heller DS, Kuye OO. Recurrent hypertrophy of the labia minora: a hormonally related lesion possibly related to fibroepithelial stromal polyps of the vulva. *J Lower Genit Tract Dis.* 2011;15:69-70.
2. Barrett MM, Carlson JA. A clinicopathologic study of labia minora hypertrophy: signs of localized lymphedema were universal. *J Lower Genit Tract Dis.* 2014;18:13-20.
3. Miklos JR, Moore RD. Simultaneous labia minora and majora reduction: a case report. *J Minim Invasive Gynecol.* 2011;18:378-380.
4. Di Saia JP. An unusual staged labial rejuvenation. *J Sex Med.* 2008;5:1263-1267. [discussion].
5. Chang P, Salisbury MA, Narsete T, Buckspan R, Derrick D, Ersek RA. Vaginal labiaplasty: defense of the simple "clip and snip" and a new classification system. *Aesthet Plast Surg.* 2013;37:887-891.
6. Miklos JR, Moore RD. Labiaplasty of the labia minora: patients' indications for pursuing surgery. *J Sex Med.* 2008;5:1492-1495.
7. Zwier S. "What motivates her": motivations for considering labial reduction surgery as recounted on women's online communities and surgeons' websites. *Sex Med.* 2014;2:16-23.
8. Hamori CA. Aesthetic surgery of the female genitalia: labiaplasty and beyond. *Plast Reconstr Surg.* 2014;134:661-673.
9. Hamori C. Aesthetic outcomes of labiaplasty. *Aesthet Surg J.* 2011;31:987; author reply 988.
10. Pauls RN. We are the correct physicians to treat women requesting labiaplasty. *Am J Obstet Gynecol.* 2014;211:218.e1.
11. Goodman MP. Female genital cosmetic and plastic surgery: a review. *J Sex Med.* 2011;8:1813-1825.
12. Veale D, Naismith I, Eshkevari E, et al. Psychosexual outcome after labiaplasty: a prospective case-comparison study. *Int Urogynecol J.* 2014;25:831-839.
13. Rogers RG. Most women who undergo labiaplasty have normal anatomy; we should not perform labiaplasty. *Am J Obstet Gynecol.* 2014;211:218.e1.
14. Creighton S. AGAINST: labiaplasty is an unnecessary cosmetic procedure. *BJOG.* 2014;121:768.
15. Crouch NS, Deans R, Michala L, Liao LM, Creighton SM. Clinical characteristics of well women seeking labial reduction surgery: a prospective study. *BJOG.* 2011;118:1507-1510.
16. Placik OJ, Arkins JP. Plastic surgery trends parallel *Playboy* magazine: the pudenda preoccupation. *Aesthet Surg J.* 2014;34:1083-1090.
17. Moran C, Lee C. What's normal? Influencing women's perceptions of normal genitalia: an experiment involving exposure to modified and nonmodified images. *BJOG.* 2014;121:761-766.
18. Veale D, Eshkevari E, Ellison N, et al. Psychological characteristics and motivation of women seeking labiaplasty. *Psychol Med.* 2014;44:555-566.
19. Koning M, Zeijlmans IA, Bouman TK, van der Lei B. Female attitudes regarding labia minora appearance and reduction with consideration of media influence. *Aesthet Surg J.* 2009;29:65-71.
20. Shaw D, Lefebvre G, Bouchard C, et al. Female genital cosmetic surgery. *JOGC.* 2013;35:1108-1114.
21. Hamori CA. Aesthetic labia minora and clitoral hood reduction using extended central wedge resection. *Plast Reconstr Surg.* 2009;124:337; author reply 337-338.
22. Liao LM, Taghinejadi N, Creighton SM. An analysis of the content and clinical implications of online advertisements for female genital cosmetic surgery. *BMJ Open.* 2012;2:e001908.
23. Capraro VJ. Congenital anomalies. *Clin Obstet Gynecol.* 1971;14:988-1012.
24. Felicio Yde A. Labial surgery. *Aesthet Surg J.* 2007;27:322-328.
25. Alter GJ. A new technique for aesthetic labia minora reduction. *Ann Plast Surg.* 1998;40:287-290.
26. Giraldo F, Gonzalez C, de Haro F. Central wedge nymphetomy with a 90-degree Z-plasty for aesthetic reduction of the labia minora. *Plast Reconstr Surg.* 2004;113:1820-1825; discussion 1826-1827.
27. Choi HY, Kim KT. A new method for aesthetic reduction of labia minora (the deepithelialized reduction of labioplasty). *Plast Reconstr Surg.* 2000;105:419-422; discussion 423-424.
28. Maas SM, Hage JJ. Functional and aesthetic labia minora reduction. *Plast Reconstr Surg.* 2000;105:1453-1456.
29. Pardo J, Sola V, Ricci P, Guilloff E. Laser labiaplasty of labia minora. *Int J Gynaecol Obstet.* 2006;93:38-43.
30. Ostrzenski A. Fenestration labioreduction of the labium minus: a new surgical intervention concept. *ISRN Obstet Gynecol.* 2014; doi: 10.1155/2014/671068.
31. Kato K, Kondo A, Gotoh M, Tanaka J, Saitoh M, Namiki Y. Hypertrophy of labia minora in myelodysplastic women. Labiaplasty to ease clean intermittent catheterization. *Urology.* 1988;31:294-299.
32. Lynch A, Marulaiah M, Samarakkody U. Reduction labiaplasty in adolescents. *J Pediatr Adolesc Gynecol.* 2008;21:147-149.
33. Wu JA, Braschi EJ, Gulminelli PL, Comiter CV. Labiaplasty for hypertrophic labia minora contributing to recurrent urinary tract infections. *Female Pelvic Medicine Reconstr Surg.* 2013;19:121-123.
34. Jothilakshmi PK, Salvi NR, Hayden BE, Bose-Haider B. Labial reduction in adolescent population—a case series study. *J Pediatr Adolesc Gynecol.* 2009;22:53-55.
35. Chavis WM, LaFerla JJ, Niccolini R. Plastic repair of elongated, hypertrophic labia minora. A case report. *J Reprod Med.* 1989;34:373-375.
36. Munhoz AM, Filassi JR, Ricci MD, et al. Aesthetic labia minora reduction with inferior wedge resection and superior pedicle flap reconstruction. *Plast Reconstr Surg.* 2006;118:1237-1247; discussion 1248-1250.
37. Rouzier R, Louis-Sylvestre C, Paniel BJ, Haddad B. Hypertrophy of labia minora: experience with 163 reductions. *Am J Obstet Gynecol.* 2000;182:35-40.
38. Iglesia CB, Yurteri-Kaplan L, Alinsod R. Female genital cosmetic surgery: a review of techniques and outcomes. *Int Urogynecol J.* 2013;24:1997-2009.

39. Foldes P, Droupy S, Cuzin B. Cosmetic surgery of the female genitalia. *Prog Urol*. 2013;23:601-611 [article in French].
40. Pourcelot AG, Fernandez H, Legendre G. Surgical reduction of labia minora: which approach? *Gynecol Obstet Fertilite*. 2013;41:218-221 [article in French].
41. Reddy J, Laufer MR. Hypertrophic labia minora. *J Pediatr Adolesc Gynecol*. 2010;23:3-6.
42. Motakef S, Rodriguez-Feliz J, Chung MT, Ingargiola MJ, Wong VW, Patel A. Vaginal labiaplasty: a systematic review, simplified classification system, and standardized practice guidelines. *Plast Reconstr Surg*. 2014;134:125-126.
43. Hodgkinson DJ, Hait G. Aesthetic vaginal labioplasty. *Plast Reconstr Surg*. 1984;74:414-416.
44. Hamori CA. Postoperative clitoral hood deformity after labiaplasty. *Aesthet Surg J*. 2013;33:1030-1036.
45. Alter GJ. Aesthetic labia minora and clitoral hood reduction using extended central wedge resection. *Plast Reconstr Surg*. 2008;122:1780-1789.
46. Hong ZJ, Wang J, Yuan SM, Wang Y, Hu XB, Jiang HQ. Central wedge resection and asymmetric Z-plasty for minor labia reduction. *Zhonghua Zheng Xing Wai Ke Za Zhi*. 2009;25:268-270 [article in Chinese].
47. Kelishadi SS, Elston JB, Rao AJ, Tutela JP, Mizuguchi NN. Posterior wedge resection: a more aesthetic labiaplasty. *Aesthet Surg J*. 2013;33:847-853.
48. Martincik J, Malinovsky L. Surgical treatment of the hypertrophy of the labia minora. *Cesk Gynekol*. 1971;36:216-217 [article in Czech].
49. Solanki NS, Tejero-Trujeque R, Stevens-King A, Malata CM. Aesthetic and functional reduction of the labia minora using the Maas and Hage technique. *J Plast Reconstr Aesthet Surg*. 2010;63:1181-1185.
50. Cao YJ, Li FY, Li SK, et al. A modified method of labia minora reduction: the de-epithelialised reduction of the central and posterior labia minora. *J Plast Reconstr Aesthet Surg*. 2012;65:1096-1102.
51. Ellsworth WA, Rizvi M, Lypka M, et al. Techniques for labia minora reduction: an algorithmic approach. *Aesthet Plast Surg*. 2010;34:105-110.
52. Mayer HF. A modified method of labia minora reduction. *J Plast Reconstr Aesthet Surg*. 2013;66:147-148.
53. Gress S. Composite reduction labiaplasty. *Aesthet Plast Surg*. 2013;37:674-683.
54. Gonzalez F, Dass D, Almeida B. Custom flask labiaplasty. *Ann Plast Surg*. 2013. [Epub ahead of print].
55. Miklos JR, Moore RD. Postoperative cosmetic expectations for patients considering labiaplasty surgery: our experience with 550 patients. *Surg Technol Int*. 2011;21:170-174.
56. Radman HM. Hypertrophy of the labia minora. *Obstet Gynecol*. 1976;48:78S-79S.
57. Honore LH, O'Hara KE. Benign enlargement of the labia minora: report of two cases. *Eur J Obstet Gynecol Reprod Biol*. 1978;8:61-64.
58. Bernal Bastidas S. Hypertrophy of the labia minora. Report of a case. *Ginecol Obstet (Mexico)*. 1981;48:55-58. [article in Spanish].
59. Gowen RM, Martin VL. Labia minora reduction in an iron-lung disabled woman. *Obstet Gynecol*. 1988;71:488-489.
60. Fliegner JR. Vulval varicosities and labial reduction. *Aust N Z J Obstet Gynaecol*. 1997;37:129-130.
61. Sanjuan Rodriguez S, Torres de Aguirre A, Enriquez Zarabozo E, Ayuso Velasco R, Santamaria Ossorio JL. Labia minora hypertrophy in the puberty. *Cir Pediatr*. 2009;22:109-111 [article in Spanish].
62. Sakamoto H, Ichikawa G, Shimizu Y, Kikuchi A, Yamamoto T. Extreme hypertrophy of the labia minora. *Acta Obstet Gynecol Scand*. 2004;83:1225-1226.
63. Krizko M, Krizko M, Janek L. Plastic adjustment in hypertrophy of labia minora. *Ceska Gynekol*. 2005;70:446-449 [article in Czech].
64. Kruk-Jeromin J, Zielinski T. Hypertrophy of labia minora—pathomorphology and surgical treatment. *Ginekol Pol*. 2010;81:298-302 [article in Polish].
65. Trichot C, Thubert T, Faivre E, Fernandez H, Deffieux X. Surgical reduction of hypertrophy of the labia minora. *Int J Gynaecol Obstet*. 2011;115:40-43.
66. Cayrac M, Rouzier R. Evaluation of labia minora reduction by longitudinal resection. *Gynecol Obstet Fertilite*. 2012;40:561-565 [article in French].
67. Triana L, Robledo AM. Refreshing labioplasty techniques for plastic surgeons. *Aesthet Plast Surg*. 2012;36:1078-1086.
68. Wagner IJ, Damitz LA, Carey E, Zolnoun D. Bilateral accessory breast tissue of the vulva: a case report introducing a novel labiaplasty technique. *Ann Plast Surg*. 2013;70:549-552.
69. Yurteri-Kaplan LA, Miranne JM, Iglesia CB. Vulvar anatomy and labia minoraplasty. *Int Urogynecol J*. 2014;25:841-843.